



**PATIENT**

**PRESENTING CLINICAL SIGNS**

Macie Purner

History: Abd u/s yesterday showed mild hepatic remodeling and swelling with slight hepatic vein dilation, potential passive congestion

**SPECIES**

Canine

**ULTRASONOGRAPHIC EXAMINATION OF THE HEART**

**BREED**

Shih Tzu

**SEX**

Spayed female

**AGE**

12 years

The echocardiogram in this patient demonstrated normal **left atrial** size based on 3 separate methods of LA evaluation. The cranial and caudal **mitral** valve leaflets presented normal linear structure, extension in systole, and union in diastole with normal kinesis. The **left ventricle** presented normal thicknesses with linear contour and was not dilated nor restricted. The **myocardium** presented normal echogenicity without subjective evidence of significant fibrotic or ischemic disease. **Contractility** of the ventricular walls was adequate and in normal range for this patient evidenced by the fractional shortening measurement and subjective evaluation of the different regions of the myocardium. The **left ventricular outflow** tract demonstrated normal laminar flow and subjective structural integrity. The **right atrium** and auricle revealed normal size, structure and content. No evidence of masses was noted. **Tricuspid** valvular assessment demonstrated adequate linear morphology and kinesis. The **right ventricle** was of normal size (1/3 diameter of LV), chordae structure, myocardial echogenicity and thickness. **Pulmonary outflow** tract assessment revealed normal valve structure, laminar flow, and diameter (approx.1:1 pa/ao ratio). No visible **pericardial** or free pleura fluid was noted. The cranial **mediastinum and pericardial and extra-cardiac regions** were free of masses in the visible window.

**WEIGHT**

13 lbs

**INTERPRETED BY**

Eric Lindquist, DMV  
DABVP, Cert. IVUSS

CANINE CARDIAC PARAMETERS	MR VMAX (m/s)	TR VMAX (m/s)	LA/AO (Boon method)	LA/AO (Heart Base; Swe)	FS (%)	EF (%)	EPSS (cm)
NORMAL PARAMETER	4.5-5.5	<2.7	1.3	<1.6	28-40	40-100	<0.6
PATIENT			1.3	1.3	35		0.37
CANINE CARDIAC PARAMETERS	HR (BPM)	AV VMAX (m/s)	PV MAX (m/s)	BODY WEIGHT	LA 2D short axis Base view (cm)	LVIDd Avg; 2D and m- mode short axis (cm)	LVIDs Avg; 2D and m-mode short axis (cm)
NORMAL PARAMETER	50-100	0.7-1.7	0.7-1.6	BELOW	BELOW	BELOW	BELOW
PATIENT	90	1.0		13 ;lbs	2.58	2.31	

**IMAGING  
PERFORMED BY**

Jenn

**HOSPITAL NAME**

Rockaway

**REFERRING VET**

Dr. Maniar

**ULTRASONOGRAPHIC FINDINGS**

**INVOICE**

Normal echocardiogram.

42163

**INTERPRETATION OF THE FINDINGS & FURTHER RECOMMENDATIONS**

**DATE**

There is no evidence of pathology.

1/17/23



**PATIENT**

Macie Purner

**SPECIES**

Canine

**BREED**

Shih Tzu

**SEX**

Spayed female

**AGE**

12 years

**WEIGHT**

13 lbs

**INTERPRETED BY**

Eric Lindquist, DMV  
DABVP, Cert. IVUSS

**IMAGING PERFORMED BY**

Jenn

**HOSPITAL NAME**

Rockaway

**REFERRING VET**

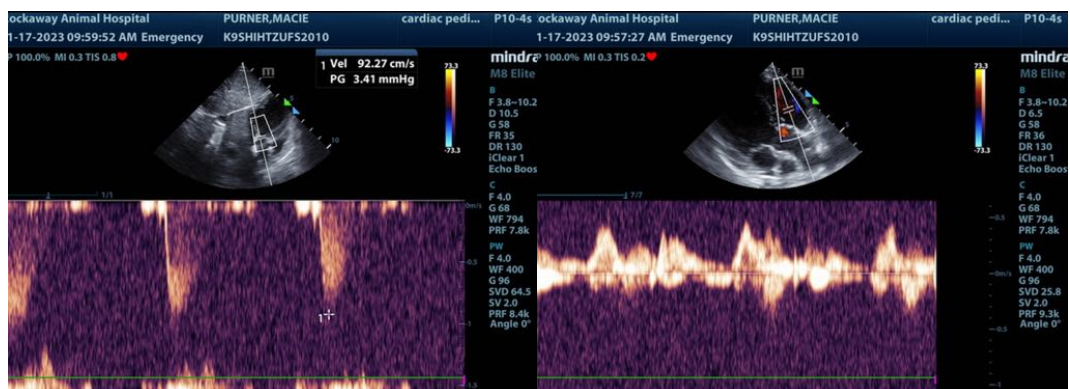
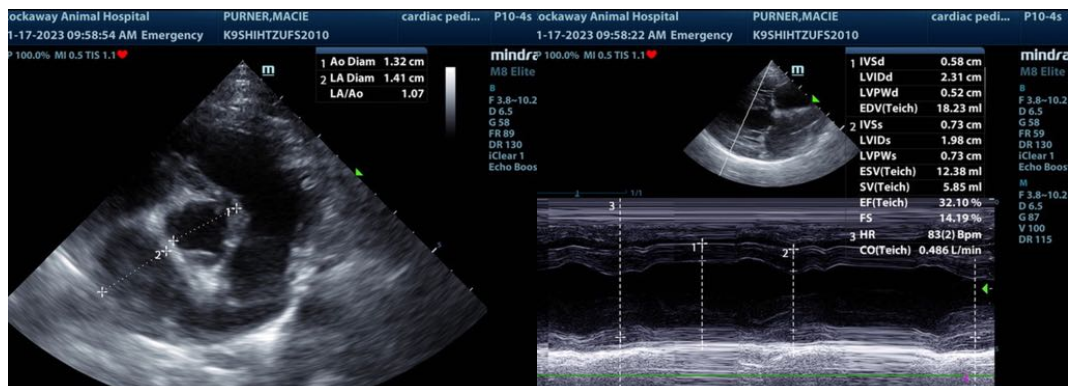
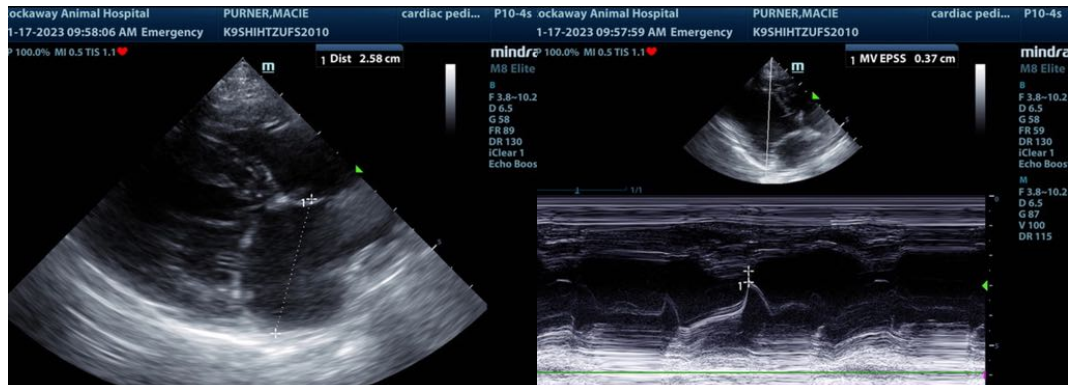
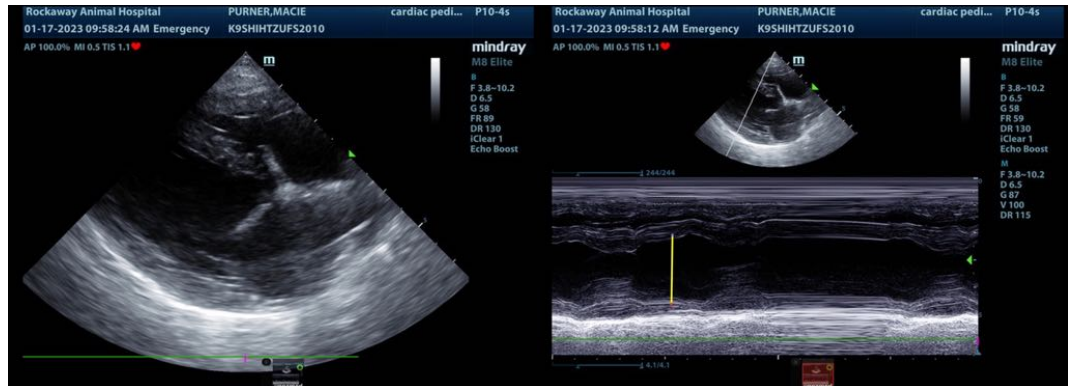
Dr. Maniar

**INVOICE**

42163

**DATE**

1/17/23





**PATIENT**

Macie Purner

The information and recommendations provided are based on the images presented by the referring veterinarian/sonographer. No evaluation can be communicated regarding pathology that was not visible in the image/video clips provided.

**SPECIES**

Canine

Thank you for this referral. If the clinical or image interpretation does not parallel your findings or if I can be of any further assistance please contact me.

**BREED**

Shih Tzu

**Eric Lindquist**, DMV, DABVP, Cert. IVUSS, CEO of SonoPath.com  
info@SonoPath.com

**SEX**

Spayed female

**AGE**

12 years

**WEIGHT**

13 lbs

**INTERPRETED BY**

Eric Lindquist, DMV  
DABVP, Cert. IVUSS

**IMAGING  
PERFORMED BY**

Jenn

**HOSPITAL NAME**

Rockaway

**REFERRING VET**

Dr. Maniar

**INVOICE**

42163

**DATE**

1/17/23