



**PATIENT**

Apache Brocklebank

**SPECIES**

Canine

**BREED**

Retriever

**SEX**

Neutered male

**AGE**

12 years

**WEIGHT**

32 kg

**INTERPRETED BY**

Eric Lindquist, DMV  
DABVP, Cert. IVUSS

**IMAGING PERFORMED BY**

Dr. Gira

**HOSPITAL NAME**

Resolution Veterinary  
Ultrasound

**REFERRING VET**

Dr. Gira

**INVOICE**

42201

**DATE**

1/17/23

**PRESENTING CLINICAL SIGNS**

History: Progressive weight loss, PUPD, elevation of liver enzymes  
Abnormal PE/Chem/CBC/UA Results: ALT 483 10 - 125 U/L ALP 272 23 - 212 U/L Cholesterol 8.85  
2.84 - 8.26 mmol/L Specific Gravity 1.015 (last UA done in De 2022)

**ULTRASONOGRAPHIC EXAMINATION OF THE ABDOMEN**

**Urinary System**

The **urinary bladder**, trigone, and pelvic urethra presented normal thicknesses and normal tone. The ureters were not visible which is normal. No uroliths or sediment were visualized and anechoic urine was present. No evidence of inflammatory or neoplastic changes was noted. Ureteral papillae were normal.

The residual prostate measured 1.2 cm.

The **kidneys** revealed largely normal size and structure, corticomedullary definition and ratio (cortex 1/3 of medulla) were essentially maintained with some age-related loss of curvilinear patterns regarding the capsule and C/M junction. The cortices presented largely uniform texture with some increased echogenicity expected for his age patient. Medullary structure differed distinctly from that of the cortex and no evidence of pelvic dilation was present. The right kidney measured 5.86 cm. The left kidney measured 7.08 cm.

**Adrenal Glands**

The **adrenal glands** appeared slightly enlarged and swollen. No evidence of focal capsular expansion or invasion into the phrenic veins was noted. No overt suspicion of neoplasia was noted. This is considered likely a hyperplastic change associated with stress or adrenal endocrinopathy (PDH). If isosthenuria is persistently present and the patient morphologically suggests Cushing's disease then ACTH testing would be indicated. The left adrenal gland measured 1.23 cm at the caudal pole and 1.01 cm at the cranial pole. The right adrenal gland measured 0.95 cm at the cranial pole and 0.62 cm at the caudal pole.

**Spleen**

The **spleen** presented discrete and diffuse hypoechoic micronodular parenchyma. The capsule was generally smooth without noticeable impingement from within the spleen or from pathology in the adjacent abdomen. The splenic vasculature demonstrated normal volume without signs of congestion or significant contraction. These changes are consistent with age related benign nodular hyperplasia. However, early hemangiosarcoma, lymphoma or mast cell neoplasia could not be entirely ruled out. Fine needle aspirate or biopsy following coagulation panel would be ideal especially if any weight loss is an issue. Otherwise, follow up ultrasound in 3-4 weeks to track these changes would be a more conservative approach.

**Liver**

The **liver** was uniformly swollen with minor, excessive gallbladder debris and over distension with dependent and suspended bile without evidence of overt mucocele formation. However, excessive



**PATIENT**

Apache Brocklebank

sludge was present. The liver presented coarse architecture with mildly increased portal markings and subtle, mixed echogenic changes. This is consistent with vacuolar hepatopathy and some level of remodeling and history of inflammatory component. There was no overt suspicion of neoplasia.

**SPECIES**

Canine

**Gastrointestinal**

Examination of the **gastrointestinal tract** revealed a stomach and intestine free of stasis, of normal wall thickness, acceptable curvilinear mural detail, and peristaltic activity. Small and large intestine demonstrated normal luminal chyme and stool consistency respectively. No obstructive or overt infiltrative disease was noted. No associated abnormal lymphatic activity was noted.

**BREED**

Retriever

**SEX**

Neutered male

**Pancreas**

The base and limbs of the **pancreas** were observed to be largely isoechoic to surrounding omental fat. Pancreatic duct and capsular contour were acceptably normal and parenchyma respected normal curvilinear patterns. No overt evidence of active inflammatory or neoplastic disease was noted.

**AGE**

12 years

**Free Abdomen**

A cystic structure was noted adjacent to the portal vein. This is likely a lymph node cyst and measured 3.0 cm.

**WEIGHT**

32 kg

**INTERPRETED BY**

Eric Lindquist, DMV  
DABVP, Cert. IVUSS

**ULTRASONOGRAPHIC FINDINGS**

Hyperplastic spleen.  
Bilateral adrenal enlargement, suspect PDH.  
Cystic hepatic lymph node.

**IMAGING PERFORMED BY**

Dr. Gira

**INTERPRETATION OF THE FINDINGS & FURTHER RECOMMENDATIONS**

**HOSPITAL NAME**

Resolution Veterinary  
Ultrasound

FNA of the spleen and liver is warranted given the ALT elevations and nodular changes. Emerging round cell neoplasia is possible, yet less likely.

**REFERRING VET**

Dr. Gira

**Efficient & Accurate Cushing's Work up-Lindquist**

**Notes regarding Cushing's Clinical Presentations:**

*Nearly all Cushing's dogs have SAP elevations and true PU/PD (USG < 1.025) and most are polyphagic.  
Cushing's dogs are > 6 years and usually > 9 years old, usually have poor skin coats, body scores > 3/5, and are usually sedentary animals.  
Its important to remember that Cushing's dogs usually look and play the part and other diseases cause false + stress related cortisol spikes. On rare occasion a Cushing's dog will not follow the rules but this is truly an exception.  
Potential Cushing's patient workups can be costly and frustrating if not definitive and, in my experience, the non-definitive patient usually has something else going on that may be contributing to*

**INVOICE**

42201

**DATE**

1/17/23



**PATIENT**

Apache Brocklebank

some of the clinical signs a Cushing's dog will have, especially SAP elevations or PU/PD. Based on this prelude of information I came up with the following algorithm in the spirit of diagnostic efficiency. The following suggested protocol is based on current available literature on Cushing's disease and extensive clinical-sonographic experience evaluation + Cushing's and False + LDDST & ACTH stim. cases in order to maximize the efficiency of a Cushing's workup in practice.

**SPECIES**

Canine

**BREED**

Retriever

**SEX**

Neutered male

**AGE**

12 years

**WEIGHT**

32 kg

**INTERPRETED BY**

Eric Lindquist, DMV  
DABVP, Cert. IVUSS

**IMAGING PERFORMED BY**

Dr. Gira

**HOSPITAL NAME**

Resolution Veterinary  
Ultrasound

**REFERRING VET**

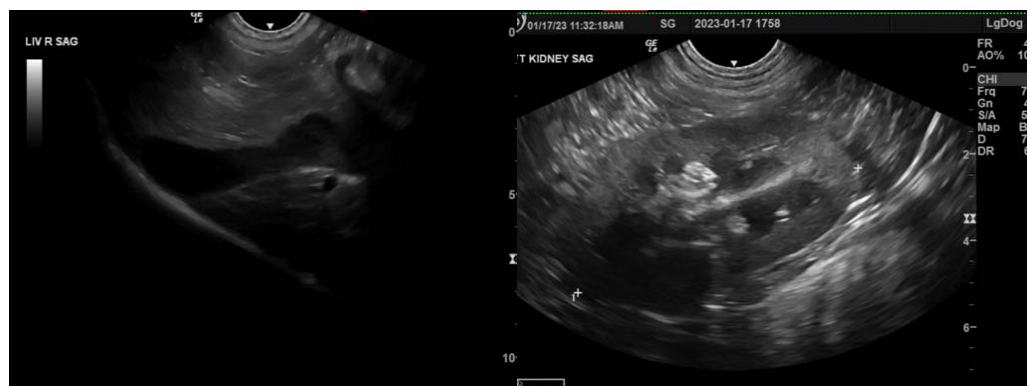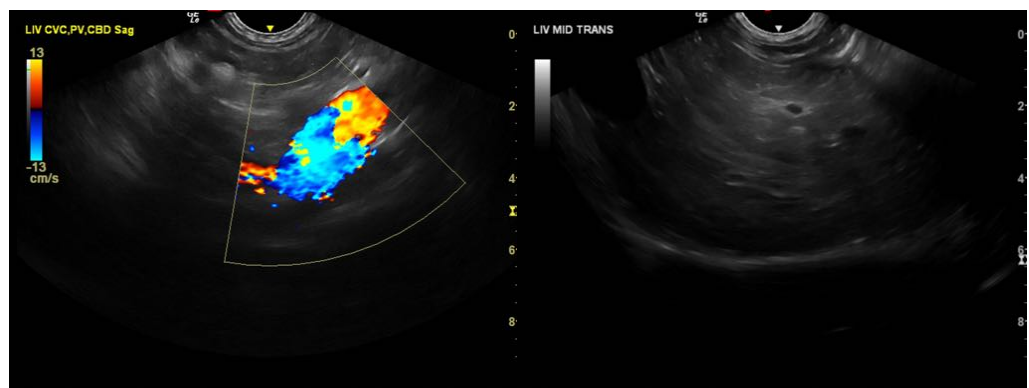
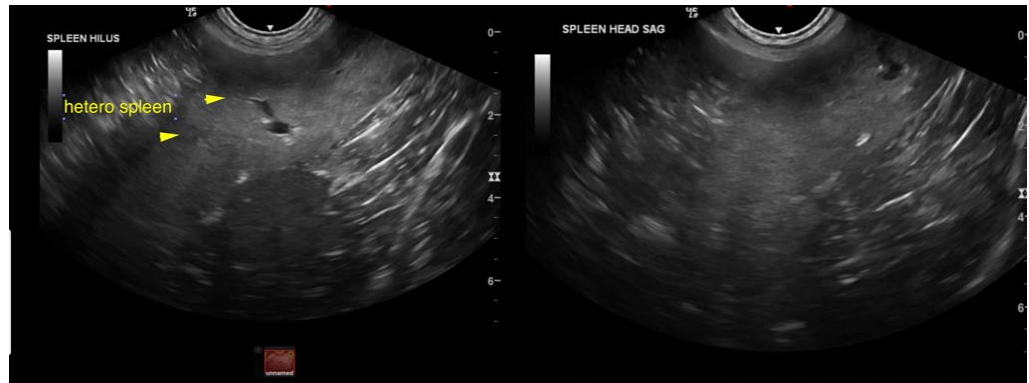
Dr. Gira

**INVOICE**

42201

**DATE**

1/17/23





**PATIENT**

Apache Brocklebank

**SPECIES**

Canine

**BREED**

Retriever

**SEX**

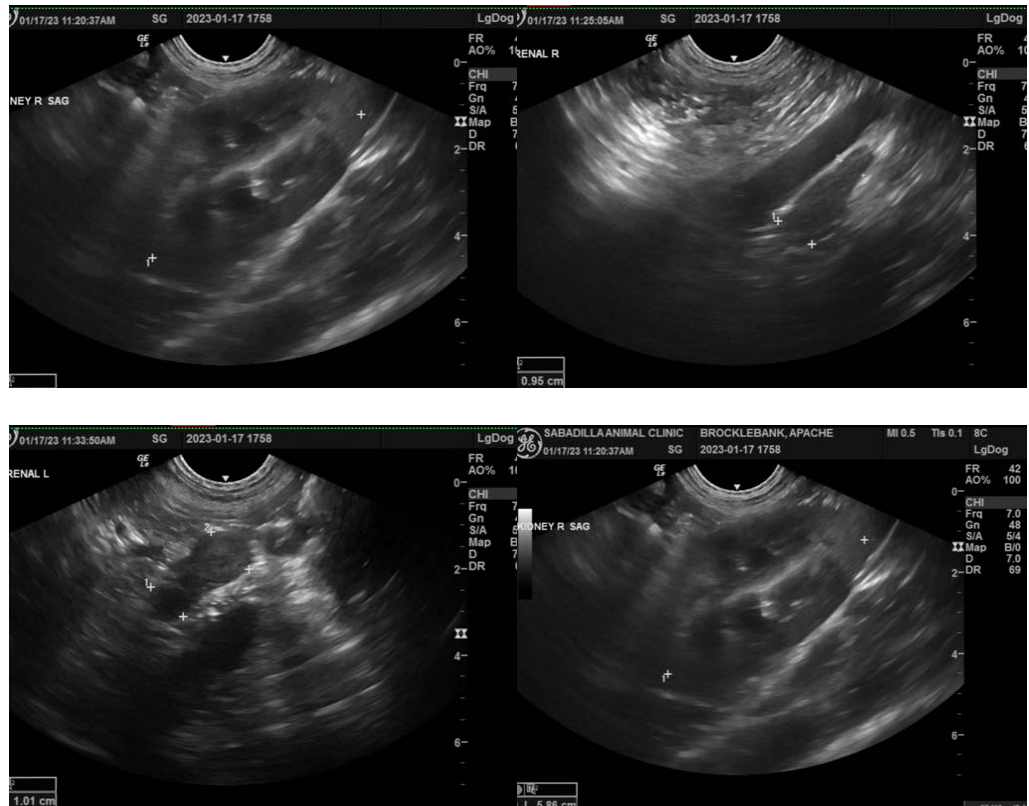
Neutered male

**AGE**

12 years

**WEIGHT**

32 kg



**INTERPRETED BY**

Eric Lindquist, DMV  
DABVP, Cert. IVUSS

**IMAGING PERFORMED BY**

Dr. Gira

**HOSPITAL NAME**

Resolution Veterinary  
Ultrasound

**REFERRING VET**

Dr. Gira

**INVOICE**

42201

**DATE**

1/17/23

The information and recommendations provided are based on the images presented by the referring veterinarian/sonographer. No evaluation can be communicated regarding pathology that was not visible in the image/video clips provided.

Thank you for this referral. If the clinical or image interpretation does not parallel your findings or if I can be of any further assistance please contact me.

**Eric Lindquist**, DMV, DABVP, Cert. IVUSS, CEO of SonoPath.com  
info@SonoPath.com