

PATIENT

Nugs Stonebridge

PRESENTING CLINICAL SIGNS

Persistently high ALKP (299); on phenobarbital

SPECIES

Canine

BREED

Pit Mix

SEX

Neutered male

AGE

10 years

WEIGHT

70 lbs

INTERPRETED BY

Eric Lindquist, DMV
DABVP, Cert. IVUSS

IMAGING PERFORMED BY

Diane McFadden, RVT

HOSPITAL NAME

Animal Mansion

INVOICE

95290

DATE

1/17/22

ULTRASONOGRAPHIC EXAMINATION OF THE ABDOMEN

Urinary System

The **urinary bladder** and visible pelvic urethra were unremarkable for the level of repletion presented. The urine, however, did present some mildly echogenic debris consistent with mucous, exfoliated cells from renal or bladder origin, and/or blood clots as these echogenic changes can all present similarly. This is often related to urinary tract infection but may represent simple evidence of exfoliated debris or sterile inflammation. Cystocentesis, urinalysis, +/- culture would be recommended to rule out and define any UTI.

The residual prostate was mildly heterogenous and measured 1.5 cm.

The **kidneys** revealed normal size and structure, corticomedullary definition and ratio for this age. The cortices presented largely uniform texture with normal echogenic relationship to liver and spleen. Medullary structure differed distinctly from the cortex and no evidence of pelvic dilation was present. The capsules were acceptably uniform without significant irregularities. The right kidney measured 6.5 cm. The left kidney measured 6.68 cm.

Adrenal Glands

Both **adrenal glands** were visualized and recognized as having normal shape, size, position and echogenicity for this breed. The phrenic vasculature, glandular echogenicity and detail were unremarkable. Capsule, cortex, and medullary definition were normal for this age patient. The left adrenal gland measured 3.09 x 0.79 cm at the caudal pole and 0.55 cm at the cranial pole. The right adrenal gland measured 3.16 x 0.71 cm at the caudal pole and 1.2 cm at the cranial pole.

Spleen

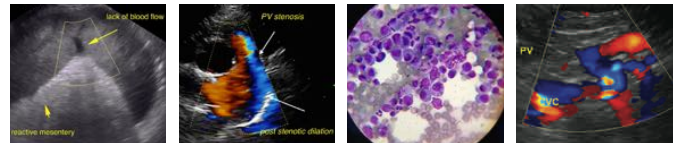
The **spleen** revealed multi-focal, hypoechoic nodular changes with mild areas of capsular expansion and disrupted architecture.

Liver

The **liver** images from right and left intercostal as well as subcostal views revealed subjectively normal liver size, contour, and structure. Some age-related parenchymal remodeling was noted but likely not clinically significant at this time. Vascular and biliary tracts were of normal volume and no evidence of congestion was noted. The gallbladder presented some dependent debris with essentially normal contour. The cystic and common bile ducts were normal. No overt evidence of active inflammatory, infiltrative or regenerative pathology was noted but should be paired with current or past LE elevations regarding any clinical significance to this presentation. The hepatic lymph nodes were unremarkable.

Gastrointestinal

Examination of the **gastrointestinal tract** revealed a stomach and intestine free of stasis, of normal wall thickness, acceptable curvilinear mural detail, and peristaltic activity. Minor retention of ingesta was



PATIENT
Nugs Stonebridge

noted in the stomach. Small and large intestine demonstrated normal luminal chyme and stool consistency respectively. No obstructive or overt infiltrative disease was noted. No associated abnormal lymphatic activity was noted.

SPECIES

Canine

Pancreas

The base and limbs of the **pancreas** were observed to be largely isoechoic to surrounding omental fat. Pancreatic duct and capsular contour were acceptably normal and parenchyma respected normal curvilinear patterns. No overt evidence of active inflammatory or neoplastic disease was noted.

BREED

Pit Mix

SEX

Neutered male

Heart

Rapid view of the heart revealed no evidence of pathology.

AGE

10 years

ULTRASONOGRAPHIC FINDINGS

Undefined nodular splenic changes, benign hepatopathy.

Prominent prostate, likely late neuter.

WEIGHT

70 lbs

INTERPRETATION OF THE FINDINGS & FURTHER RECOMMENDATIONS

FNA of the spleen is indicated to ensure that this is a hyperplastic state as opposed to emerging round cell neoplasia.

INTERPRETED BY

Eric Lindquist, DMV
DABVP, Cert. IVUSS

IMAGING PERFORMED BY

Diane McFadden, RVT

HOSPITAL NAME

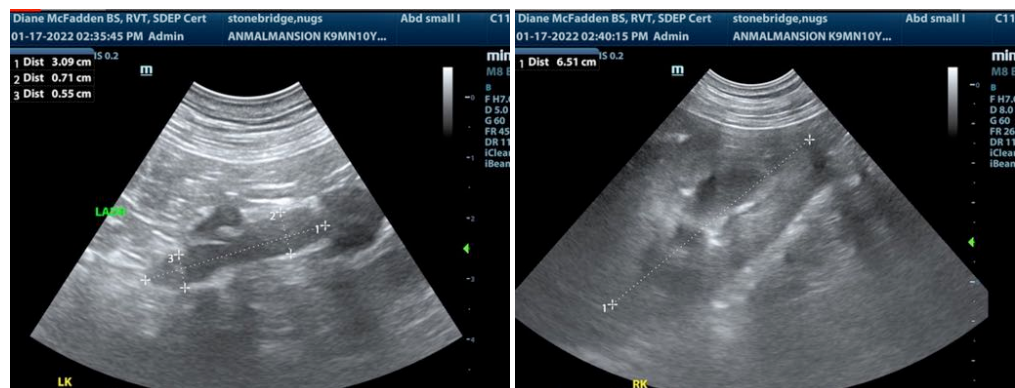
Animal Mansion

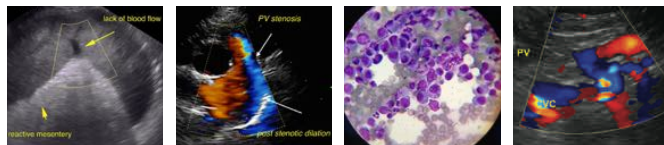
INVOICE

95290

DATE

1/17/22





PATIENT

Nugs Stonebridge

SPECIES

Canine

BREED

Pit Mix

SEX

Neutered male

AGE

10 years

WEIGHT

70 lbs

INTERPRETED BY

Eric Lindquist, DMV
DABVP, Cert. IVUS

IMAGING PERFORMED BY

Diane McFadden, RVT

HOSPITAL NAME

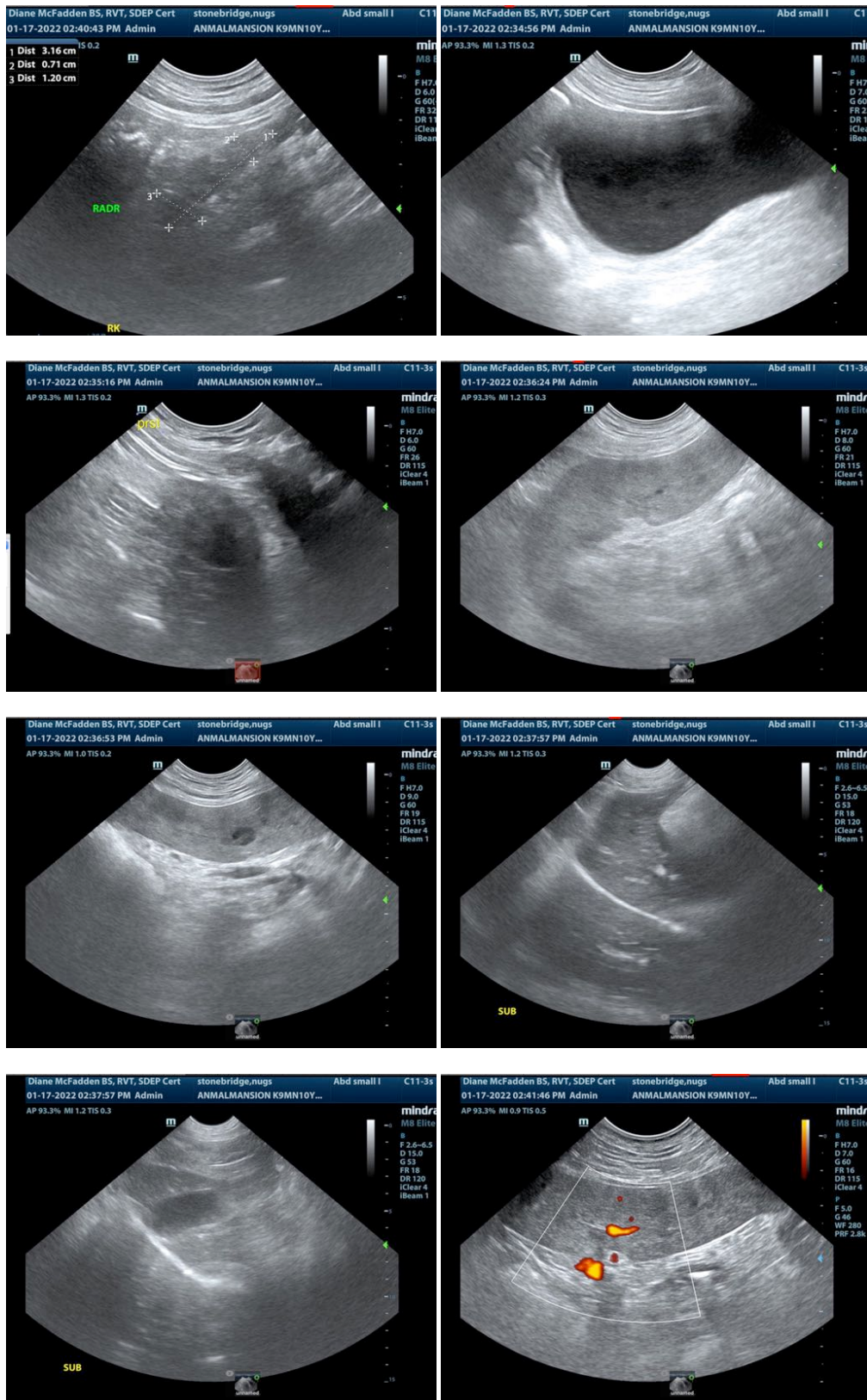
Animal Mansion

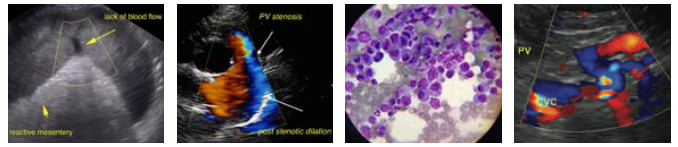
INVOICE

95290

DATE

1/17/22





PATIENT

Nugs Stonebridge

SPECIES

Canine

BREED

Pit Mix

SEX

Neutered male

AGE

10 years

WEIGHT

70 lbs

INTERPRETED BY

Eric Lindquist, DMV
DABVP, Cert. IVUSS

**IMAGING
PERFORMED BY**

Diane McFadden, RVT

HOSPITAL NAME

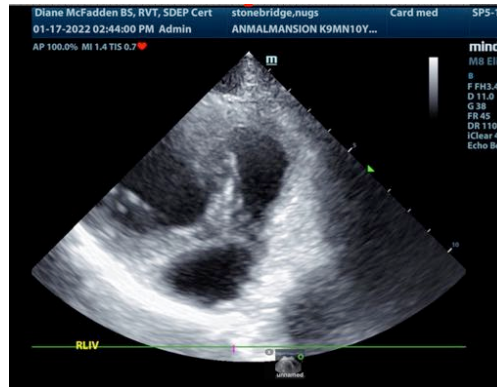
Animal Mansion

INVOICE

95290

DATE

1/17/22



The information and recommendations provided are based on the images presented by the referring veterinarian. No evaluation can be communicated regarding pathology that was not visible in the image/video clips provided.

Thank you for this referral. If the clinical or image interpretation does not parallel your findings or if I can be of any further assistance please contact me.

Eric Lindquist, DMV, DABVP, Cert. IVUSS, CEO of SonoPath.com
Info@SonoPath.com