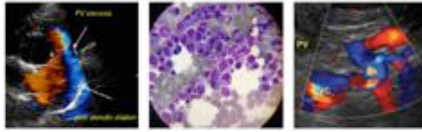


IMAGING PERFORMED BYSVS Mobile Imaging 262-366-5970
fredgromalak@gmail.com

Clinical Sonography & Teletology

EDUCATIONAL TELECONSULTATION SERVICES™

1-800-838-4268 info@sonopath.com SonoPath.com

PATIENT

Cutty Moore

SPECIES

Canine

BREED

Golden Retriever

SEX

Neutered Male

AGE

11 years

WEIGHT

90 Pounds

INTERPRETED BYEric Lindquist, DMV
DABVP, Cert. IVUSS**IMAGING PERFORMED BY**

Dr. Gromalak

HOSPITAL NAME

SVS Imaging

REFERRING VET

Dr. Texeria

INVOICE

95304

DATE

1/17/22

PRESENTING CLINICAL SIGNS

T4: 4.6 (1.0-4.0) Hyperthyroid? Ig firm mass freely mobile L ventral mid cervical region 3x3x3in Firm Mass L ventral neck, PU/PD 1/13/22 BW CBC: increase PH 484 (143-448)K/ul Chem: WNL TT4: 5.3 (1-4.0) increased from 4.6 10/14/21

Abnormal PE/Chem/CBC/UA Results: suspect arrhythmia present.

ECG

Multiple solitary and uniform, wide, bizarre complexes, sometimes in a trigeminy pattern. The coupling intervals range from 320-360 ms. There's no R on T-phenomenon visible. Apart from this sinus rhythm with tall P-waves, possibly indicating right atrial enlargement. Also, the ectopy likely originates from the right ventricular side.

Causes can be extracardiac or cardiac.

Would recommend full echocardiogram (e.g. rule out cardiac metastasis), electrolytes, Troponin I, chest radiographs (metastasis? cardiac enlargement? signs of congestion?) and an abdominal scan.

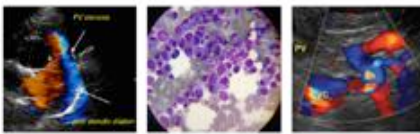
If a thyroid tumor is confirmed, removal is indicated.

If this arrhythmia on this short rhythm strip is representative for the whole arrhythmia, it does not appear to be life threatening. Still, I would strongly recommend a Holter-ECG to decide if therapy is necessary. If not possible/feasible, I would potentially start with Sotalolol at 1 mg/kg bid increasing to 2 mg/kg after a week, if well tolerated. If not tolerated, mexiletine would be an alternative.

Peter Modler DVM, Dipl.-Tzt. | SonoPath

ULTRASONOGRAPHIC EXAMINATION OF THE HEART

The echocardiogram in this patient demonstrated normal **left atrial** size based on 3 separate methods of LA evaluation. Trivial **mitral** valve insufficiency was noted in this patient. This is not clinically significant. Trivial mitral insufficiency was noted on color flow assessment. The **left ventricle** presented thicknesses with linear contour and was not dilated nor restricted. The **myocardium** presented normal echogenicity without subjective evidence of significant fibrotic or ischemic disease. **Contractility** of the ventricular walls was adequate and in normal range for this patient evidenced by the fractional shortening measurement and subjective evaluation of the different regions of the myocardium. The **left ventricular outflow** tract demonstrated normal laminar flow and subjective structural integrity. The **right atrium** and auricle revealed normal size, structure and content. No evidence of masses was noted. **Tricuspid** valvular assessment demonstrated adequate linear morphology and kinesis. The **right ventricle** was of normal size (1/3 diameter of LV), chordae structure, myocardial echogenicity and thickness. **Pulmonary outflow** tract assessment revealed normal valve structure, laminar flow, and diameter (approx. 1:1 pa/ao ratio). No visible **pericardial** or free pleura fluid was noted. The cranial **mediastinum and pericardial and extra-cardiac regions** were free of masses in the visible window. Persistent arrhythmia was noted, see EKG evaluation above.



PATIENT

Cutty Moore	CANINE	MR	TR	LA/AO	LA/AO	FS	EF	EPSS
	CARDIAC	VMAX	VMAX	(Boon method)	(Heart Base; Swe)	(%)	(%)	(cm)
	PARAMETER	(m/s)	(m/s)					
	NORMAL PARAMETER	4.5-5.5	<2.7	1.3	<1.6	28-40	40-100	<0.6
	BREED			1.08	1.4	Variable 45-60	90	NM
Golden Retriever	CANINE	HR	AV	PV	BODY WEIGHT	LA	LVIDd	LVIDs
	CARDIAC	(BPM)	VMAX	MAX		2D short axis Base view	Avg; 2D and m-mode short axis	Avg; 2D and m-mode short axis
	PARAMETER S		(m/s)	(m/s)		(cm)	(cm)	(cm)
Neutered Male	NORMAL PARAMETER	50-100	0.7-1.7	0.7-1.6				
	PATIENT	Variable 160	1.78 and variable based on arrhythmogenic activity	0.7	90 lbs	4.5 max	3.53	
	AGE							
11 years	WEIGHT							
90 Pounds								

INTERPRETED BY

Eric Lindquist, DMV
DABVP, Cert. IVUSS

ULTRASONOGRAPHIC FINDINGS

Normal echocardiogram with arrhythmogenic activity.

IMAGING PERFORMED BY

Dr. Gromalak

Trivial mitral valve insufficiency.

INTERPRETATION OF THE FINDINGS & FURTHER RECOMMENDATIONS

There was no structural abnormalities or dysfunction noted. However, the arrhythmia is significant and likely causes periodic cardiac dysfunction. Treatment of the arrhythmia is recommended. No primary cardiac medications are recommended; however, anti-arrhythmic therapy is recommended based on EKG findings as well as blood pressure measurements. Holter monitor would be ideal in this patient. Inciting causes such as systemic inflammation, infectious disease should be considered in this patient. Abdominal sonogram is warranted to assess for primary disease that may be inducing arrhythmia.

HOSPITAL NAME

SVS Imaging

REFERRING VET

Dr. Texeria

INVOICE

95304

DATE

1/17/22

IMAGING PERFORMED BY

SVS Mobile Imaging 262-366-5970
fredgromalak@gmail.com



Clinical Sonography & Telectyology

EDUCATIONAL TELECONSULTATION SERVICES™

1-800-838-4268 info@sonopath.com SonoPath.com

PATIENT

Cutty Moore

SPECIES

Canine

BREED

Golden Retriever

SEX

Neutered Male

AGE

11 years

WEIGHT

90 Pounds

INTERPRETED BY

Eric Lindquist, DMV
DABVP, Cert. IVUSS

IMAGING PERFORMED BY

Dr. Gromalak

HOSPITAL NAME

SVS Imaging

REFERRING VET


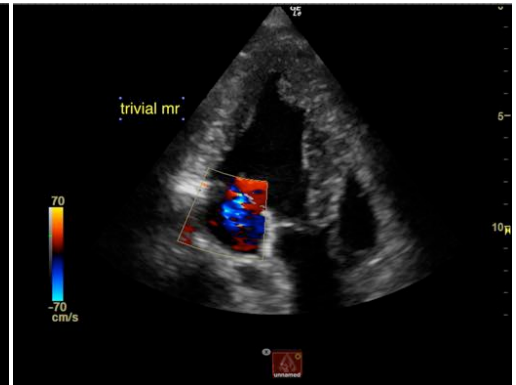
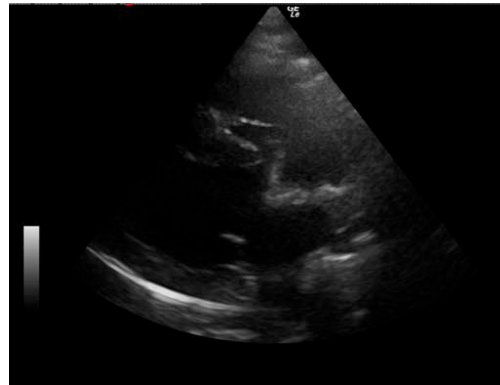
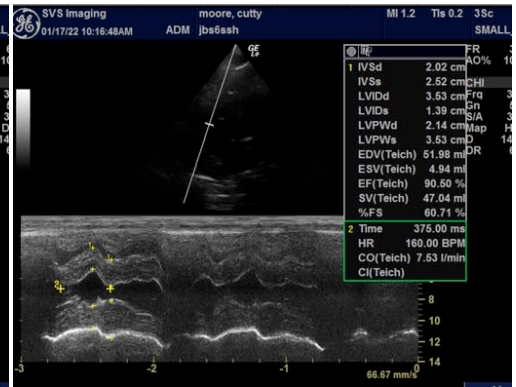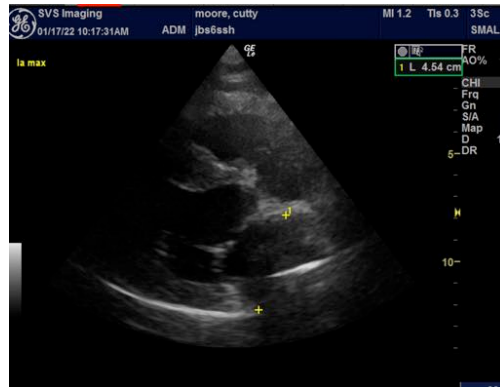
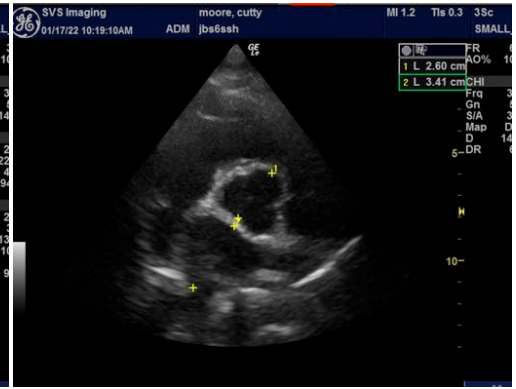
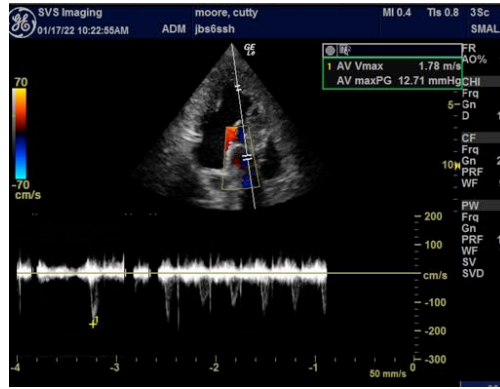
Dr. Texeria

INVOICE

95304

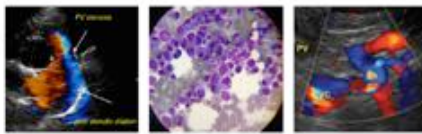
DATE

1/17/22



IMAGING PERFORMED BY

SVS Mobile Imaging 262-366-5970
fredgromalak@gmail.com



Clinical Sonography & Telectology

EDUCATIONAL TELECONSULTATION SERVICES™

1-800-838-4268 info@sonopath.com SonoPath.com

PATIENT

Cutty Moore

SPECIES

Canine

BREED

Golden Retriever

SEX

Neutered Male

AGE

11 years

WEIGHT

90 Pounds

INTERPRETED BY

Eric Lindquist, DMV
DABVP, Cert. IVUSS

IMAGING PERFORMED BY

Dr. Gromalak

HOSPITAL NAME

SVS Imaging

REFERRING VET


Dr. Texeria

INVOICE

95304

DATE

1/17/22



The information and recommendations provided are based on the images presented by the referring veterinarian. No evaluation can be communicated regarding pathology that was not visible in the image/video clips provided.

Thank you for this referral. If the clinical or image interpretation does not parallel your findings or if I can be of any further assistance please contact me.

Eric Lindquist, DMV, DABVP, Cert. IVUSS, CEO of SonoPath.com
Eric.Lindquist@SonoPath.com