



PATIENT

Biscuit Pencheva

SPECIES

Canine

BREED

Havanese

SEX

Male

AGE

11

WEIGHT

11.8

INTERPRETED BY

Eric Lindquist, DMV,
DABVP(CFM), Cert.
IVUSS

IMAGING PERFORMED BY

Dr. Brianna Gaines

HOSPITAL NAME

Healthy Pets
Veterinary Care- Boca
North

REFERRING VET

Dr. Brianna Gaines

INVOICE

13186

DATE

01/16/26

PRESENTING CLINICAL SIGNS

P presented in for an enlarged prostate and O is concerned about kidneys. Bloodwork is WNL

ULTRASONOGRAPHIC EXAMINATION OF THE ABDOMEN

Urinary System

The **urinary bladder** revealed a minimal amount of urine present with muscularis, hypertrophy and minor micropolypoid changes in the bladder wall at mild repletion measuring 0.70 cm.

The **prostate** was moderately enlarged with lobar swelling appeared to impinge upon the urethra and mildly deviate the descending colon. The prostatic tissue was hyperechoic containing focal areas of decreased echogenicity. These changes are suggestive of either chronic inflammatory episodes, benign cystic pathology or both. Underlying neoplasia cannot be completely ruled-out but is lower on the differential list. This presentation is most consistent with benign prostatic hyperplasia with possible active prostatitis. Neutering or off-label Finasteride (Propecia) (0.1-0.5 mg/kg Sid) treatment is indicated +/- FNA or prostatic wash cytology and culture. The prostate measured 2.4 cm.

The **kidneys** revealed normal size and structure, corticomedullary definition and ratio for this age. The cortices presented largely uniform texture with normal echogenic relationship to liver and spleen. Medullary structure differed distinctly from the cortex and no evidence of pelvic dilation was present. The capsules were acceptably uniform without significant irregularities. The left kidney measured 3.7 cm in length. The right kidney measured 3.7 cm in length.

Adrenal Glands

Both **adrenal glands** were visualized and recognized as having normal shape, size, position and echogenicity for this breed. The phrenic vasculature, glandular echogenicity and detail were unremarkable. Capsule, cortex, and medullary definition were normal for this age patient. The left adrenal gland measured 0.47 cm width. The right adrenal gland measured 0.50 cm width.

Spleen

The **spleen** presented a smooth homogeneous parenchyma hyperechoic to liver and renal cortical parenchyma. The capsule was smooth without noticeable expansion or deviation from within the spleen or adjacent pathology. The splenic vasculature demonstrated normal volume without signs of congestion or thrombosis. No sonographic evidence of acute or chronic inflammatory, neoplastic, or infarctual changes were noted.

Liver

The **liver** images submitted revealed subjectively normal liver size, contour, and structure. Parenchymal echogenicity was naturally coarse and hypoechoic to the spleen. Vascular and biliary tracts were of normal volume with no evidence of congestion. The gallbladder presented acceptably thin walls with primarily anechoic content. The cystic and common bile ducts were normal. No pathological hepatic lymphadenopathy was evident. No overt structural evidence of inflammatory, infiltrative or regenerative pathology was evident.

Gastrointestinal

Examination of the **gastrointestinal tract** revealed a stomach and intestine free of stasis, of normal wall thickness, acceptable curvilinear mural detail, and peristaltic activity. Small and large intestine



PATIENT

Biscuit Pencheva

SPECIES

Canine

BREED

Havanese

SEX

Male

AGE

11

WEIGHT

11.8

INTERPRETED BY

Eric Lindquist, DMV,
DABVP(CFM), Cert.
IVUSS

IMAGING PERFORMED BY

Dr. Brianna Gaines

HOSPITAL NAME

Healthy Pets
Veterinary Care- Boca
North

REFERRING VET

Dr. Brianna Gaines

INVOICE

13186

DATE

01/16/26

demonstrated normal luminal chyme and stool consistency respectively. No obstructive or overt infiltrative disease was noted. No associated abnormal lymphatic activity was noted.

Pancreas

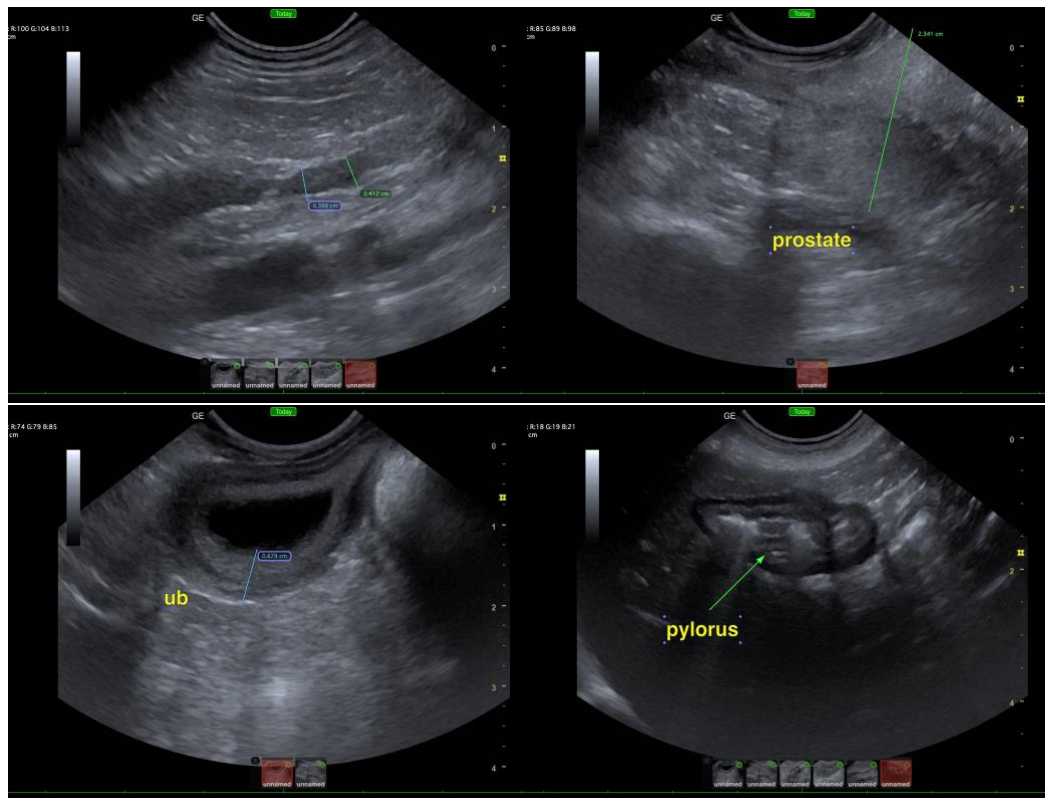
The base and limbs of the **pancreas** were observed to be largely isoechoic to surrounding omental fat. Pancreatic duct and capsular contour were acceptably normal and parenchyma respected normal curvilinear patterns. No overt evidence of active inflammatory or neoplastic disease was noted.

ULTRASONOGRAPHIC FINDINGS

- Minor bladder thickening without calculi.
- BPH prostate- cannot rule out low-grade prostatitis.

INTERPRETATION OF THE FINDINGS & FURTHER RECOMMENDATIONS

Urinary work up is warranted if not already performed. No evidence of gross pathology.





PATIENT

Biscuit Pencheva

SPECIES

Canine

BREED

Havanese

SEX

Male

AGE

11

WEIGHT

11.8

INTERPRETED BY

Eric Lindquist, DMV,
DABVP(CFM), Cert.
IVUSS

IMAGING PERFORMED BY

Dr. Brianna Gaines

HOSPITAL NAME

Healthy Pets
Veterinary Care- Boca
North

REFERRING VET

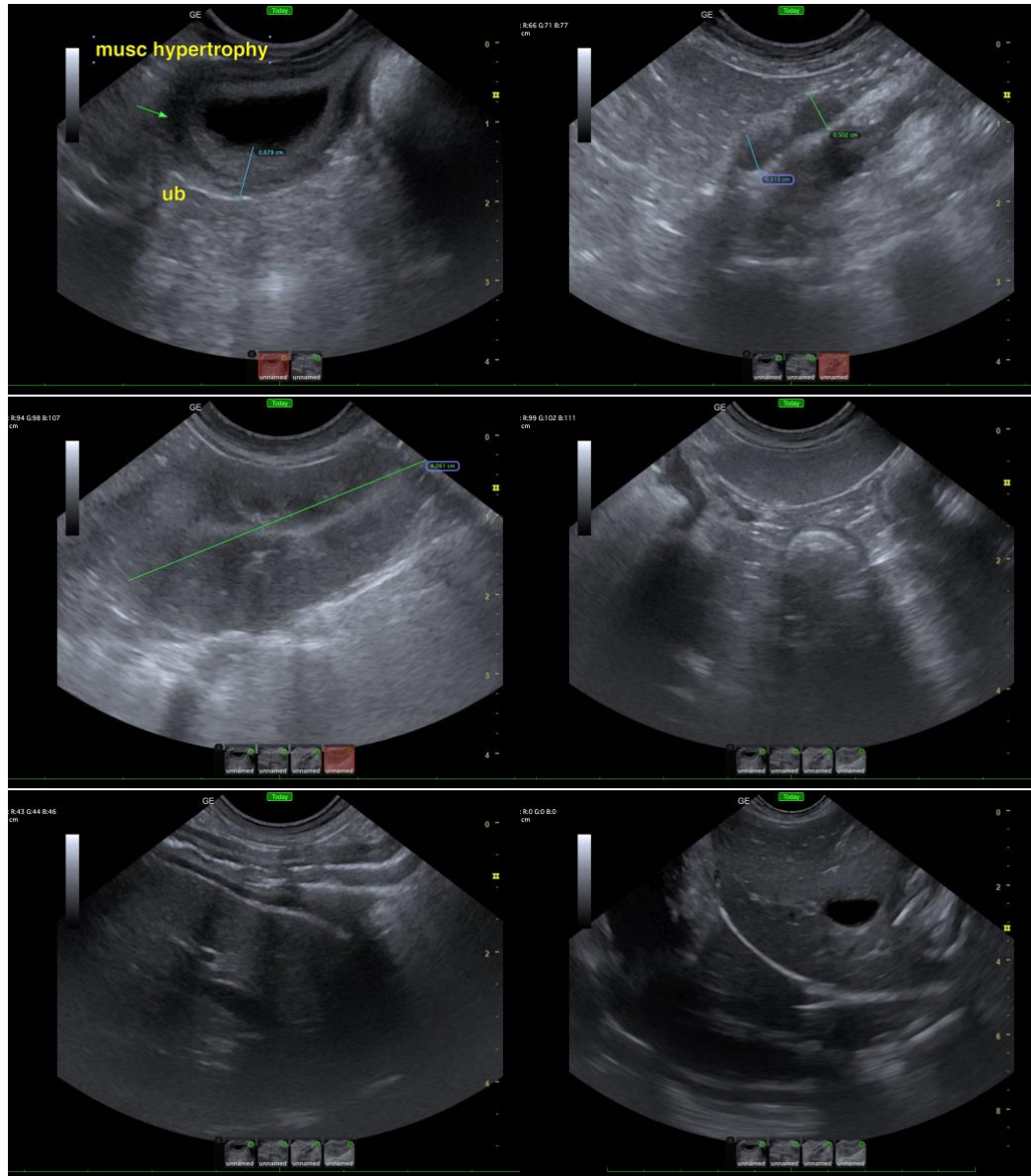
Dr. Brianna Gaines

INVOICE

13186

DATE

01/16/26



The information and recommendations provided are based on the images presented by the referring veterinarian/sonographer. No evaluation can be communicated regarding pathology that was not visible in the image/video clips provided.

Thank you for this referral. If the clinical or image interpretation does not parallel your findings or if I can be of any further assistance, please contact me.

Eric Lindquist, DMV, DABVP(CFM), Cert. IVUSS,

CEO, Owner, Founder -- SonoPath.com

info@SonoPath.com



PATIENT

Biscuit Pencheva

SPECIES

Canine

BREED

Havanese

SEX

Male

AGE

11

WEIGHT

11.8

INTERPRETED BY

Eric Lindquist, DMV,
DABVP(CFM), Cert.
IVUSS

IMAGING PERFORMED BY

Dr. Brianna Gaines

HOSPITAL NAME

Healthy Pets
Veterinary Care- Boca
North

REFERRING VET

Dr. Brianna Gaines

INVOICE

13186

DATE

01/16/26