



PATIENT

Agnes Cifelli

SPECIES

Canine

BREED

Chorkie

SEX

Spayed Female

AGE

9 Years 4 Months

WEIGHT

9.5 pounds

INTERPRETED BY

Eric Lindquist, DMV,
DABVP(CFM), Cert.
IVUSS

IMAGING PERFORMED BY

Rebecca Hamilton

HOSPITAL NAME

Animal Care Center
North Jersey

REFERRING VET

Dr. Adalaft

INVOICE

13219

DATE

01/16/26

PRESENTING CLINICAL SIGNS

Pet is starting to cough more at home. 2-3/6 heart murmur heard when last seen in Sept 2025.

Abnormal PE/Chem/CBC/UA Results: SC: Bun/Creat ratio 36, K 5.6, CBC: PC 443

ULTRASONOGRAPHIC EXAMINATION OF THE HEART

CANINE CARDIAC PARAMETERS	MR VMAX (m/s)	TR VMAX (m/s)	LA/AO (M-Mode)	LA/AO (Heart Base; Swe)	FS (%)	EF (%)	EPSS (cm)
NORMAL PARAMETER	4.5-5.5	<2.7	1.3	Up to 1.6	28-40	40-100	<0.6
PATIENT	6.0	--	1.3	1.4	46	80	0.3
CANINE CARDIAC PARAMETERS	HR (BPM)	AV VMAX (m/s)	PV MAX (m/s)	BODY WEIGHT (lbs)	LAD LA MAX 4 Chamber	LVIDd Avg; 2D and m-mode short axis (cm)	LVIDs Avg; 2D and m-mode short axis (cm)
NORMAL PARAMETER	50-100	0.7-1.7	0.7-1.6				
PATIENT	126	1.3	1.05	9.5	2.1	2.18	--

Cardiac Presentation

The echocardiogram in this patient demonstrated normal **left atrial** size based on 3 different LA measurement methods. Chamber volumes and echogenicity were normal. The cranial and caudal **mitral** valve leaflets presented vegetative thickening consistent with endocardiosis. Doppler indicated measurable insufficiency. The **left ventricle** presented normal thicknesses with linear contour and was not dilated nor restricted. The **myocardium** presented normal echogenicity without subjective evidence of significant fibrotic or ischemic disease. **Contractility** of the ventricular walls was adequate and in normal range for this patient evidenced by the fractional shortening measurement and subjective evaluation of the different regions of the myocardium. The **left ventricular outflow** tract demonstrated normal laminar flow and subjective structural integrity. The **right atrium** and auricle revealed normal size, structure and content. No evidence of masses was noted or chamber overload. **Tricuspid** valvular assessment demonstrated adequate linear morphology. The **right ventricle** was of normal size (1/3 diameter of LV), chordae structure, myocardial echogenicity and thickness. **Pulmonic** tract assessment revealed normal valve structure, laminar flow, and diameter (approx.1:1 pa/ao ratio). No visible **pericardial** or free pleura fluid was noted. No echographically detectable evidence of infiltrative disease was visible. The cranial **mediastinum and pericardial regions** were free of masses in the visible window. A periodic arrhythmia was noted in this patient and may be a simple pronounced sinus arrhythmia, however, baseline EKG is recommended.

ULTRASONOGRAPHIC FINDINGS

- Stage B1 valvular disease.



PATIENT

Agnes Cifelli

SPECIES

Canine

BREED

Chorkie

SEX

Spayed Female

AGE

9 Years 4 Months

WEIGHT

9.5 pounds

INTERPRETED BY

Eric Lindquist, DMV,
DABVP(CFM), Cert.
IVUSS

IMAGING PERFORMED BY

Rebecca Hamilton

HOSPITAL NAME

Animal Care Center
North Jersey

REFERRING VET

Dr. Adalaft

INVOICE

13219

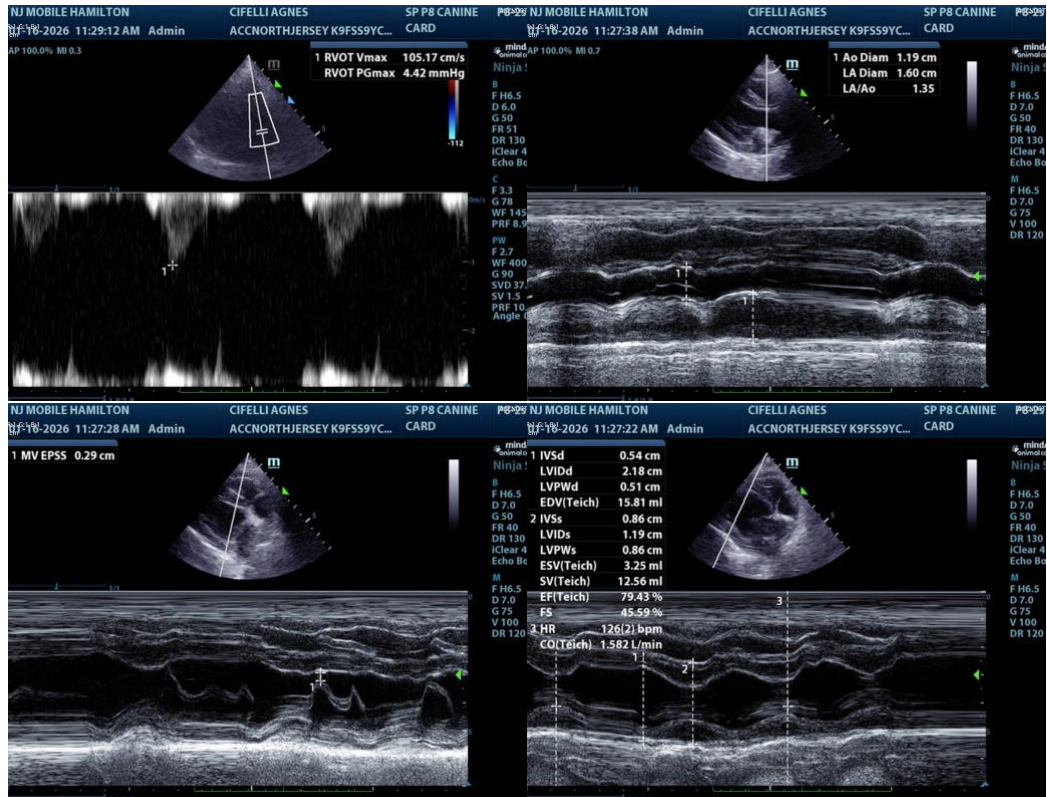
DATE

01/16/26

INTERPRETATION OF THE FINDINGS & FURTHER RECOMMENDATIONS

The cough is noncardiogenic at this time. No therapy is recommended at this time.

The heart has minor volume overload and is working to compensate for the valvular insufficiency. Target respiratory rate is < 20 resp/minute after therapy. After initiating or adjusting therapy, I recommend recheck on the clinical exam, BUN, Creatinine, USG, Chest radiographs & Blood pressure in 5-7 days. Recheck echo in 6 months, earlier if clinical decompensation is occurring. Minor anesthetic risk for a brief procedure at this time. Repeat preanesthetic echo is ideal if anesthesia is eventually necessary. A suggested anesthetic combination would involve Torbutrol premed, propofol induction, Isoflurane maintenance or equivalent protocol.





PATIENT

Agnes Cifelli

SPECIES

Canine

BREED

Chorkie

SEX

Spayed Female

AGE

9 Years 4 Months

WEIGHT

9.5 pounds

INTERPRETED BY

Eric Lindquist, DMV,
 DABVP(CFM), Cert. IVUSS

IMAGING PERFORMED BY

Rebecca Hamilton

HOSPITAL NAME

Animal Care Center
 North Jersey

REFERRING VET

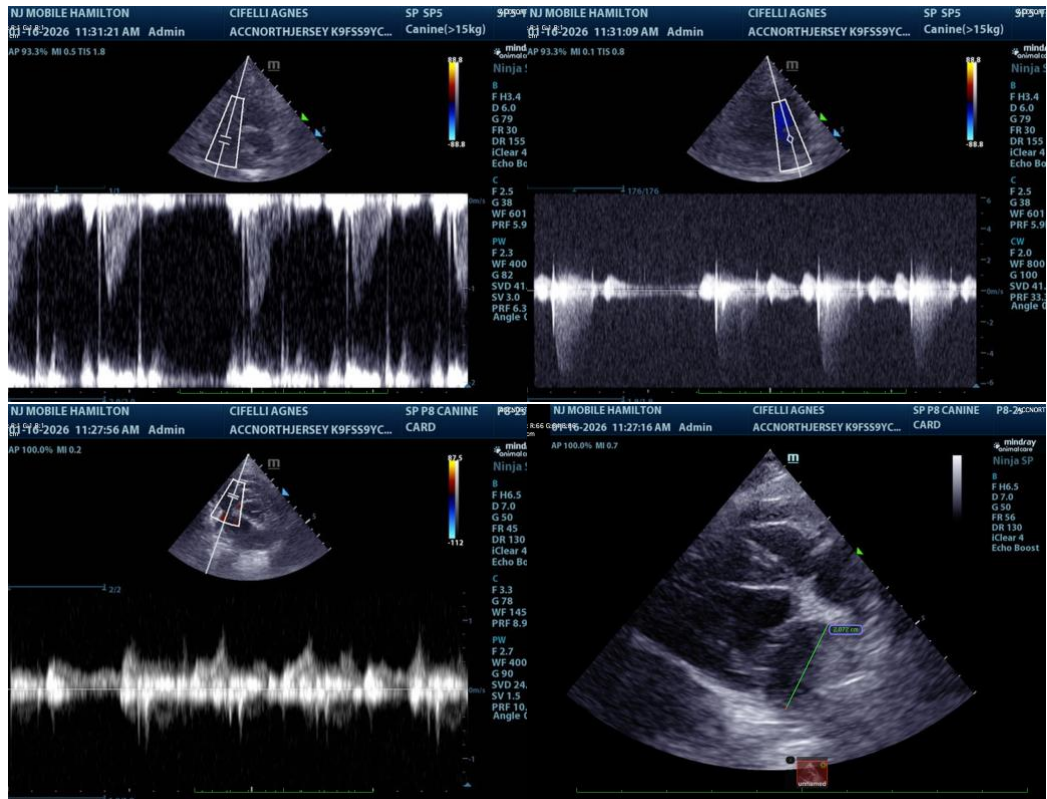
Dr. Adalaft

INVOICE

13219

DATE

01/16/26



The information and recommendations provided are based on the images presented by the referring veterinarian/sonographer. No evaluation can be communicated regarding pathology that was not visible in the image/video clips provided.

Thank you for this referral. If the clinical or image interpretation does not parallel your findings or if I can be of any further assistance, please contact me.

Eric Lindquist, DMV, DABVP(CFM), Cert. IVUSS,

CEO, Owner, Founder -- SonoPath.com

info@SonoPath.com