



**PATIENT**

Tigi Brearly

**SPECIES**

Canine

**BREED**

Chihuahua Longhair

**SEX**

Spayed female

**AGE**

12 years

**WEIGHT**

3.43 kg

**INTERPRETED BY**

Eric Lindquist, DMV  
DABVP, Cert. IVUSS

**IMAGING PERFORMED BY**

Dr. McFarlen

**HOSPITAL NAME**

Van Isle VH

**REFERRING VET**

Dr. McFarlen

**PRESENTING CLINICAL SIGNS**

History: Dental and Health Check up. Needs dental surgery.

Abnormal PE/Chem/CBC/UA Results: Grade 3-4 systolic murmur on exam. No symptoms that owner has noted. Pre-dental procedure echo.

**ULTRASONOGRAPHIC EXAMINATION OF THE HEART**

The echocardiogram in this patient demonstrated normal **left atrial** size based on 3 separate methods of LA evaluation. The cranial and caudal **mitral** valve leaflets presented normal linear structure, extension in systole, and union in diastole with normal kinesis. The **left ventricle** presented normal thicknesses with linear contour and was not dilated nor restricted. The **myocardium** presented normal echogenicity without subjective evidence of significant fibrotic or ischemic disease. **Contractility** of the ventricular walls was adequate and in normal range for this patient evidenced by the fractional shortening measurement and subjective evaluation of the different regions of the myocardium. The **left ventricular outflow** tract demonstrated normal laminar flow and subjective structural integrity. The **right atrium** and auricle revealed normal size, structure and content. No evidence of masses was noted. **Tricuspid** insufficiency was noted. The **right ventricle** was of normal size (1/3 diameter of LV), chordae structure, myocardial echogenicity and thickness. **Pulmonary outflow** tract assessment revealed normal valve structure, laminar flow, and diameter (approx. 1:1 pa/ao ratio). No visible **pericardial** or free pleura fluid was noted. The cranial **mediastinum and pericardial and extra-cardiac regions** were free of masses in the visible window.

CANINE CARDIAC PARAMETERS	MR VMAX (m/s)	TR VMAX (m/s)	LA/AO (Boon method)	LA/AO (Heart Base; Swe)	FS (%)	EF (%)	EPSS (cm)
NORMAL PARAMETER	4.5-5.5	<2.7	1.3	<1.6	28-40	40-100	<0.6
PATIENT	5.15		1.4	1.3	42	76	0.1
CANINE CARDIAC PARAMETERS	HR (BPM)	AV VMAX (m/s)	PV MAX (m/s)	BODY WEIGHT	LA 2D short axis Base view (cm)	LVIDd Avg; 2D and m- mode short axis (cm)	LVIDs Avg; 2D and m-mode short axis (cm)
NORMAL PARAMETER	50-100	0.7-1.7	0.7-1.6	BELOW	BELOW	BELOW	BELOW
PATIENT		2.01	0.75	3.43 kg	2.67	1.83	

**INVOICE**

42153

**DATE**

1/16/23

**ULTRASONOGRAPHIC FINDINGS**

Stage B1 valvular disease, compensated at this time.



**PATIENT**

Tigi Brearly

**SPECIES**

Canine

**BREED**

Chihuahua Longhair

**SEX**

Spayed female

**AGE**

12 years

**WEIGHT**

3.43 kg

**INTERPRETED BY**

Eric Lindquist, DMV  
DABVP, Cert. IVUSS

**IMAGING PERFORMED BY**

Dr. McFarlen

**HOSPITAL NAME**

Van Isle VH

**REFERRING VET**

Dr. McFarlen

**INVOICE**

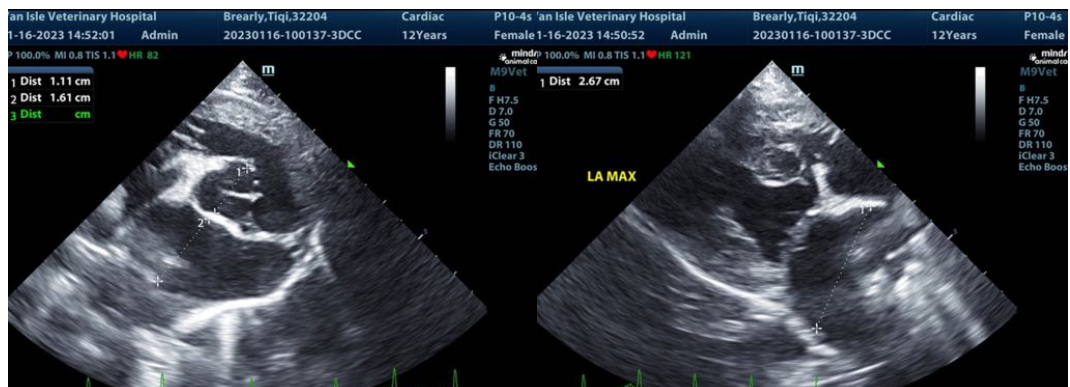
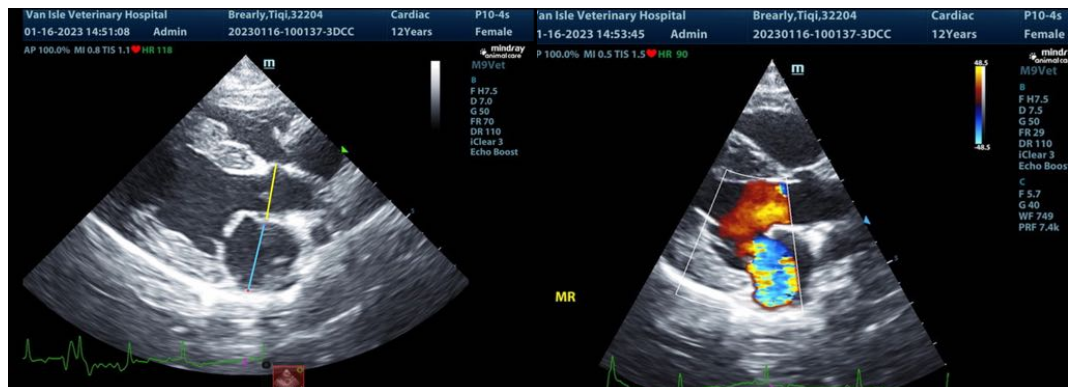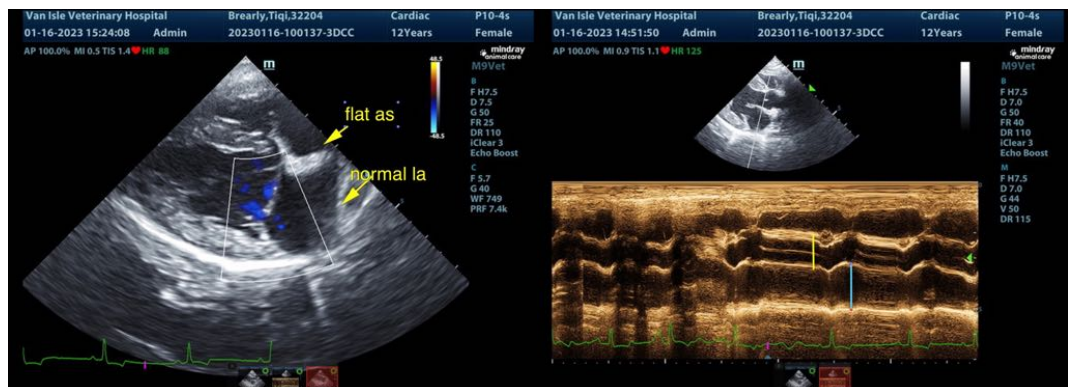
42153

**DATE**

1/16/23

**INTERPRETATION OF THE FINDINGS & FURTHER RECOMMENDATIONS**

The heart is stable without clinical disease. No overt contraindication for anesthesia of brief to moderate duration. I suggest Torbutrol premed, Propofol induction, Isoflo maintenance or similar protocol if anesthesia is desired. Blood pressure recommended if not already performed and target white coat negative systolic pressure of < 160 mmHg. If higher than this ACE-inhibitor is suggested to reach this level. Recheck echocardiogram is recommended in 6 months, earlier if murmur grade increases or clinical signs initiate.





**PATIENT**

Tigi Brearly

**SPECIES**

Canine

**BREED**

Chihuahua Longhair

**SEX**

Spayed female

**AGE**

12 years

**WEIGHT**

3.43 kg

**INTERPRETED BY**

Eric Lindquist, DMV  
DABVP, Cert. IVUSS

**IMAGING PERFORMED BY**

Dr. McFarlen

**HOSPITAL NAME**

Van Isle VH

**REFERRING VET**

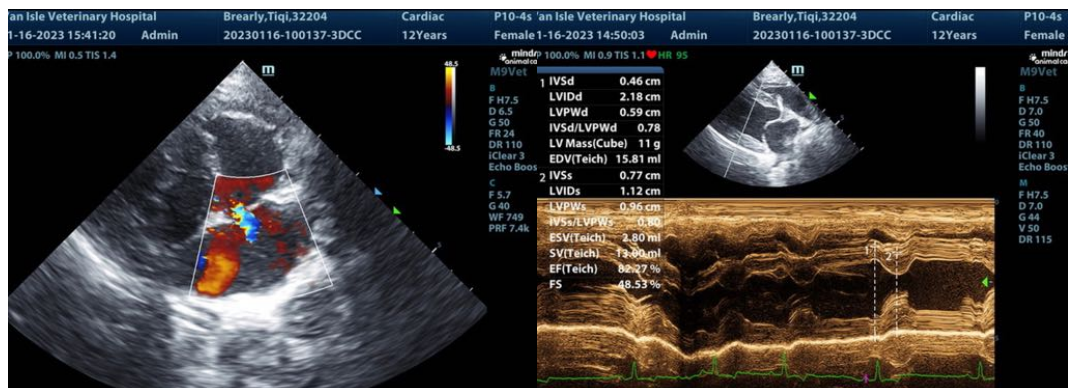
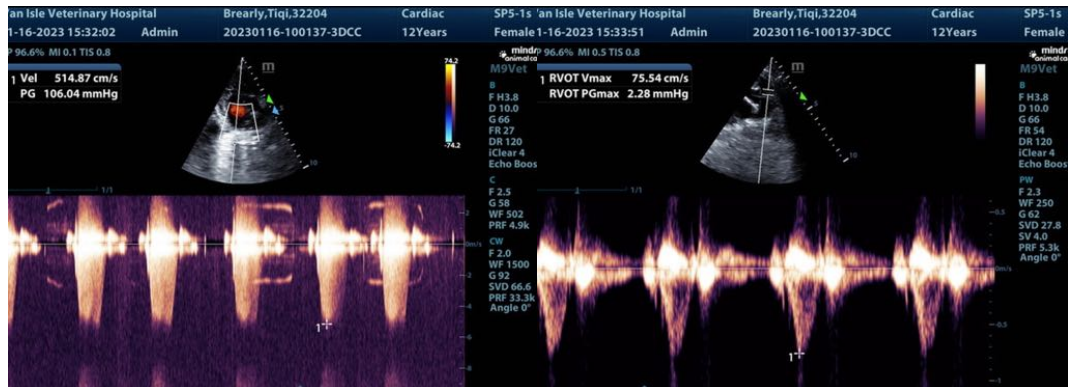
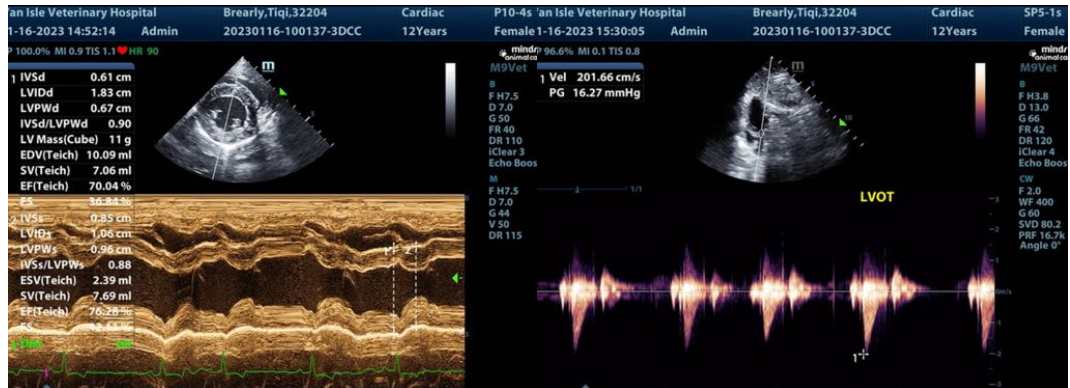
Dr. McFarlen

**INVOICE**

42153

**DATE**

1/16/23



The information and recommendations provided are based on the images presented by the referring veterinarian/sonographer. No evaluation can be communicated regarding pathology that was not visible in the image/video clips provided.

Thank you for this referral. If the clinical or image interpretation does not parallel your findings or if I can be of any further assistance please contact me.

Eric Lindquist, DMV, DABVP, Cert. IVUSS, CEO of SonoPath.com  
info@SonoPath.com