



PATIENT

Rajah Zuberbuehler

SPECIES

Feline

BREED

Domestic Longhair

SEX

Spayed female

AGE

11 years

WEIGHT

7 lbs

INTERPRETED BY

Eric Lindquist, DMV
DABVP, Cert. IVUSS

IMAGING PERFORMED BY

Jill Rumachik

HOSPITAL NAME

Clarity Imaging LLC

REFERRING VET

Dr. Heisler

INVOICE

42150

DATE

1/16/23

PRESENTING CLINICAL SIGNS

History: Recent onset vomiting (with blood), inappetence, and lethargy. Examined three days ago and started on cerenia and sucralfate (slurry). Some improvement. Known hyperthyroidism.
Abnormal PE/Chem/CBC/UA Results: 1/14/22: Chem, CBC - WNL. T4 elevated at 5.5 - increased methimazole dosing.

ULTRASONOGRAPHIC EXAMINATION OF THE ABDOMEN

Urinary System

The **urinary bladder**, trigone, and pelvic urethra presented normal thicknesses and normal tone. The ureters were not visible which is normal. No uroliths or sediment were visualized and anechoic urine was present. No evidence of inflammatory or neoplastic changes was noted. Ureteral papillae were normal.

The **kidneys** revealed largely normal size and structure, corticomedullary definition and ratio (cortex 1/3 of medulla) were essentially maintained with some age-related loss of curvilinear patterns regarding the capsule and C/M junction. The cortices presented largely uniform texture with some increased echogenicity expected for his age patient. Medullary structure differed distinctly from that of the cortex and no evidence of pelvic dilation was present. Both kidneys measure 3.0 cm.

Adrenal Glands

Both **adrenal glands** were visualized and recognized as having normal shape, size, position and echogenicity for this breed. The phrenic vasculature, glandular echogenicity and detail were unremarkable. Capsule, cortex, and medullary definition were normal for this age patient.

Spleen

The **spleen** presented a smooth homogeneous parenchyma hyperechoic to liver and renal cortical parenchyma. The capsule was smooth without noticeable expansion or deviation from within the spleen or adjacent pathology. The splenic vasculature demonstrated normal volume without signs of congestion or thrombosis. No sonographic evidence of acute or chronic inflammatory, neoplastic, or infarctual changes was noted.

Liver

The **liver** images from right and left intercostal as well as subcostal views revealed subjectively normal liver size, contour, and structure. Some age-related parenchymal remodeling was noted but likely not clinically significant at this time. Vascular and biliary tracts were of normal volume and no evidence of congestion was noted. The gallbladder presented some dependent debris with essentially normal contour. The cystic and common bile ducts were normal. No overt evidence of active inflammatory, infiltrative or regenerative pathology was noted but should be paired with current or past LE elevations regarding any clinical significance to this presentation. The hepatic lymph nodes were unremarkable.



PATIENT

Gastrointestinal

Rajah Zuberbuehler

The **stomach** in this patient presented variable pyloric and gastroesophageal fundic thickening without overt loss of detail. The majority of the small intestine was unremarkable including the ileocecal junction; however, a portion of jejunum was particularly thickened with slight regional lymphadenopathy that measured 1.0 x 0.5 cm. This portion of jejunum did lose mural detail. I am concerned for underlying emerging round cell neoplasia.

SPECIES

Feline

BREED

Pancreas

Domestic Longhair

The base and limbs of the **pancreas** were observed to be largely isoechoic to surrounding omental fat. Pancreatic duct and capsular contour were acceptably normal and parenchyma respected normal curvilinear patterns. No overt evidence of active inflammatory or neoplastic disease was noted.

SEX

Spayed female

ULTRASONOGRAPHIC FINDINGS

AGE

Inflammatory bowel with focal regional inflammation.

11 years

INTERPRETATION OF THE FINDINGS & FURTHER RECOMMENDATIONS

WEIGHT

7 lbs

Ideally surgical, gastric and jejunal biopsies would be performed in this patient to assess for a pre-neoplastic or early neoplastic state. Intraoperative ultrasound with full thickness biopsies would be ideal to localize more dramatic changes. The focal portion of jejunum that was thickened with a minor amount of reactive surrounding mesentery, which is indicative of transmural disease. Guarded prognosis. If sampling is not an option then the following protocol may prove effective.

INTERPRETED BY

Eric Lindquist, DMV
DABVP, Cert. IVUSS

Part or all of this protocol may be considered based on your clinical impression of the patient:

IMAGING PERFORMED BY

Jill Rumachik

Recommend pain management when anorexic with **Buprenorphine** (0.01-0.02 mg/kg IM or SC), clinical trial of **Zithromax** (50 mg sid/cat x 10 days, 3 weeks if bartonella +), **Prednisolone** (0.5-2 mg/kg tapering over 1 week to minimal effective dose), and **B12 injections** if weight loss (Cyanobalaminine 250 mcg sub-q once-weekly x six weeks, then every other week for six weeks and then once-monthly, long-term if necessary), **novel-protein or hydrolyzed diet** (*Hydrolyzed diets have been shown to be more effective in dietary intolerance case management compared to hypoallergenic diets*) or the **magical Purina DM** (changing protein source is crucial and may need rotation every 6 months if clinical signs recur) Diet trials is a whatever works phenomenon. If vomiting becomes a persistent issue then endoscopy would be warranted and/or recheck sonogram to assess more emerging disease. One diet does not work for all patients so different trials may be necessary or protein source rotation every 6 months as new sensitivities develop.

HOSPITAL NAME

Clarity Imaging LLC

REFERRING VET

Dr. Heisler

INVOICE

42150

DATE

1/16/23



PATIENT

Rajah Zuberbuehler

SPECIES

Feline

BREED

Domestic Longhair

SEX

Spayed female

AGE

11 years

WEIGHT

7 lbs

INTERPRETED BY

Eric Lindquist, DMV
DABVP, Cert. IVUSS

IMAGING PERFORMED BY

Jill Rumachik

HOSPITAL NAME

Clarity Imaging LLC

REFERRING VET

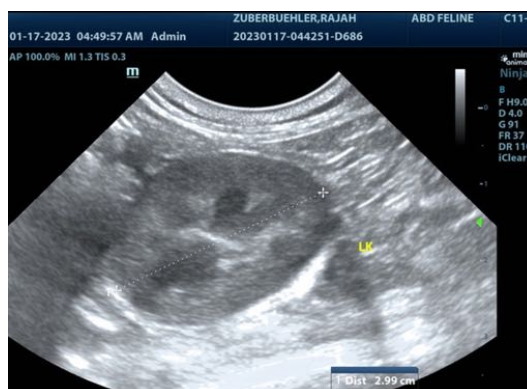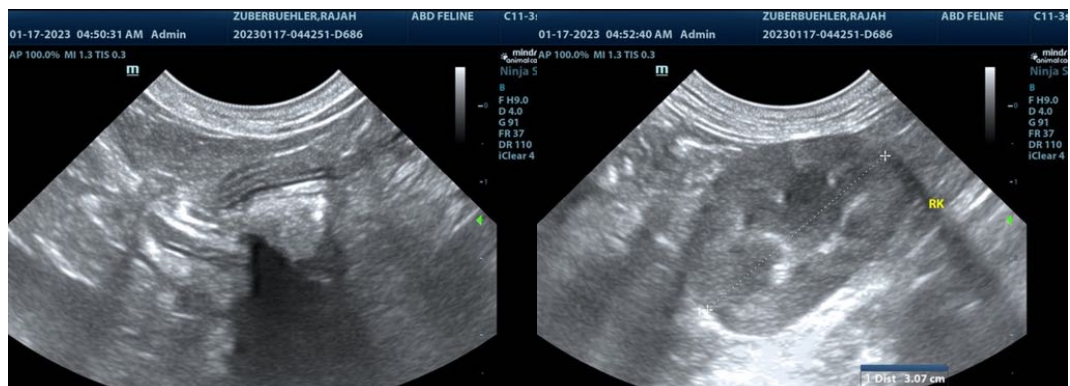
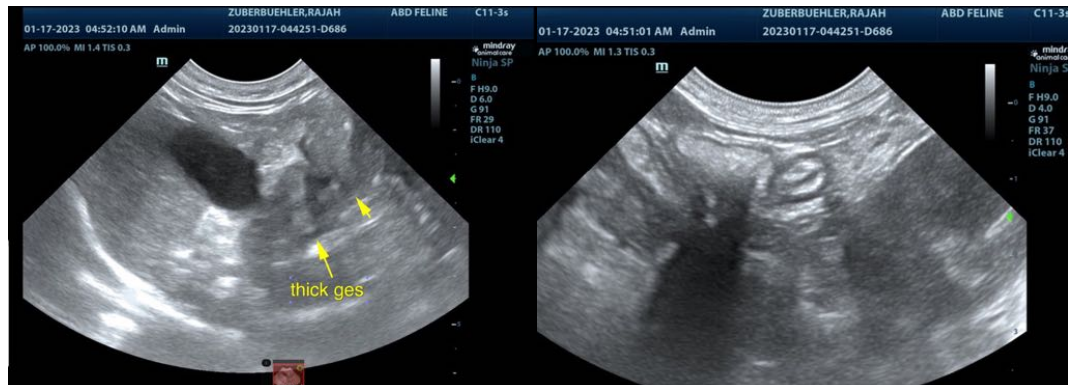
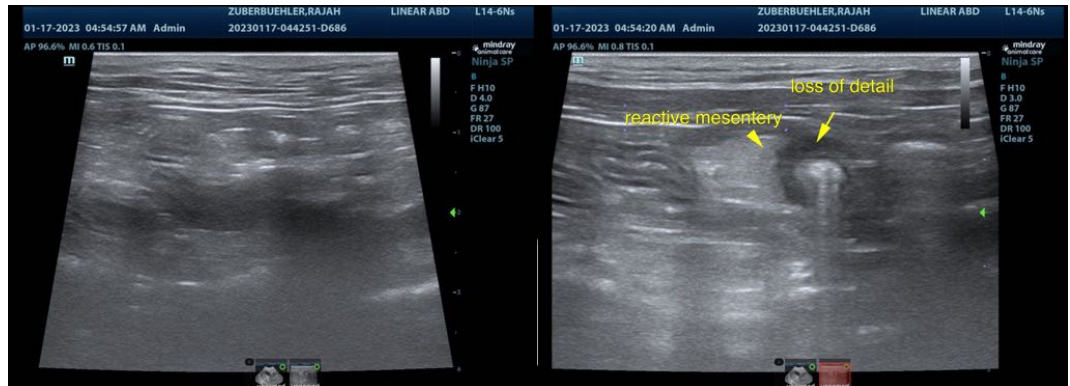
Dr. Heisler

INVOICE

42150

DATE

1/16/23





PATIENT

Rajah Zuberbuehler

The information and recommendations provided are based on the images presented by the referring veterinarian/sonographer. No evaluation can be communicated regarding pathology that was not visible in the image/video clips provided.

SPECIES

Feline

Thank you for this referral. If the clinical or image interpretation does not parallel your findings or if I can be of any further assistance please contact me.

BREED

Domestic Longhair

Eric Lindquist, DMV, DABVP, Cert. IVUSS, CEO of SonoPath.com
info@SonoPath.com

SEX

Spayed female

AGE

11 years

WEIGHT

7 lbs

INTERPRETED BY

Eric Lindquist, DMV
DABVP, Cert. IVUSS

**IMAGING
PERFORMED BY**

Jill Rumachik

HOSPITAL NAME

Clarity Imaging LLC

REFERRING VET

Dr. Heisler

INVOICE

42150

DATE

1/16/23