


PATIENT

Flower Ciminaro

PRESENTING CLINICAL SIGNS

History: Intermittent cough. Prev echo 3/22/22 with SonoPath. Currently on vetmendin. Heart murmur 4-5/6

SPECIES

Canine

ULTRASONOGRAPHIC EXAMINATION OF THE HEART

The echocardiogram in this patient demonstrated normal volumes in all four chambers with mitral valve prolapse of the anterior leaflet. Insufficiency was noted with elevated velocity. Blood pressure measurements are recommended. Contractility was adequate. The patient was tachycardic. Minor tricuspid insufficiency was noted. There was no pericardial or pleural effusion noted. There is no evidence of heart failure. This is most consistent with stage B1 valvular disease, yet prolapse is evident.

BREED

Chihuahua Longhair

SEX

Spayed female

AGE

16 years

WEIGHT

3.9 lbs

INTERPRETED BY

 Eric Lindquist, DMV
 DABVP, Cert. IVUSS

IMAGING PERFORMED BY

Dr. Rodriguez

HOSPITAL NAME

Foxfield VS

REFERRING VET

Dr. Rodriguez

INVOICE

41248

DATE

1/16/23

CANINE CARDIAC PARAMETERS	MR VMAX (m/s)	TR VMAX (m/s)	LA/AO (Boon method)	LA/AO (Heart Base)	FS (%)	EF (%)	EPSS (cm)
NORMAL PARAMETER	4.5-5.5	<2.7	1.3	<1.6	28-40	40-100	<0.6
PATIENT	6.0	3.0	1.2	1.54	44	79	0.1
CANINE CARDIAC PARAMETERS	HR (BPM)	AV VMAX (m/s)	PV MAX (m/s)	BODY WEIGHT	LA 2D short axis Base view (cm)	LVIDd Avg; 2D and m- mode short axis (cm)	LVIDs Avg; 2D and m- mode short axis (cm)
NORMAL PARAMETER	50-100	0.7-1.7	0.7-1.6	BELOW	BELOW	BELOW	BELOW
PATIENT	110		1.0	3.9 lbs	2.0	1.93	

ULTRASONOGRAPHIC FINDINGS

Stable stage B1 valvular disease.

INTERPRETATION OF THE FINDINGS & FURTHER RECOMMENDATIONS

The heart is stable without clinical disease. No overt contraindication for anesthesia of brief to moderate duration. I suggest Torbutrol premed, Propofol induction, Isoflurane maintenance or similar protocol if anesthesia is desired. Blood pressure recommended if not already performed and target white coat negative systolic pressure of < 160 mmHg. If higher than this ACE-inhibitor is suggested to reach this level. Recheck echocardiogram is recommended in 6 months, earlier if murmur grade increases or clinical signs initiate.



PATIENT

Flower Ciminaro

SPECIES

Canine

BREED

Chihuahua Longhair

SEX

Spayed female

AGE

16 years

WEIGHT

3.9 lbs

INTERPRETED BY

Eric Lindquist, DMV
DABVP, Cert. IVUS

IMAGING PERFORMED BY

Dr. Rodriguez

HOSPITAL NAME

Foxfield VS

REFERRING VET

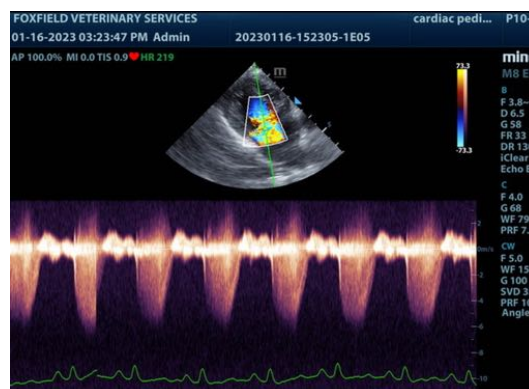
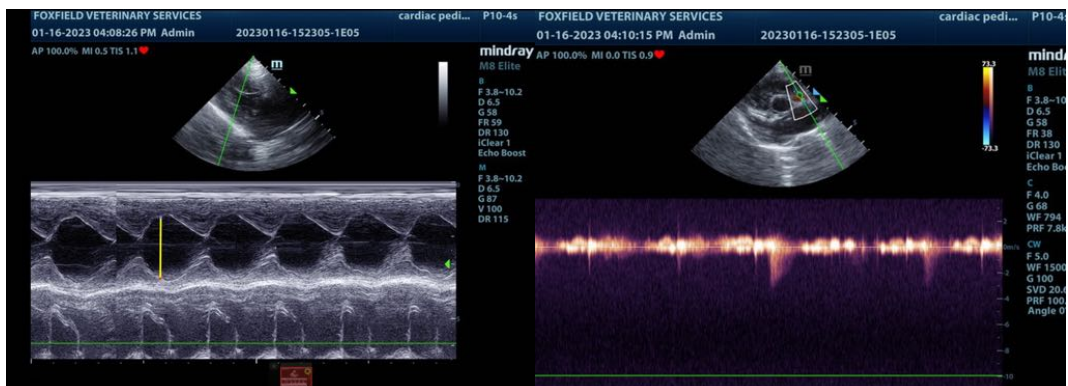
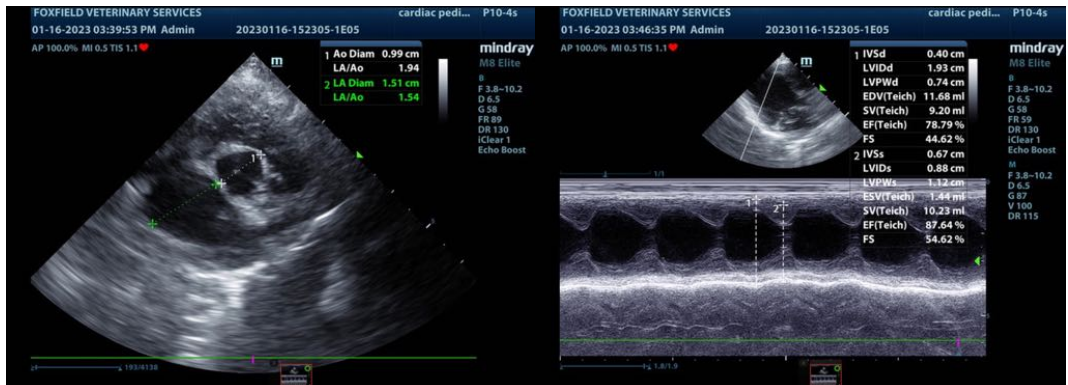
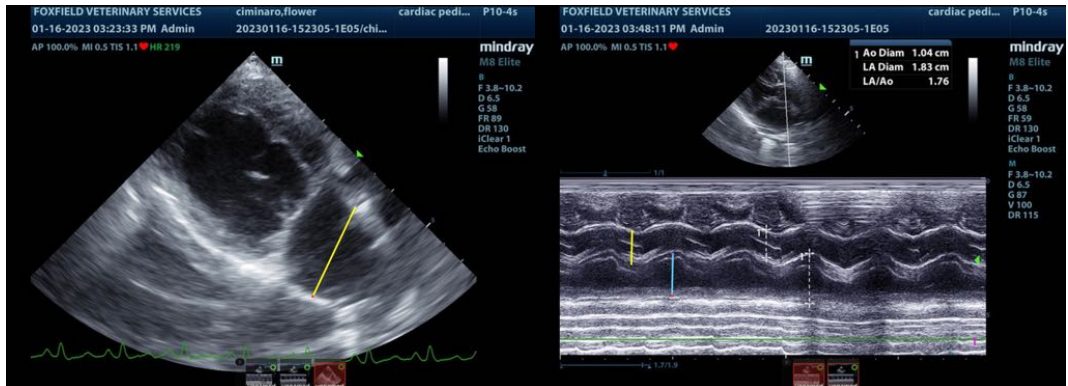
Dr. Rodriguez

INVOICE

41248

DATE

1/16/23





PATIENT

Flower Ciminaro

The information and recommendations provided are based on the images presented by the referring veterinarian/sonographer. No evaluation can be communicated regarding pathology that was not visible in the image/video clips provided.

SPECIES

Canine

Thank you for this referral. If the clinical or image interpretation does not parallel your findings or if I can be of any further assistance please contact me.

BREED

Chihuahua Longhair

Eric Lindquist, DMV, DABVP, Cert. IVUSS, CEO of SonoPath.com
info@SonoPath.com

SEX

Spayed female

AGE

16 years

WEIGHT

3.9 lbs

INTERPRETED BY

Eric Lindquist, DMV
DABVP, Cert. IVUSS

**IMAGING
PERFORMED BY**

Dr. Rodriguez

HOSPITAL NAME

Foxfield VS

REFERRING VET

Dr. Rodriguez

INVOICE

41248

DATE

1/16/23