


PATIENT

Dusty Amna

SPECIES

Feline

BREED

Persian

SEX

Male

AGE

13 years

WEIGHT

3.34 lbs

INTERPRETED BY

 Eric Lindquist, DMV
 DABVP, Cert. IVUSS

IMAGING PERFORMED BY

Dr. Inam ul haq

HOSPITAL NAME

 City Veterinary Clinic,
 Abu Dhabi

REFERRING VET

Dr. Inam ul haq

INVOICE

42150

DATE

1/16/23

PRESENTING CLINICAL SIGNS

History: The cat was presented with the complaint of pruritis. There was some history of cardiac disease which was suspected at another practice, but no diagnostics were run at that time. The RDVM noticed hepatomegaly on survey radiographs. The cat was referred for cardiac and abdominal ultrasound. Feline proBNP and FPLi results were abnormal. Arrhythmia was heard on auscultation

Abnormal PE/Chem/CBC/UA Results: Multiple cysts were noticed in the liver during the abdominal ultrasound exam. One cyst was also noticed in the right limb of the pancreas

ULTRASONOGRAPHIC EXAMINATION OF THE HEART

The cardiac presentation presented volume overload of the left and right atrium. A mild amount of smoke was noted in both atria. Septal and free wall thicknesses were normal. Mitral and tricuspid valve insufficiency was noted on color flow assessment. Contractility appeared adequate. Pericardial effusion was noted with occasional arrhythmia. Periodic tachyarrhythmia was noted.

FELINE CARDIAC PARAMETERS	BODY WEIGHT	HR (BPM)	IVSd (cm)	LVIDd (cm)	LVWd (cm)	FS (%)	EF (%)
NORMAL PARAMETER	-----	150-240	0.3-0.6	1.0-2.1	0.25-0.6	35-67	80-100
PATIENT	3.34	157	0.47	1.45	0.45	49	84
FELINE CARDIAC PARAMETERS	LA/AO (Boon)	LA/AO HEART BASE (Sisson)	LA 2D 4-chamber long axis AS to FW (Sisson) (cm)	LVOT VEL. (m/s)	RVOT VEL. (m/s)	IVRT (m/)	
NORMAL PARAMETER	<1.5	0.88-1.79	0.7-1.7	<1.6	<1.3	40-60	
PATIENT		2.1	2.09 max		0.72	NM	
Adapted from June Boon, Veterinary Echocardiography, 1998 Sisson D et al. JVIM 1991; 5: 232, Jacobs et al. Am J Vet Res 1985; 46:1705							

ULTRASONOGRAPHIC FINDINGS

Unclassified cardiomyopathy with left and right sided heart failure. Presuming hepatic vein dilation given the right atrial enlargement.

Arrhythmogenic disease and smoke.

Pericardial effusion. This is justified by left-sided volume overload and increased wedge pressure.

INTERPRETATION OF THE FINDINGS & FURTHER RECOMMENDATIONS

I recommend assessment for potential causes of myocarditis; however, triple therapy is warranted in this patient and off-label use of Pimobendan at 0.3 mg/kg b.i.d., ace inhibitor at 0.5 mg/kg s.i.d., Lasix at



PATIENT

Dusty Amna

6.25 mg b.i.d. and Plavix therapy. Recheck echocardiogram is recommended. Basal respiratory rate and body temperature is all warranted. Sleeping respiratory rate should be less than 25/minute. Although no overt dyspnea is noted, assessment for mild tachypnea is indicated. Recheck echocardiogram is recommended in 10 days. Taurine levels would also be warranted as well as nutritional evaluation to ensure that no underlying nutritional cardiomyopathy may be playing a role.

SPECIES

Feline

BREED

Persian

SEX

Male

AGE

13 years

WEIGHT

3.34 lbs

INTERPRETED BY

Eric Lindquist, DMV
DABVP, Cert. IVUSS

IMAGING PERFORMED BY

Dr. Inam ul haq

HOSPITAL NAME

City Veterinary Clinic,
Abu Dhabi

REFERRING VET

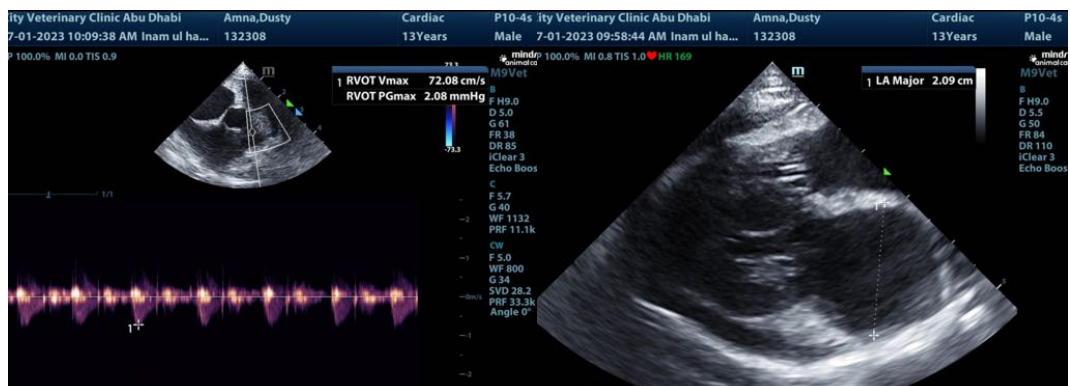
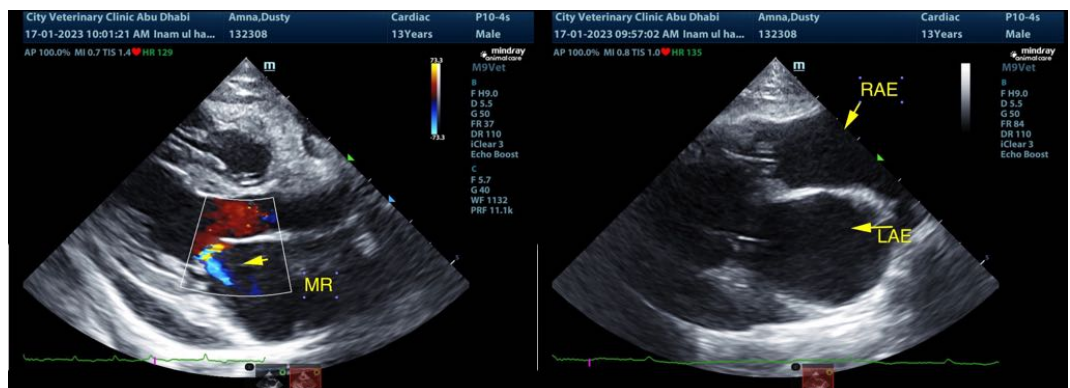
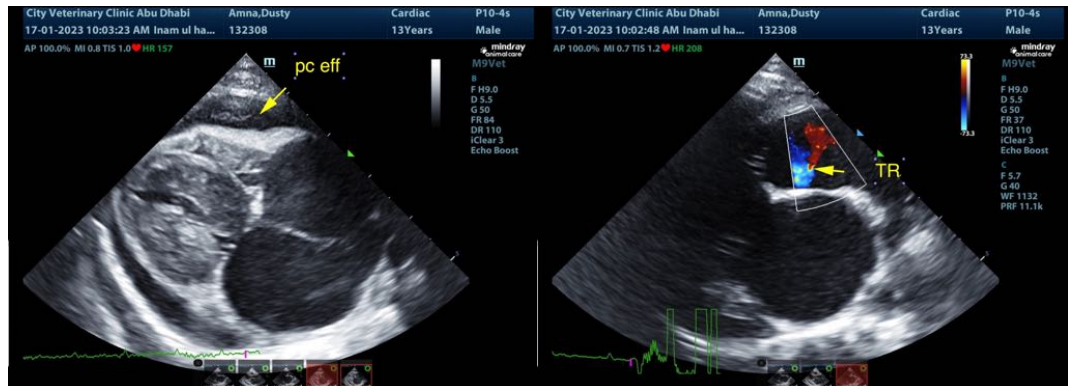
Dr. Inam ul haq

INVOICE

42150

DATE

1/16/23





PATIENT

Dusty Amna

SPECIES

Feline

BREED

Persian

SEX

Male

AGE

13 years

WEIGHT

3.34 lbs

INTERPRETED BY

Eric Lindquist, DMV
DABVP, Cert. IVUSS

IMAGING PERFORMED BY

Dr. Inam ul haq

HOSPITAL NAME

City Veterinary Clinic,
Abu Dhabi

REFERRING VET

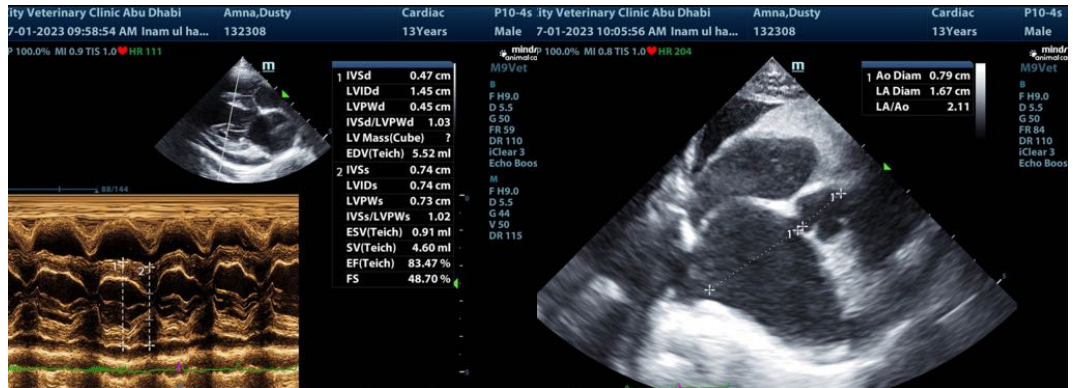
Dr. Inam ul haq

INVOICE

42150

DATE

1/16/23



The information and recommendations provided are based on the images presented by the referring veterinarian/sonographer. No evaluation can be communicated regarding pathology that was not visible in the image/video clips provided.

Thank you for this referral. If the clinical or image interpretation does not parallel your findings or if I can be of any further assistance please contact me.

Eric Lindquist, DMV, DABVP, Cert. IVUSS, CEO of SonoPath.com
info@SonoPath.com