



PATIENT

Capone Sengle

SPECIES

Canine

BREED

Pit Bull

SEX

Male

AGE

8

WEIGHT

65

INTERPRETED BY

Eric Lindquist, DMV

DABVP, Cert. IVUSS

IMAGING PERFORMED BY

Jenn

HOSPITAL NAME

Rockaway AH

REFERRING VET

Dr. Maniar

INVOICE

44246

DATE

1/16/23

PRESENTING CLINICAL SIGNS

Re heck previous u/s on 1/12 showed persistent retained ingesta and strongly shadowing gastric luminal echo.

LIMITED ULTRASONOGRAPHIC EXAMINATION

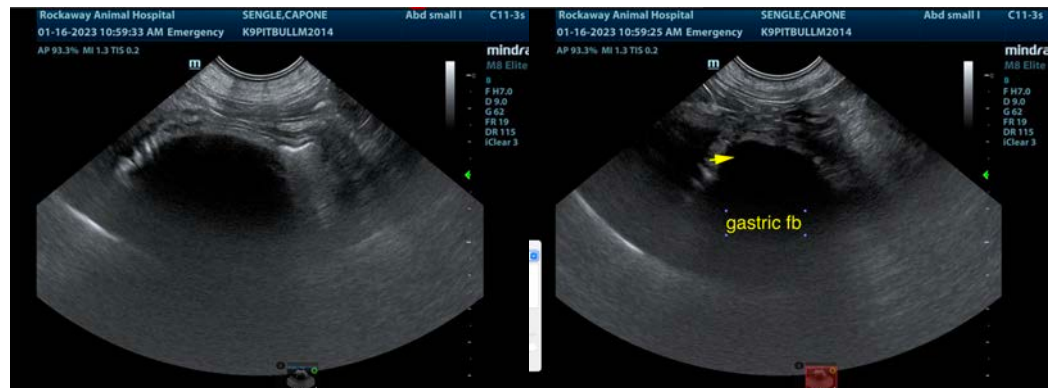
The stomach presented persistently shadowing gastric foreign body measuring approximately 3-4 cm, non-obstructive at the time of the sonogram. The small intestine and colon were unremarkable.

ULTRASONOGRAPHIC FINDINGS

- Persistent gastric foreign body

INTERPRETATION OF THE FINDINGS & FURTHER RECOMMENDATIONS

Gastroscopy or gastrotomy indicated.



The information and recommendations provided are based on the images presented by the referring veterinarian/sonographer. No evaluation can be communicated regarding pathology that was not visible in the image/video clips provided.

Thank you for this referral. If the clinical or image interpretation does not parallel your findings or if I can be of any further assistance please contact me.

Eric Lindquist, DMV, DABVP, Cert. IVUSS, CEO of SonoPath.com

info@SonoPath.com