



PATIENT

Hunter Marchesi

SPECIES

Canine

BREED

Toy Poodle Mix

SEX

Intact Male

AGE

6 Months

WEIGHT

6.67

INTERPRETED BY

Eric Lindquist, DMV,
DABVP(CFM), Cert.
IVUSS

IMAGING PERFORMED BY

Dr. Cassidy Stone

HOSPITAL NAME

Petroglyph Animal
Hospital

REFERRING VET

Dr. Cassidy Stone

INVOICE

13177

DATE

01/15/26

PRESENTING CLINICAL SIGNS

Sudden onset lethargy and icterus. P has a history of eating cherry pits on Saturday.

Abnormal PE/Chem/CBC/UA Results: ALT (431 U/L) and ALP (860 U/L); GGT 20 U/l, severe elevation in GGT (>27.9 mg/dL). Neutrophilia (21.72 K/uL) and monocytosis (2.25 K/uL) Regenerative anemia 25.8%

ULTRASONOGRAPHIC EXAMINATION OF THE ABDOMEN

Urinary System

The **urinary bladder**, trigone, and pelvic urethra to depth of 2.0 cm presented normal thicknesses and normal tone. The ureters were not visible which is normal. No uroliths or sediment were visualized, and anechoic urine was present. No evidence of inflammatory or neoplastic changes were noted. Ureteral papillae were normal.

The **prostate** measured 7.0 mm.

The **kidneys** revealed normal size and structure, corticomedullary definition and ratio for this age. The cortices presented largely uniform texture with normal echogenic relationship to liver and spleen. Medullary structure differed distinctly from the cortex and no evidence of pelvic dilation was present. The capsules were acceptably uniform without significant irregularities. The left kidney measured 3.4 cm in length. The right kidney measured 3.4 cm in length.

Adrenal Glands

The regions of the **adrenal glands** were imaged with no evident pathology.

Spleen

The **spleen** in this patient was uniform, yet volume contracted. Hydration status should be assessed.

Liver

The **liver** presented diffusely heterogenous and hyperechoic. The gallbladder was double layered and edematous.

Gastrointestinal

The **stomach** in this patient was severely dilated with dependent and suspended chyme. Variable gastric wall thickening was noted in the gastric fundus and pylorus. The small intestine and colon were unremarkable.

Pancreas

Pancreatic edema was noted as well as mild heterogenous parenchymal changes and free fluid.

Free Abdomen

The mesenteric **lymph nodes** presented normal length to width ratio with slight, swollen contour. There was no loss of parenchymal detail. This is most consistent with reactive lymphadenitis or lymphatic hyperplasia. The lymph nodes measured up to 1.0 cm.



PATIENT

Hunter Marchesi

SPECIES

Canine

BREED

Toy Poodle Mix

SEX

Intact Male

AGE

6 Months

WEIGHT

6.67

INTERPRETED BY

Eric Lindquist, DMV,
DABVP(CFM), Cert.
IUUSS

IMAGING PERFORMED BY

Dr. Cassidy Stone

HOSPITAL NAME

Petroglyph Animal
Hospital

REFERRING VET

Dr. Cassidy Stone

INVOICE

13177

DATE

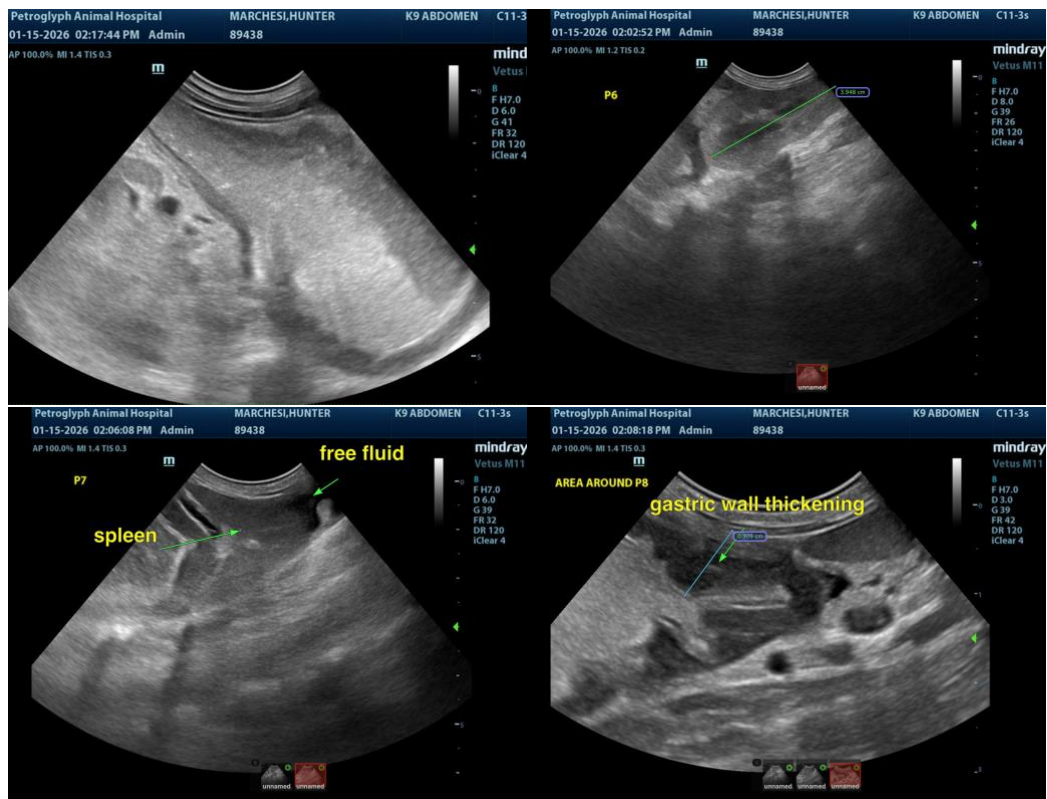
01/15/26

ULTRASONOGRAPHIC FINDINGS

- Acute toxic insult involving the stomach and the liver with secondary pancreatic edema- no evidence of obstructive foreign bodies.
- Mild reactive lymphadenopathy.
- Volume contracted spleen.

INTERPRETATION OF THE FINDINGS & FURTHER RECOMMENDATIONS

Aggressive IV fluid support, plasma expanders, potential plasma transfusion may be necessary in this patient. Eventual coagulation panel and 25-gauge FNA of the liver is indicated. Assessment for toxin exposure is recommended. Prognosis is guarded depending upon response to therapy. Recheck sonogram in 48-72 hours.





PATIENT

Hunter Marchesi

SPECIES

Canine

BREED

Toy Poodle Mix

SEX

Intact Male

AGE

6 Months

WEIGHT

6.67

INTERPRETED BY

Eric Lindquist, DMV,
DABVP(CFM), Cert. IVUSS

IMAGING PERFORMED BY

Dr. Cassidy Stone

HOSPITAL NAME

Petroglyph Animal Hospital

REFERRING VET

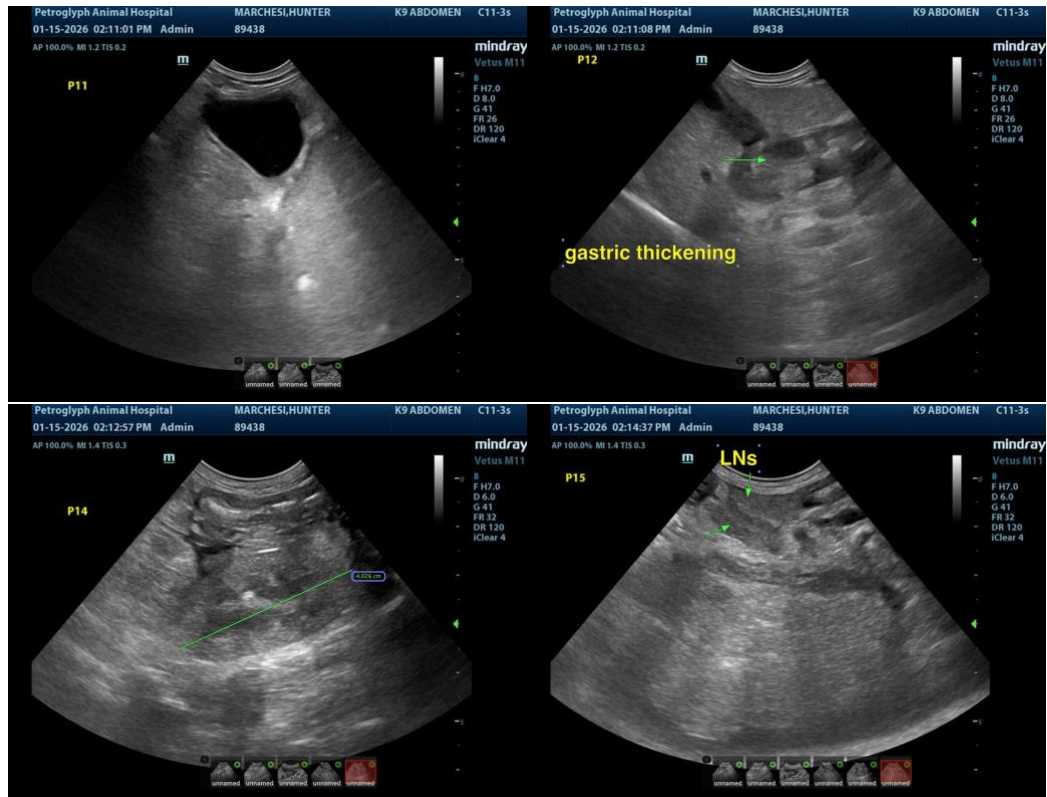
Dr. Cassidy Stone

INVOICE

13177

DATE

01/15/26



The information and recommendations provided are based on the images presented by the referring veterinarian/sonographer. No evaluation can be communicated regarding pathology that was not visible in the image/video clips provided.

Thank you for this referral. If the clinical or image interpretation does not parallel your findings or if I can be of any further assistance, please contact me.

Eric Lindquist, DMV, DABVP(CFM), Cert. IVUSS,

CEO, Owner, Founder -- SonoPath.com

info@SonoPath.com