


**DATE PRESENTING CLINICAL SIGNS**

01/15/26

Patient History: Patient seen June of last year for hematuria. Abdominal radiographs at that time revealed evidence of bladder stones, supported by urinalysis findings. Initial management included a prescription urinary diet trial, reassessed six weeks later with no change in the bladder stones. The owner elected to proceed with cystotomy, and stones were submitted to Minnesota for analysis. Results confirmed urate stones. The patient was transitioned to a urate control diet. The presence of urate stones raised concern for MVD vs PSS. Clinically, the patient has been doing well. Bile acids testing performed in September showed elevated pre and post prandial values. Most recent laboratory work shows a mild increase in ALT.

**PATIENT**

Harley LoZito

**SPECIES**

Canine

Current Medications: Royal Canin UD

Labwork Results: Labwork not submitted. Reported as 1/13/2026 ALT 166 (18-121) AST 98 (16-55). 9/2025 Bile Acids Pre 473.3 (0-14.9) Post 284.8 (0-29.9).

**BREED**

Yorkshire Terrier

Date of Previous IntraPet Ultrasound: No previous.

Sedation: Propofol to effect.

Stat Report: Not requested.

Imaging Performed by: Andi Parkinson, BS, RDMS.

**SEX**

Neutered Male

**ULTRASONOGRAPHIC EXAMINATION OF THE ABDOMEN**
**AGE**

03/07/17

**Urinary System**

The **urinary bladder**, trigone, and pelvic urethra presented normal thicknesses and normal tone. The ureters were not visible which is normal. No uroliths or sediment were visualized, and anechoic urine was present. No evidence of inflammatory or neoplastic changes were noted. Ureteral papillae were normal.

**WEIGHT**

8.78 pounds

The **right kidney** was normal in size and contour with corticomedullary and pelvic calculi. The right kidney measured 4.22 cm in length.

**INTERPRETED BY**

 Eric Lindquist, DMV,  
 DABVP(CFM), Cert.  
 IVUSS

The **left kidney** presented with calculi. The left kidney measured 3.9 cm in length.

**Adrenal Glands**

The **right adrenal gland** was not visualized.

**HOSPITAL NAME**

 Northwind Animal  
 Hospital

The **left adrenal gland** revealed a hyperechoic nodule at the cranial pole measuring 0.60 cm.

**Spleen**

The **spleen** presented a smooth homogeneous parenchyma hyperechoic to liver and renal cortical parenchyma. The capsule was smooth without noticeable expansion or deviation from within the spleen or adjacent pathology. The splenic vasculature demonstrated normal volume without signs of congestion or thrombosis. No sonographic evidence of acute or chronic inflammatory, neoplastic, or infarctual changes were noted.

**REFERRING VET**

Dr. Wilson

**INVOICE**

13183

**Liver**

The **liver** was subnormal in size. The hepatic parenchyma presented with hypovascularity. The portal vein was subnormal in size measuring 0.25 cm to 0.30 cm. The vena cava measured 0.50 cm. The aorta measured 0.55 cm. A large 0.70 cm to 1.0 cm wide spleno-azygous shunt was noted in this patient entering into the thorax through the esophageal inlet or aortic hiatus.

Excessive gallbladder debris was noted with some striation consistent with emerging mucocele.

### ***Gastrointestinal***

**Gastric** stasis was noted. The pylorus was patent. The small intestine and colon were unremarkable.

### ***Pancreas***

The base and limbs of the **pancreas** were observed to be largely isoechoic to surrounding omental fat. Pancreatic duct and capsular contour were acceptably normal and parenchyma respected normal curvilinear patterns. No overt evidence of active inflammatory or neoplastic disease was noted.

### **ULTRASONOGRAPHIC FINDINGS**

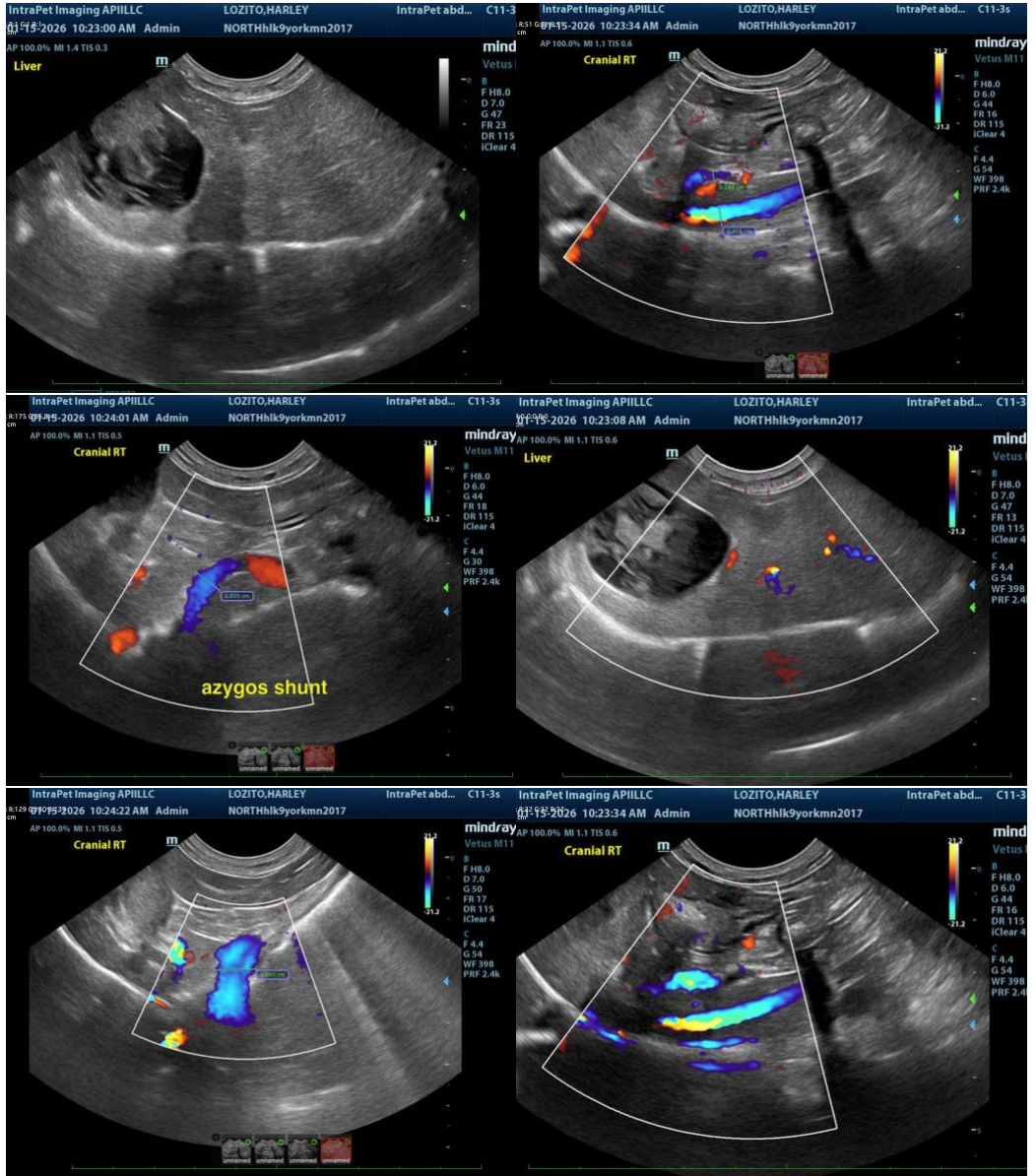
- Spleno-azygous shunt with emerging gallbladder mucocele.
- Nonobstructive renal calculi.
- Slight left adrenal nodule- likely hyperplasia with potential for adenoma, adenocarcinoma, pheochromocytoma unlikely.
- Gastric stasis.

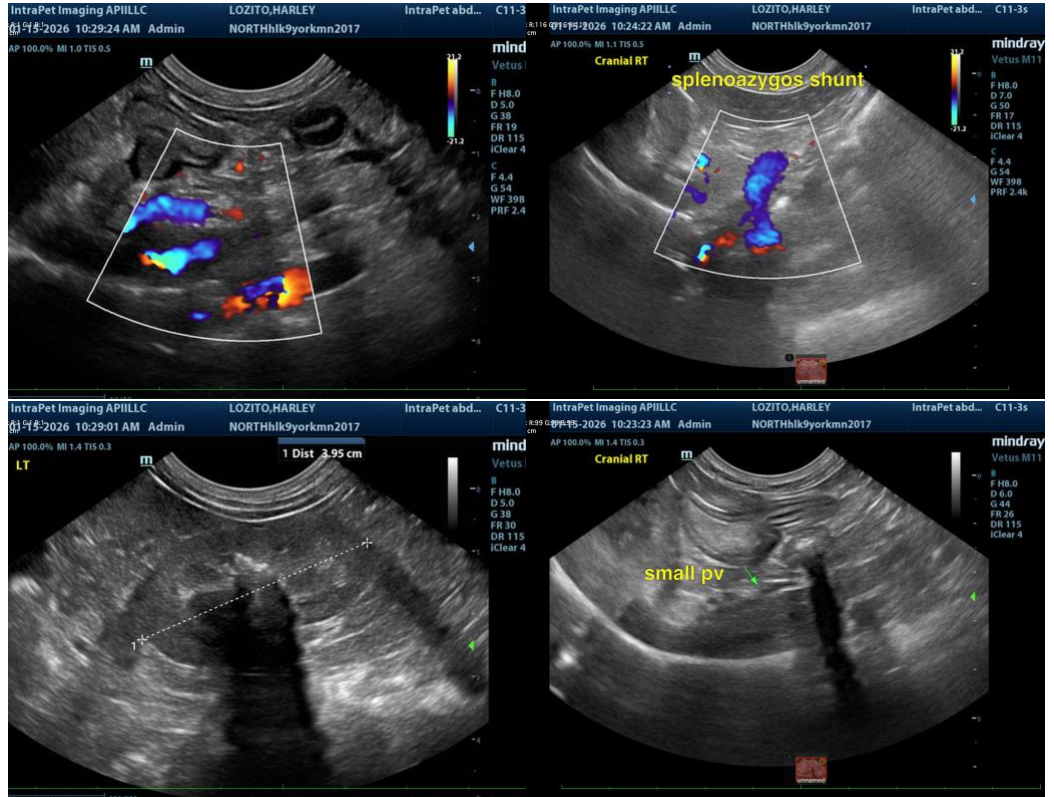
### **INTERPRETATION OF THE FINDINGS & FURTHER RECOMMENDATIONS**

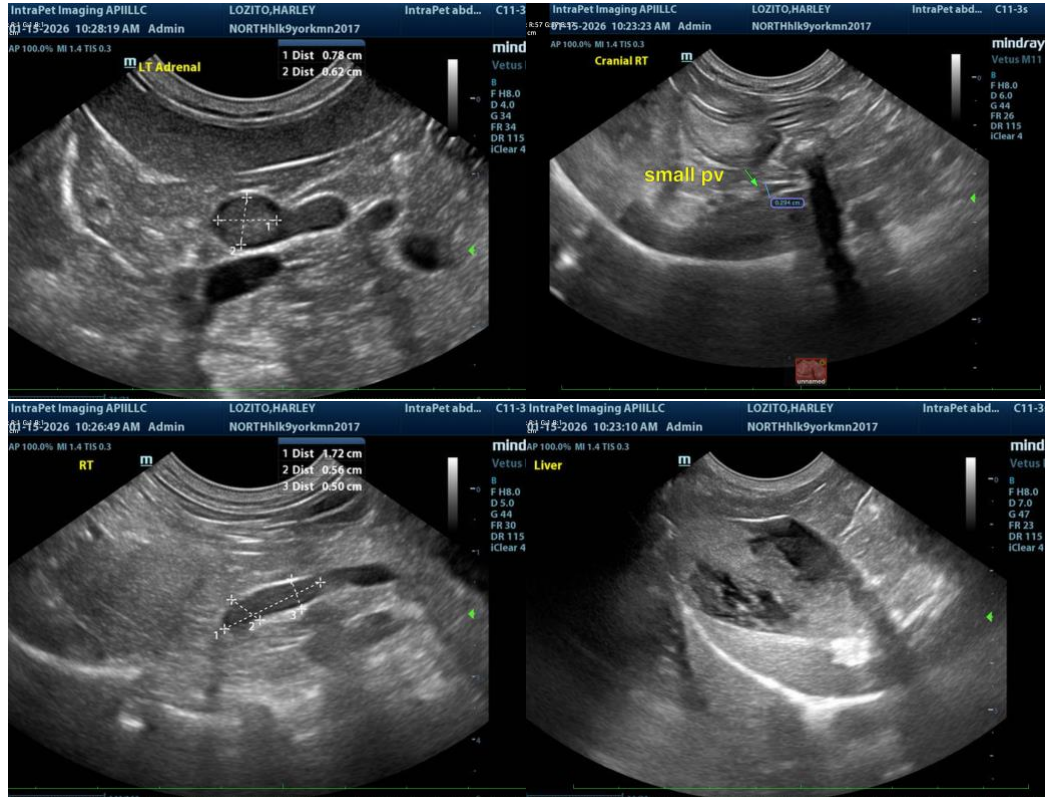
CT evaluation for surgical planning and shunt correction would be ideal. Concurrent inflammatory hepatopathy given the patient's history.

#### **Hepatic Support for Bile Acid Elevation +/- Hepatic Encephalopathy**

**Royal Canin Hepatic Support diet or Hills L/D, Metronidazole** (7.5 mg/kg PO bid) over the next 14 days, **Lactulose** (Oral: 3.1-3.7 g/5 ml lactulose in a syrup base) long term to target 2-3 soft stools/day, with a **high-quality protein supplement** of minor amount of **yogurt** or **cheddar cheese**. Monitor bile acids, with attention paid to dropping albumin, BUN or cholesterol. **SAMe** and nutraceuticals as needed. **Ursodiol** (10-15 mg/kg p.o. q24h) can be considered as hepatoprotectant and to enhance bile flow. **Zinc** serum level keep between 200–500 ug/dl. If deficient then Tx zinc acetate 1-3 mg/kg/day. Gastrointestinal protectants are recommended if the patient is anorexic.







The information and recommendations provided are based on the images presented by the referring veterinarian/sonographer. No evaluation can be communicated regarding pathology that was not visible in the image/video clips provided.

Thank you for this referral. If the clinical or image interpretation does not parallel your findings or if I can be of any further assistance, please contact me.

Eric Lindquist, DMV, DABVP(CFM), Cert. IVUSS,

CEO, Owner, Founder -- SonoPath.com

[info@SonoPath.com](mailto:info@SonoPath.com)

## **Bile Acid Elevations and Hepatic Vascular Disorders: Portosystemic Shunts and Portal Vein Hypoplasia (Microvascular Dysplasia)**

<http://www.sonopath.com/BAShunts>

### ***Non-Shunt Pathologies and Elevated Bile Acid Levels***

**Description:** Bile acids are conjugated with cholesterol in the liver; they then enter the biliary tree and

are stored in the gallbladder. Under the stimulation of cholecystokinin, the gallbladder contracts and bile acids are released from the cystic duct into the common bile duct; they then pass through the sphincter of Oddi to reach the duodenum. Bile acids are absorbed primarily in the ileum (95%), and then reenter the portal system and move into the liver. This enterohepatic circulation cycle can occur 2-5 times within the space of a single meal. When bile flow is obstructed and the bile secretory pressure reaches 30 cm H<sub>2</sub>O, bile acids accumulate in the blood. Obstruction can occur due to calculi, the accumulation of acids (also known as “bile sludge”) in the common bile duct, or extrahepatic obstruction, such as pancreatitis. Unconjugated bile acids are cytotoxic and result in inflammation, intestinal necrosis, poor permeability, bacterial translocation, sepsis, endotoxemia, poor micelle formation, and a deficiency of fat-soluble vitamins.

### **Causes of Bile Acid Elevation:**

#### 1. Nonhepatic Causes

- Inflammatory bowel disease or intestinal dysbiosis
- Delayed gastric emptying
- Spontaneous gallbladder contraction
- Hypertriglyceridemia or lipemia
- Ursodeoxycholic acid treatment
- Severe disease or resection of the ileum (site of bile acid reabsorption)
- Cholecystectomy
- Prolonged anorexia
- Hyperadrenocorticism
- Pancreatitis
- Transient elevation, which occurs most commonly in Irish wolfhound puppies

#### 2. Hepatic Causes

- Diffuse hepatocellular disease
- Cholestatic disease
- Primary portal vein hypoplasia or microvascular dysplasia

### ***Hepatic Vascular Diseases***

**Description:** Hepatic vascular diseases can be divided into congenital and acquired forms. Congenital disorders include: portosystemic shunting (PSS) or portosystemic vascular anomalies (PSVA), both intrahepatic (IHPSS) and extrahepatic (EHPSS); microhepatic PSS, also called portal vein hypoplasia (PVH) (previously known as microvascular dysplasia [MVD]) without portal hypertension; portal vein atresia; and hepatic arteriovenous (AV) malformations. Acquired forms include: acquired shunting secondary to portal hypertension due to primary hepatic disease; fibrosis/cirrhosis; and non-cirrhotic portal hypertension. Although PSVA can result in elevated liver enzymes and bile acids, other possible causes for elevated bile acids include, but are not limited to: diffuse hepatocellular disease; cholestatic disease; cholecystectomy; spontaneous gallbladder contraction; ursodeoxycholic acid use; inflammatory bowel disease; hyperlipidemia; prolonged anorexia; hyperadrenocorticism; pancreatitis; severe ileal disease or resection; delayed gastric emptying; prolonged or rapid intestinal transit time; small intestinal bacterial overgrowth; and breed-associated increases, as observed in the Maltese breed, for example, in the absence of primary hepatic disease. Given the long list of differentials, the assessment for PSVA often depends on the clinical presentation, such as signalment, clinical signs, and specific laboratory findings, which may suggest PSVA. Ultrasound and additional diagnostics are imperative in the diagnostic process.

The following canine breeds—typically small breed dogs—are predisposed to congenital extrahepatic shunting: Miniature Schnauzer, Yorkshire Terrier, Pug, Dachshund, Cairn Terrier, Shih Tzu, West Highland White Terrier, Bichon Frisé, Havanese, Dandie Dinmonts, and Maltese. Extrahepatic shunts often involve a shunt from the portal vein (PV), left gastric, or splenic vein, to the caudal vena cava. The shunt may occasionally enter the azygous vein dorsally, bypassing the vena cava (VC). The following breeds—typically large breed dogs—are predisposed to intrahepatic shunting: Irish Wolfhound, Australian Cattle Dog, Australian Shepherd, Golden Retriever, Old English Sheepdog, and Labrador Retriever. Intrahepatic shunting in the latter breeds most commonly presents as a shunt between the PV and the caudal vena cava, and may coexist with PVH. Yorkshire Terriers and Cairn Terriers are predisposed to PVH.

PVSA are not seen as commonly in cats compared to dogs. In cats, extrahepatic PSVA usually arise from the left gastric vein; they also often have a patent ductus venosus. The following feline breeds are predisposed to PVSA: domestic shorthair, Persian, Siamese, Himalayan, and Burman.

**Clinical Signs:** Dogs affected with PVH uniquely are typically asymptomatic and their hepatic vascular abnormalities are non-progressive; however, patients with severe PVH may sometimes display clinical signs similar to those with PSVA.

A patient with PSVA is often more symptomatic; clinical findings vary. Dogs and cats with PSVA often have smaller bodies compared to their litter mates, and may exhibit anorexia, vomiting, diarrhea, depression, lethargy, ataxia, head pressing, “stargazing,” behavioral changes, seizures, and/or coma. Drooling is common in cats, but can be seen in dogs as well. Renomegaly is common in patients with PSVA, and polyuria and polydipsia (PU/PD) can occur due to low BUN in the face of hepatic insufficiency. Signs of lower urinary tract disease manifest if urate calculi have formed. Animals with PSVA also have

an increased susceptibility to infections due to reduced Kupffer cell function. Minor bite wounds, tick bites, subcutaneous infections, lacerations, and even vaccinations may cause illness that can require hospitalization. Cats with PSVA may have copper-colored irises (36%). Dogs with portoazygous shunts are generally the least symptomatic and frequently present with ammonium biurate calculi as adults; their disorder is often discovered serendipitously. Generally, asymptomatic dogs (15-20%) whose PSVA is only detected later in life usually respond well to PSVA ligation. Acquired shunting may occur later in life secondary to chronic hepatic disease and can result in portal hypertension and ascites.

**Diagnosics:** Clinicopathologic findings for both PSVA and PVH may include mild hypoalbuminemia, hypoglycemia, hypocholesterolemia, microcytosis (low MCV), and hypochromasia. One may also note the following: borderline, non-regenerative anemia; target cells; low BUN; low creatinine; normal to variable increases in liver enzymes (mild to modest); and ammonium biurate crystalluria (a minimum of 3 urine specimens should be examined). Radiographic findings may include microhepatica in dogs; however, liver size is variable in cats, and kidneys may be large in both species. Contrast portography yields varying patterns in patients with PSVA. Fasting plasma ammonium determination is more sensitive than bile acid profiles when gauging the presence of either congenital or acquired shunting; however, ammonium levels must be measured immediately upon collecting blood in a lithium heparin tube. The ammonium tolerance test or baseline ammonium level measurement is not practical if in-house testing is not available. Most dogs with PSVA have postprandial bile acid concentrations greater than 100 nmol/L, but values do not correlate with the severity of the disease. Dogs with PSVA have lower clotting factor activity than healthy dogs; this can cause complications during surgery. Protein C is an anti-thrombotic protein that is synthesized in the liver; it is used as a hepatic function test in people and is a better indicator of portal venous flow than total serum bile acids. In combination with serum bile acids, it can help differentiate PSVA from PVH, as dogs with PVH will have more normal protein C levels than those with PSVA. Markedly low levels of protein C suggest that a patient is likely a poor candidate for surgical ligation and also help identify dogs with hepatic failure.

**Treatment:** The majority of dogs affected with PVH alone do not require medical treatment and have a normal life expectancy. The severity of clinical signs in symptomatic PSVA patients is highly variable and can be regulated in large part by an appropriately formulated low-protein diet. Surgical treatment for PSVA is the subject of much debate; however, a recent study confirmed that long-term survivability was improved by surgical correction. Medical management remains a reasonable alternative. If surgery is to be pursued, it should be considered in light of comorbidities that influence hepatic integrity. Extrahepatic shunts are more accessible and therefore more amenable to ameroid ring constriction or shunt ligation, while intrahepatic shunts are often difficult to access surgically, as they are positioned deep within the liver parenchyma but may be closed with coil embolization under fluoroscopic guidance. Other considerations include whether the patient should be stabilized medically before surgery is attempted or if full recovery is to be expected once the PSVA is closed. The most common and severe complications of surgical ligation include portal hypertension and ascites, which is why slow attenuation via ameroid ring placement is often preferred, as well as the development of seizures/status epilepticus. Seizure development cannot always be predicted and is more common in small breed dogs, especially Maltese, and in cats.

The medical management of PSVA primarily involves restricting dietary protein (2.2-2.5 g/kg/day of protein, administered in small, frequent meals). Protein sources such as dairy, soy, and egg are enriched in branched-chain amino acids, which bypass liver metabolism and help reduce blood ammonia levels. Unsuccessful medical management is determined by recurrent hepatic encephalopathy or persistent ammonium biurate crystalluria. In both cases, if the animal has PSVA, one should consider surgical intervention or additional medical therapy. Lactulose should be started at a low dose (0.25 ml-1 ml/kg BID-TID) and titrated to achieve several soft stools per day. It acidifies the pH in the colon, which reduces urease activity and reduces urease-producing bacteria. Antibiotics, such as metronidazole (7.5 mg/kg PO BID) and neomycin (22 mg/kg PO BID), are utilized to modify enteric flora and reduce toxin production from urease-producing bacteria. Dogs with unresponsive hepatic encephalopathy are also managed with retention enemas (5-10 ml/kg with 20% lactulose), which rapidly acidify colonic contents.

**Conclusion:** PSVA and PVH are not uncommon in veterinary medicine. Medical therapy as well as surgical correction must be considered carefully in light of clinical presentation and shunt location. In all cases, dietary modification is the first-line treatment of choice; however, mild cases of PVH may not even require diet change.

#### **References:**

Allen L, Stobie D, et al. Clinicopathologic features of dogs with hepatic microvascular dysplasia with and without portosystemic shunts: 42 cases (1991-1996). *J Am Vet Med Assoc* 1999;214:218-20.

Christiansen JS, Hottinger HA, Allen L, et al. Hepatic microvascular dysplasia in dogs: a retrospective study of 24 cases 1987-1995). *J Am Anim Hosp Assoc* 2000;36:385-89.

Gerritzen-Bruning MJ, van den Ingh TS, Rothuizen J. Diagnostic value of fasting plasma ammonia and bile acid concentrations in the identification of portosystemic shunting in dogs. *J Vet Intern Med* 2006;20:13-19.

Greenhalgh SN, Dunning MD, McKinley TJ, et al. Comparison of survival after surgical or medical treatment in dogs with a congenital portosystemic shunt. *J Am Vet Med Assoc* 2010;236:1215-20.

Hunt GB. Effect of breed anatomy of portosystemic shunts resulting from congenital diseases in dogs and cats: A review of 242 cases. *Aust Vet J* 2004;82:746-49.

Kummeling A, Teske E, Rothuizen J, et al. Coagulation profiles in dogs with congenital portosystemic shunts before and after surgical attenuation. *J Vet Intern Med* 2006;20:1319-26.

Lamb CR, Daniel GB. Diagnostic imaging of dogs with suspected portosystemic shunting. *Compend Contin Educ Pract Vet* 2002;24:626-35.

Schermerhorn T, Center Sa, Dykes NL et al. Characterization of hepatoportal microvascular dysplasia in a kindred of cairn terriers. *J Vet Intern Med* 1996;10:219-30.

Toulza O, Center S, Brooks M, et al. Evaluation of plasma protein C activity for detection of hepatobiliary disease and portosystemic shunting in dogs. *J Am Vet Med Assoc* 2006;229:1761-71.

Windsor RC, Olby NJ. Congenital portosystemic shunts in five mature dogs with neurological signs. *J Am Anim Hosp Assoc* 2007;43:322-31.