



PATIENT

Grace Ostenfeld

SPECIES

Canine

BREED

Chihuahua

SEX

Spayed Female

AGE

14 Years

WEIGHT

5 lbs

PRESENTING CLINICAL SIGNS

MMVD B1 – prior echo 1/2/25. Pimobendan 1.25 mg ½ SID.

ULTRASONOGRAPHIC EXAMINATION OF THE HEART

CANINE CARDIAC PARAMETERS	MR VMAX (m/s)	TR VMAX (m/s)	LA/AO (M-Mode)	LA/AO (Heart Base; Swe)	FS (%)	EF (%)	EPSS (cm)
NORMAL PARAMETER	4.5-5.5	<2.7	1.3	Up to 1.6	28-40	40-100	<0.6
PATIENT	--	--	1.2	1.3	61	92	NM
CANINE CARDIAC PARAMETERS	HR (BPM)	AV VMAX (m/s)	PV MAX (m/s)	BODY WEIGHT (lbs)	LAD LA MAX 4 Chamber	LVIDd Avg; 2D and m-mode short axis (cm)	LVIDs Avg; 2D and m-mode short axis (cm)
NORMAL PARAMETER	50-100	0.7-1.7	0.7-1.6				
PATIENT	90	1.4	0.95	5	1.9	1.94	--

INTERPRETED BY

Eric Lindquist, DMV, DABVP (CFM), Cert. IVUSS

IMAGING PERFORMED BY

Eric Lindquist, DMV, DABVP (CFM), Cert. IVUSS

HOSPITAL NAME

Franklin Lakes Animal Hospital

REFERRING VET

Dr. Greenhut

INVOICE

72232

DATE

1/15/26

Cardiac Presentation

The echocardiogram in this patient demonstrated normal **left atrial** size based on 3 different LA measurement methods. Chamber volumes and echogenicity were normal. The cranial and caudal **mitral** valve leaflets presented vegetative thickening consistent with endocardiosis. Doppler indicated moderate insufficiency. Prolapse of the anterior mitral valve leaflet noted. The **left ventricle** presented thicknesses with linear contour and was not dilated nor restricted. The **myocardium** presented normal echogenicity without subjective evidence of significant fibrotic or ischemic disease. **Contractility** of the ventricular walls was adequate and in normal range for this patient evidenced by the fractional shortening measurement and subjective evaluation of the different regions of the myocardium. The **left ventricular outflow** tract demonstrated normal laminar flow and subjective structural integrity. The **right atrium** and auricle revealed normal size, structure and content. No evidence of masses was noted or chamber overload. **Tricuspid** valvular assessment demonstrated adequate linear morphology. The **right ventricle** was of normal size (1/3 diameter of LV), chordae structure, myocardial echogenicity and thickness. **Pulmonic** tract assessment revealed normal valve structure, laminar flow, and diameter (approx. 1:1 pa/ao ratio). No visible **pericardial** or free pleura fluid was noted. No echographically detectable evidence of infiltrative disease was visible. The cranial **mediastinum** and **pericardial** regions were free of masses in the visible window.

ULTRASONOGRAPHIC FINDINGS

- Compensated mitral disease with prolapse, no volume overload.

INTERPRETATION OF THE FINDINGS & FURTHER RECOMMENDATIONS

Recommend continuation of the current protocol.



PATIENT

Grace Ostenfeld

SPECIES

Canine

BREED

Chihuahua

SEX

Spayed Female

AGE

14 Years

WEIGHT

5 lbs

INTERPRETED BY

Eric Lindquist, DMV,
 DABVP (CFM), Cert.
 IVUSS

IMAGING PERFORMED BY

Eric Lindquist, DMV,
 DABVP (CFM), Cert.
 IVUSS

HOSPITAL NAME

Franklin Lakes Animal
 Hospital

REFERRING VET

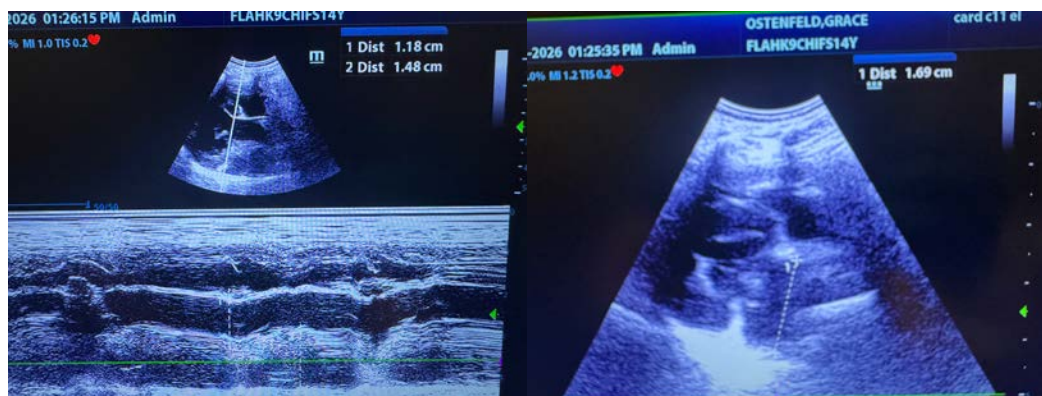
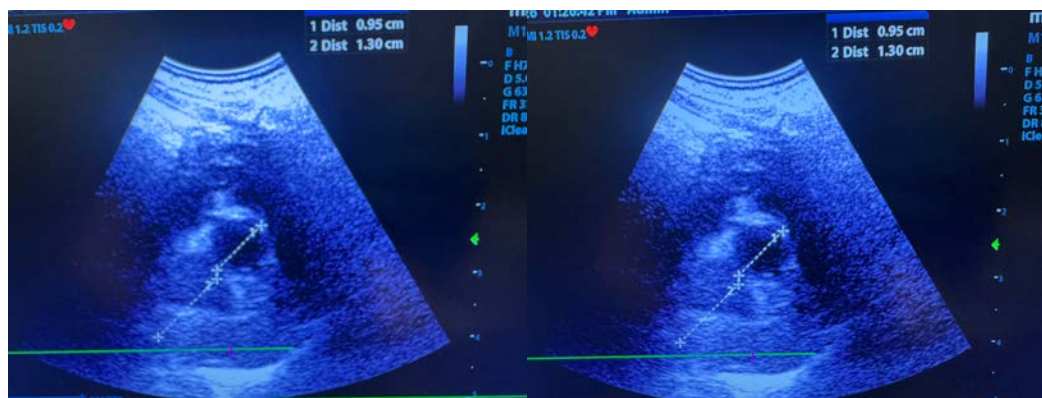
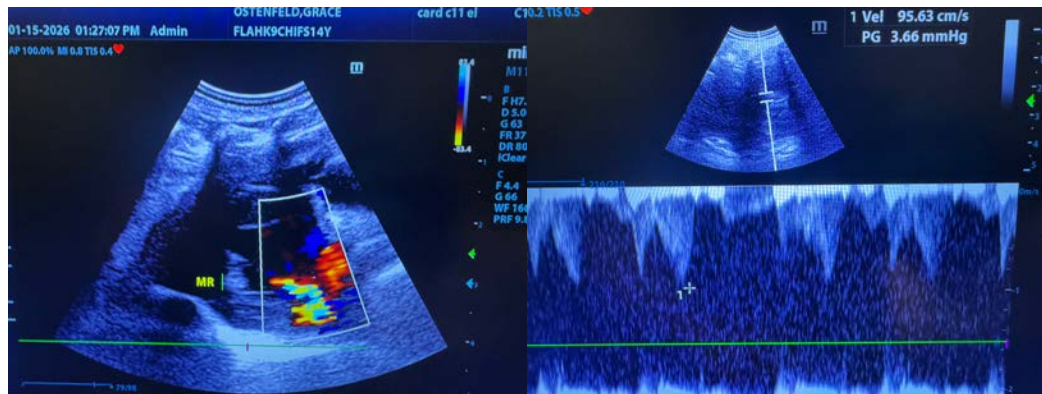
Dr. Greenhut

INVOICE

72232

DATE

1/15/26





PATIENT

Grace Ostenfeld

SPECIES

Canine

BREED

Chihuahua

SEX

Spayed Female

AGE

14 Years

WEIGHT

5 lbs

INTERPRETED BY

Eric Lindquist, DMV,
 DABVP (CFM), Cert.
 IVUSS

IMAGING PERFORMED BY

Eric Lindquist, DMV,
 DABVP (CFM), Cert.
 IVUSS

HOSPITAL NAME

Franklin Lakes Animal
 Hospital

REFERRING VET

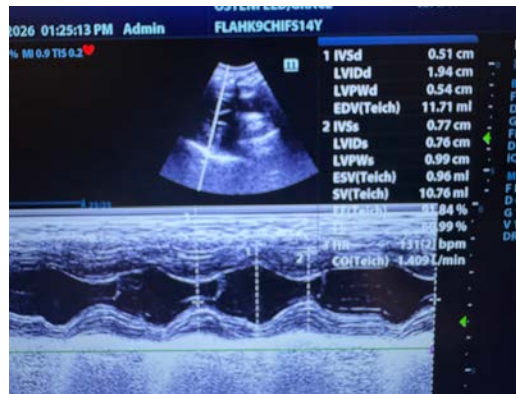
Dr. Greenhut

INVOICE

72232

DATE

1/15/26



The information and recommendations provided are based on the images presented by the referring veterinarian/sonographer. No evaluation can be communicated regarding pathology that was not visible in the image/video clips provided.

Thank you for this referral. If the clinical or image interpretation does not parallel your findings or if I can be of any further assistance please contact me.

Eric Lindquist, DMV, DABVP(CFM), Cert. IVUSS,
 CEO, Owner, Founder -- SonoPath.com
info@SonoPath.com