



PATIENT

BigBoy Martin

SPECIES

Feline

BREED

Domestic Shorthair

SEX

Neutered Male

AGE

14 Years

WEIGHT

20 lbs

INTERPRETED BY

Eric Lindquist, DMV,
DABVP (CFM), Cert.
IVUSS

IMAGING PERFORMED BY

Dr. Ken Leal

HOSPITAL NAME

Animal Hospital of
Roxbury

REFERRING VET

Dr. Elia

INVOICE

72262

DATE

1/15/26

PRESENTING CLINICAL SIGNS

Pro BNP snap abnormal Heart enlargement on x-ray Medications: Methimazole
Abnormal PE/Chem/CBC/UA Results: Hyperthyroid

ULTRASONOGRAPHIC EXAMINATION OF THE HEART

FELINE CARDIAC PARAMETERS	BODY WEIGHT (lbs)	HR (BPM)	IVSd (cm)	LVIDd (cm)	LVWd (cm)	FS (%)	EF (%)
NORMAL PARAMETER	-----	150-240	0.3-0.6	1.0-2.1	0.25-0.6	35-67	80-100
PATIENT	20	220	0.51	1.87	0.62	43	77
FELINE CARDIAC PARAMETERS	LA/AO (M-mode)	LA/AO HEART BASE (Sisson)	LAD LA MAX 4 Chamber		LVOT VEL. (m/s)	RVOT VEL. (m/s)	IVRT (m)
NORMAL PARAMETER	<1.5	1.6	0.7-1.7		<1.6	<1.3	40-60
PATIENT	1.9	1.9	--		--	1.24	NM

Adapted from June Boon, Veterinary Echocardiography, 1998
Sisson D et al. JVIM 1991; 5: 232, Jacobs et al. Am J Vet Res 1985; 46:1705

E-wave velocity = 1.3

Cardiac Presentation

The cardiac presentation presented fairly normal septal and free wall thicknesses with mild septal hypertrophy. Mitral insufficiency noted at > 5.0 m/sec, with volume overload of the left and right atria. Tricuspid insufficiency also noted. Slight pericardial effusion noted. Mild "smoke" noted in the left atrium without overt clot formation. Contractility appeared adequate.

ULTRASONOGRAPHIC FINDINGS

- Unclassified cardiomyopathy with left and right-sided volume overload, emerging cardiac failure – Myocarditis should be considered a potential in this patient.

INTERPRETATION OF THE FINDINGS & FURTHER RECOMMENDATIONS

Recommend initiating Pimobendan at 0.3 mg/kg BID, ACE inhibitor 0.5 mg/kg SID, and Lasix at 0.625 mg BID. Plavix therapy also indicated. Recheck echo in one month, earlier if clinical signs persist. BUN, creatinine, blood pressures, body temperature should all be monitored carefully, as well as basal respiratory rate.



PATIENT

BigBoy Martin

SPECIES

Feline

BREED

Domestic Shorthair

SEX

Neutered Male

AGE

14 Years

WEIGHT

20 lbs

INTERPRETED BY

Eric Lindquist, DMV,
 DABVP (CFM), Cert.
 IVUSS

IMAGING PERFORMED BY

Dr. Ken Leal

HOSPITAL NAME

Animal Hospital of
 Roxbury

REFERRING VET

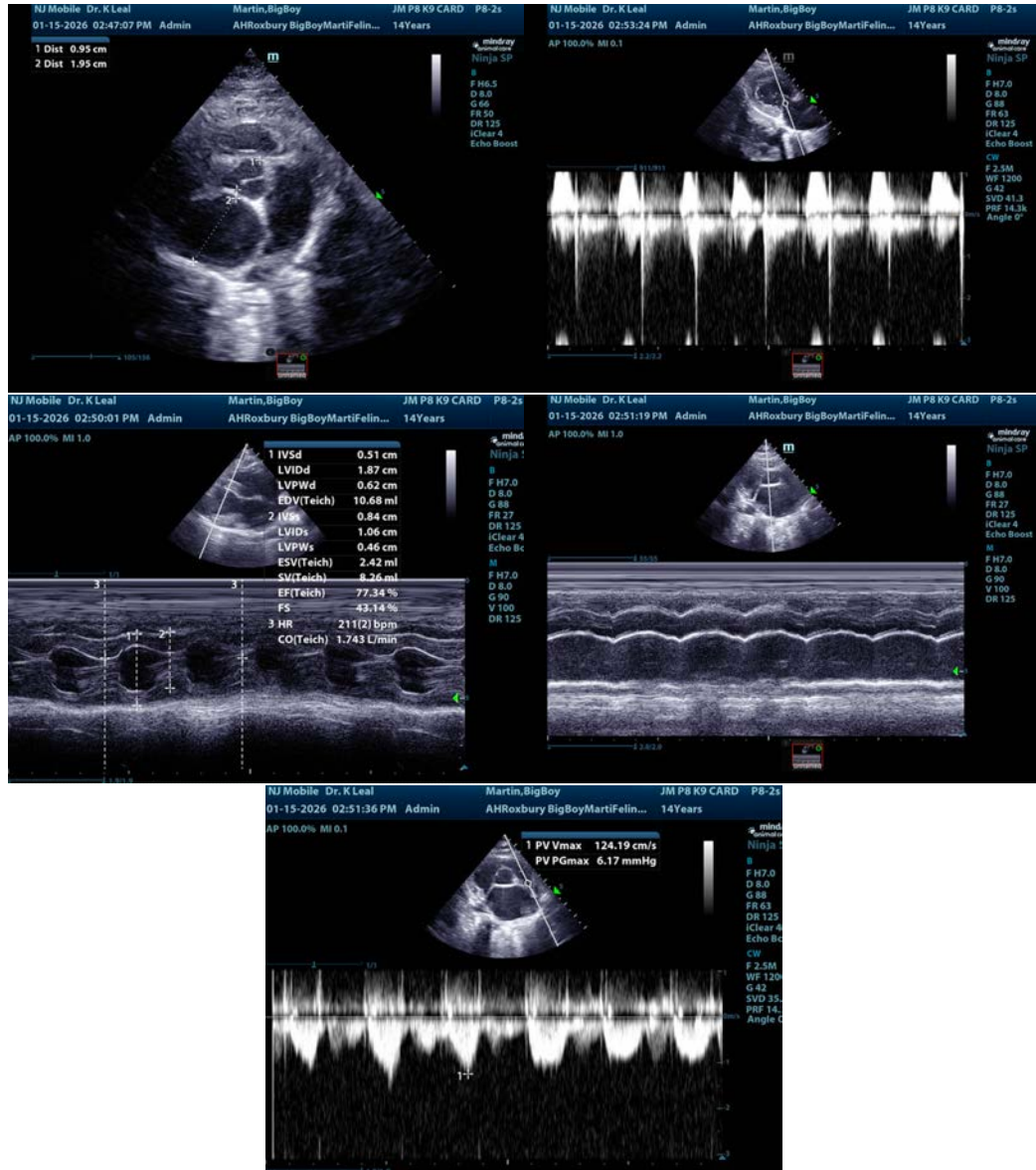
Dr. Elia

INVOICE

72262

DATE

1/15/26



The information and recommendations provided are based on the images presented by the referring veterinarian/sonographer. No evaluation can be communicated regarding pathology that was not visible in the image/video clips provided.

Thank you for this referral. If the clinical or image interpretation does not parallel your findings or if I can be of any further assistance please contact me.

Eric Lindquist, DMV, DABVP(CFM), Cert. IVUSS,
 CEO, Owner, Founder -- SonoPath.com
info@SonoPath.com