



**PATIENT**

Bentley McFalls

**SPECIES**

Canine

**BREED**

Shih-Poo

**SEX**

Neutered Male

**AGE**

14 Years

**WEIGHT**

11.7 lbs

**PRESENTING CLINICAL SIGNS**

Follow up echo. Diagnosed with stable B1 valvular disease. Grade 4/6 systolic murmur.

**ULTRASONOGRAPHIC EXAMINATION OF THE HEART**

CANINE CARDIAC PARAMETERS	MR VMAX (m/s)	TR VMAX (m/s)	LA/AO (M-Mode)	LA/AO (Heart Base; Swe)	FS (%)	EF (%)	EPSS (cm)
NORMAL PARAMETER	4.5-5.5	<2.7	1.3	Up to 1.6	28-40	40-100	<0.6
PATIENT	6.8	--	1.1	1.2	54	86	0.1
CANINE CARDIAC PARAMETERS	HR (BPM)	AV VMAX (m/s)	PV MAX (m/s)	BODY WEIGHT (lbs)	LAD LA MAX 4 Chamber	LVIDd Avg; 2D and m-mode short axis (cm)	LVIDs Avg; 2D and m-mode short axis (cm)
NORMAL PARAMETER	50-100	0.7-1.7	0.7-1.6				
PATIENT	179	1.37	0.99	11.7	2.7	2.53	--

**INTERPRETED BY**

Eric Lindquist, DMV, DABVP (CFM), Cert. IVUSS

**IMAGING PERFORMED BY**

Eric Lindquist, DMV, DABVP (CFM), Cert. IVUSS

**HOSPITAL NAME**

Franklin Lakes Animal Hospital

**REFERRING VET**

Dr. Onesios

**INVOICE**

72233

**DATE**

1/15/26

**Cardiac Presentation**

The echocardiogram in this patient demonstrated normal **left atrial** size based on 3 different LA measurement methods. Chamber volumes and echogenicity were normal. The cranial and caudal **mitral** valve leaflets presented vegetative thickening consistent with endocardiosis. Doppler indicated measurable insufficiency. Slight prolapse of the anterior mitral valve leaflet noted. The **left ventricle** presented thicknesses with linear contour and was not dilated nor restricted. The **myocardium** presented normal echogenicity without subjective evidence of significant fibrotic or ischemic disease. **Contractility** of the ventricular walls was adequate and in normal range for this patient evidenced by the fractional shortening measurement and subjective evaluation of the different regions of the myocardium. The **left ventricular outflow** tract demonstrated normal laminar flow and subjective structural integrity. The **right atrium** and auricle revealed normal size, structure and content. No evidence of masses was noted or chamber overload. **Tricuspid** valvular assessment demonstrated adequate linear morphology. The **right ventricle** was of normal size (1/3 diameter of LV), chordae structure, myocardial echogenicity and thickness. **Pulmonic** tract assessment revealed normal valve structure, laminar flow, and diameter (approx. 1:1 pa/ao ratio). No visible **pericardial** or free pleura fluid was noted. No echographically detectable evidence of infiltrative disease was visible. The cranial **mediastinum** and **pericardial** regions were free of masses in the visible window.

**ULTRASONOGRAPHIC FINDINGS**

- Stage B1 valvular disease, no evidence of volume overload.

**INTERPRETATION OF THE FINDINGS & FURTHER RECOMMENDATIONS**

The heart is stable without clinical disease. No overt contraindication for anesthesia of brief to moderate duration. I suggest Torbutrol premed, Propofol induction, Isoflo maintenance or similar



**PATIENT**

Bentley McFalls

**SPECIES**

Canine

**BREED**

Shih-Poo

**SEX**

Neutered Male

**AGE**

14 Years

**WEIGHT**

11.7 lbs

**INTERPRETED BY**

Eric Lindquist, DMV,  
DABVP (CFM), Cert.  
IVUSS

**IMAGING PERFORMED BY**

Eric Lindquist, DMV,  
DABVP (CFM), Cert.  
IVUSS

**HOSPITAL NAME**

Franklin Lakes Animal  
Hospital

**REFERRING VET**

Dr. Onesios

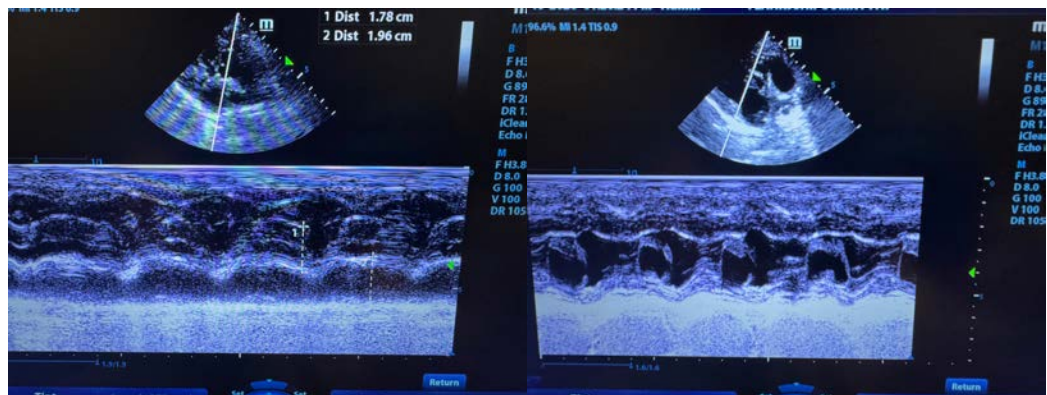
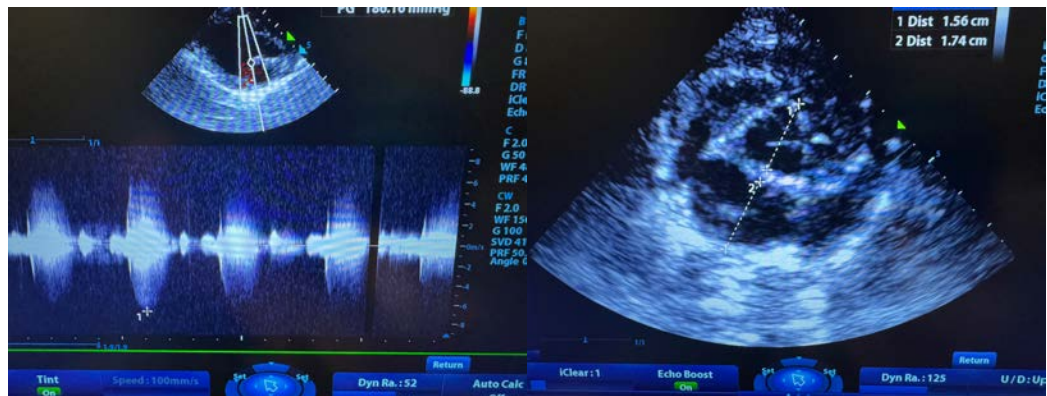
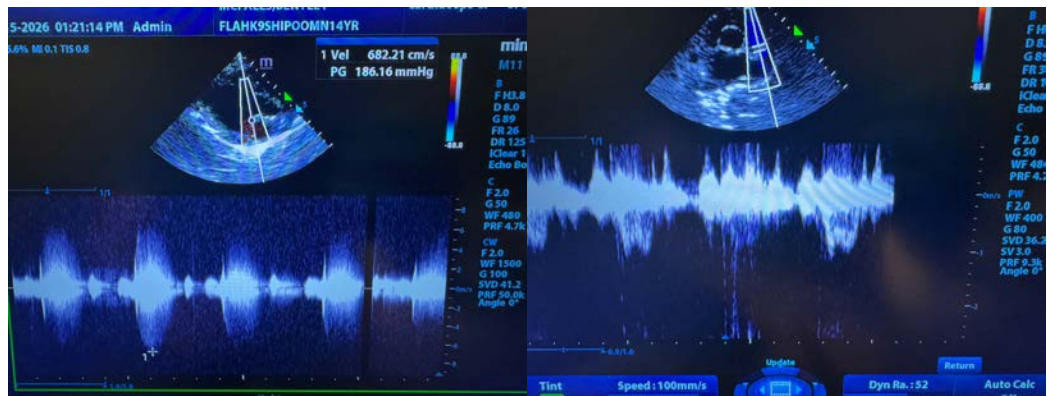
**INVOICE**

72233

**DATE**

1/15/26

protocol if anesthesia is desired. Blood pressure, EKG and chest radiographs are recommended if not already performed. Target white coat negative systolic pressure of < 160 mmHg. If higher than this ACE-inhibitor is suggested to reach this level. Recheck echocardiogram is recommended in 6 months, earlier if murmur grade increases or clinical signs initiate.





**PATIENT**

Bentley McFalls

**SPECIES**

Canine

**BREED**

Shih-Poo

**SEX**

Neutered Male

**AGE**

14 Years

**WEIGHT**

11.7 lbs

**INTERPRETED BY**

Eric Lindquist, DMV,  
 DABVP (CFM), Cert.  
 IVUSS

**IMAGING PERFORMED BY**

Eric Lindquist, DMV,  
 DABVP (CFM), Cert.  
 IVUSS

**HOSPITAL NAME**

Franklin Lakes Animal  
 Hospital

**REFERRING VET**

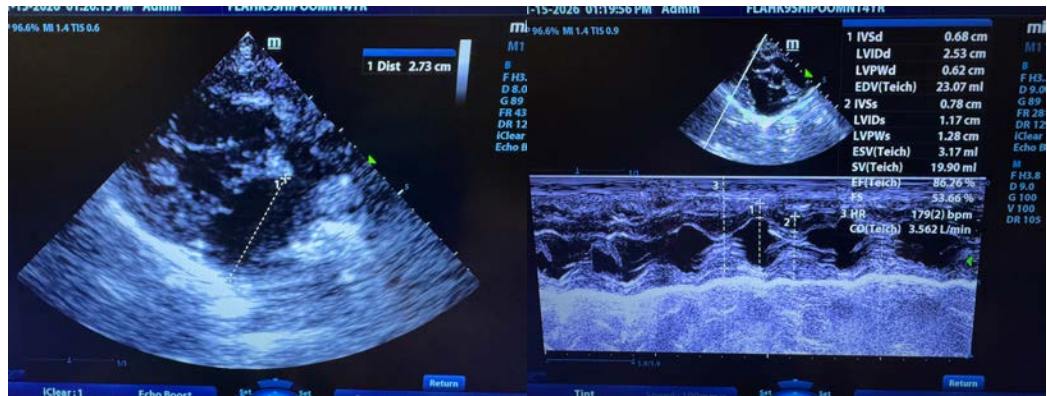
Dr. Onesios

**INVOICE**

72233

**DATE**

1/15/26



The information and recommendations provided are based on the images presented by the referring veterinarian/sonographer. No evaluation can be communicated regarding pathology that was not visible in the image/video clips provided.

Thank you for this referral. If the clinical or image interpretation does not parallel your findings or if I can be of any further assistance please contact me.

**Eric Lindquist, DMV, DABVP(CFM), Cert. IVUSS,**  
 CEO, Owner, Founder -- SonoPath.com  
[info@SonoPath.com](mailto:info@SonoPath.com)