



## PATIENT

Predita Shymanski

## SPECIES

Canine

## BREED

Mix

## SEX

Spayed female

## AGE

1 ½ years

## WEIGHT

35 lbs

## INTERPRETED BY

Eric Lindquist, DMV  
DABVP, Cert. IVUSS

## IMAGING PERFORMED BY

Dr. Christensen

## HOSPITAL NAME

Tranquility VC

## REFERRING VET

Dr. Christensen

## INVOICE

70088

## DATE

1/14/26

## PRESENTING CLINICAL SIGNS

History: Intermittent vomiting for past few days. Owner did not fast dog last night. Kept down meal last night.

Abnormal PE/Chem/CBC/UA Results: Elevated eosinophils on CBC.

## ULTRASONOGRAPHIC EXAMINATION OF THE ABDOMEN

### Urinary System

The **urinary bladder**, trigone, and pelvic urethra presented normal thicknesses and normal tone. The ureters were not visible which is normal. No uroliths or sediment were visualized and anechoic urine was present. No evidence of inflammatory or neoplastic changes was noted. Ureteral papillae were normal.

The **kidneys** revealed normal size and structure, corticomedullary definition and ratio for this age. The cortices presented largely uniform texture with normal echogenic relationship to liver and spleen. Medullary structure differed distinctly from the cortex and no evidence of pelvic dilation was present. The capsules were acceptably uniform without significant irregularities. The right kidney measured 5.47 cm. The left kidney measured 5.3 cm.

### Adrenal Glands

Both **adrenal glands** were visualized and recognized as having normal shape, size, position and echogenicity for this breed. The phrenic vasculature, glandular echogenicity and detail were unremarkable. Capsule, cortex, and medullary definition were normal for this age patient. The left adrenal gland measured 1.92 x 0.34 cm at the caudal pole and 0.47 cm at the cranial pole. The right adrenal gland measured 2.42 x 0.46 cm at the cranial pole and 0.45 cm at the caudal pole.

### Spleen

The **spleen** presented a smooth homogeneous parenchyma hyperechoic to liver and renal cortical parenchyma. The capsule was smooth without noticeable expansion or deviation from within the spleen or adjacent pathology. The splenic vasculature demonstrated normal volume without signs of congestion or thrombosis. No sonographic evidence of acute or chronic inflammatory, neoplastic, or infarctual changes was noted.

### Liver

The **liver** images submitted revealed subjectively normal liver size, contour, and structure. Parenchymal echogenicity was naturally coarse and hypoechoic to the spleen. Vascular and biliary tracts were of normal volume with no evidence of congestion. The gallbladder presented acceptably thin walls with primarily anechoic content. The cystic and common bile ducts were normal. No pathological hepatic lymphadenopathy was evident. No overt structural evidence of inflammatory, infiltrative or regenerative pathology was evident.



**PATIENT**

Predita Shymanski

**SPECIES**

Canine

**BREED**

Mix

**SEX**

Spayed female

**AGE**

1 ½ years

**WEIGHT**

35 lbs

**INTERPRETED BY**

Eric Lindquist, DMV  
DABVP, Cert. IVUSS

**IMAGING PERFORMED BY**

Dr. Christensen

**HOSPITAL NAME**

Tranquility VC

**REFERRING VET**

Dr. Christensen

**INVOICE**

70088

**DATE**

1/14/26

**Gastrointestinal**

The **stomach** was filled with progressively shadowing luminal material. Much of the small intestine was empty, however, portions were dilated with similar echotexture material. The colon was unremarkable.

**Pancreas**

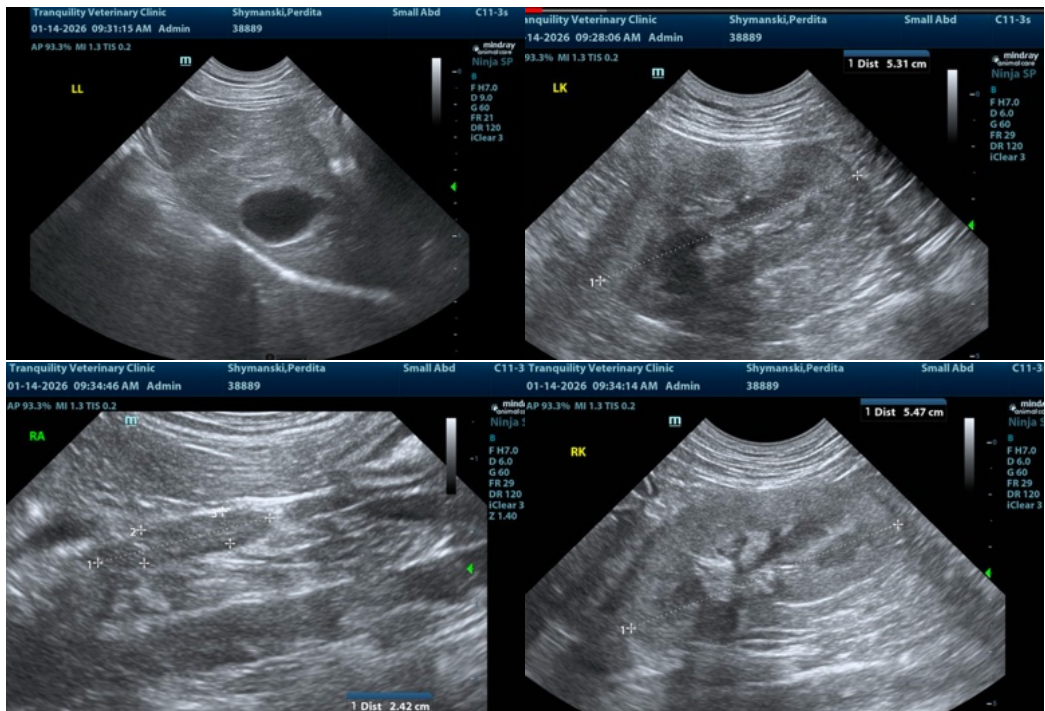
The base and limbs of the **pancreas** were observed to be largely isoechoic to surrounding omental fat. Pancreatic duct and capsular contour were acceptably normal and parenchyma respected normal curvilinear patterns. No overt evidence of active inflammatory or neoplastic disease was noted.

**ULTRASONOGRAPHIC FINDINGS**

Full stomach of progressively shadowing material.

**INTERPRETATION OF THE FINDINGS & FURTHER RECOMMENDATIONS**

If the patient was n.p.o. at the time of the sonogram then gastrotomy +/- enterotomy is indicated.





## PATIENT

Predita Shymanski

## SPECIES

Canine

## BREED

Mix

## SEX

Spayed female

## AGE

1 ½ years

## WEIGHT

35 lbs

## INTERPRETED BY

Eric Lindquist, DMV  
DABVP, Cert. IVUSS

## IMAGING PERFORMED BY

Dr. Christensen

## HOSPITAL NAME

Tranquility VC

## REFERRING VET

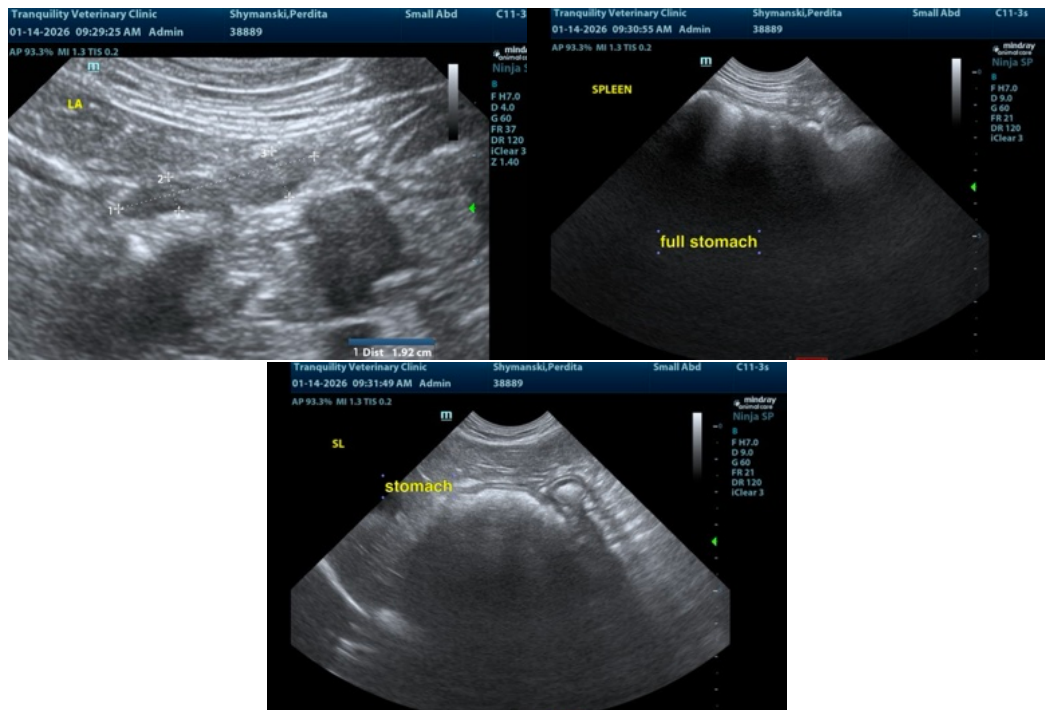
Dr. Christensen

## INVOICE

70088

## DATE

1/14/26



The information and recommendations provided are based on the images presented by the referring veterinarian/sonographer. No evaluation can be communicated regarding pathology that was not visible in the image/video clips provided.

Thank you for this referral. If the clinical or image interpretation does not parallel your findings or if I can be of any further assistance please contact me.

Eric Lindquist, DMV, DABVP (CFM), Cert. IVUSS, CEO of SonoPath.com

[info@SonoPath.com](mailto:info@SonoPath.com)