



PATIENT

Midnight Westling

SPECIES

Canine

BREED

Pomeranian

SEX

Male

AGE

12 years

WEIGHT

18.2 lbs

INTERPRETED BY

Eric Lindquist, DMV
DABVP, Cert. IVUS

IMAGING PERFORMED BY

Jenn

HOSPITAL NAME

Rockaway AH

REFERRING VET

Dr. Salazar

INVOICE

70105

DATE

1/14/26

PRESENTING CLINICAL SIGNS

History: History of heart dz Increased coughing since Dec Was at boarding facility, possibly kennel cough was put om Doxy and Cerenia on 1/7 Owner reports cough is finally starting to subside. Had last cardiac u/s 3/4/25 Current meds Vetmedin 5mg 1/2 SID Spironolactone 25mg 1/2 SID Lasix 12.5mg 1/4 BID Enalapril 2.5mg 1 SID

ULTRASONOGRAPHIC EXAMINATION OF THE HEART

The echocardiogram in this patient presented minor volume overload of the left atrium and left ventricle. However, contractility appeared adequate. Mitral valve insufficiency was severe with complete filling of the left atrium. Tricuspid insufficiency was minor. Occasional arrhythmogenic activity was noted. Minor aortic insufficiency was noted. There was no pericardial or pleural effusion was noted.

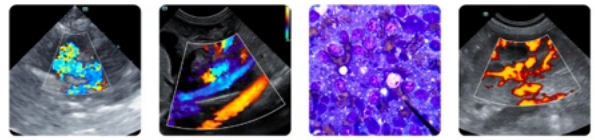
CANINE CARDIAC PARAMETERS	MR VMAX (m/s)	TR VMAX (m/s)	LA/AO	LA/AO (Heart Base)	FS (%)	EF (%)	EPSS (cm)
NORMAL PARAMETER	4.5-5.5	<2.7	1.3	<1.6	28-40	40-100	<0.6
PATIENT	6.0	2.0	1.4	1.77	42	74	NM
CANINE CARDIAC PARAMETERS	HR (BPM)	AV VMAX (m/s)	PV MAX (m/s)	BODY WEIGHT	LA 2D short axis Base view (cm)	LVIDd Avg; 2D and m-mode short axis (cm)	LVIDs Avg; 2D and m-mode short axis (cm)
NORMAL PARAMETER	50-100	0.7-1.7	0.7-1.6	BELOW	BELOW	BELOW	BELOW
PATIENT	80	-	0.7	18.2 lbs	3.35	3.3	-

ULTRASONOGRAPHIC FINDINGS

- Fairly stable valvular disease under current protocol.

INTERPRETATION OF THE FINDINGS & FURTHER RECOMMENDATIONS

Primary respiratory protocol is warranted. Slight increase in Lasix could be justified. A recheck echocardiogram is recommended in 6 months or earlier if clinical signs persist.



PATIENT

Midnight Westling

SPECIES

Canine

BREED

Pomeranian

SEX

Male

AGE

12 years

WEIGHT

18.2 lbs

INTERPRETED BY

Eric Lindquist, DMV
DABVP, Cert. IVUS

IMAGING PERFORMED BY

Jenn

HOSPITAL NAME

Rockaway AH

REFERRING VET

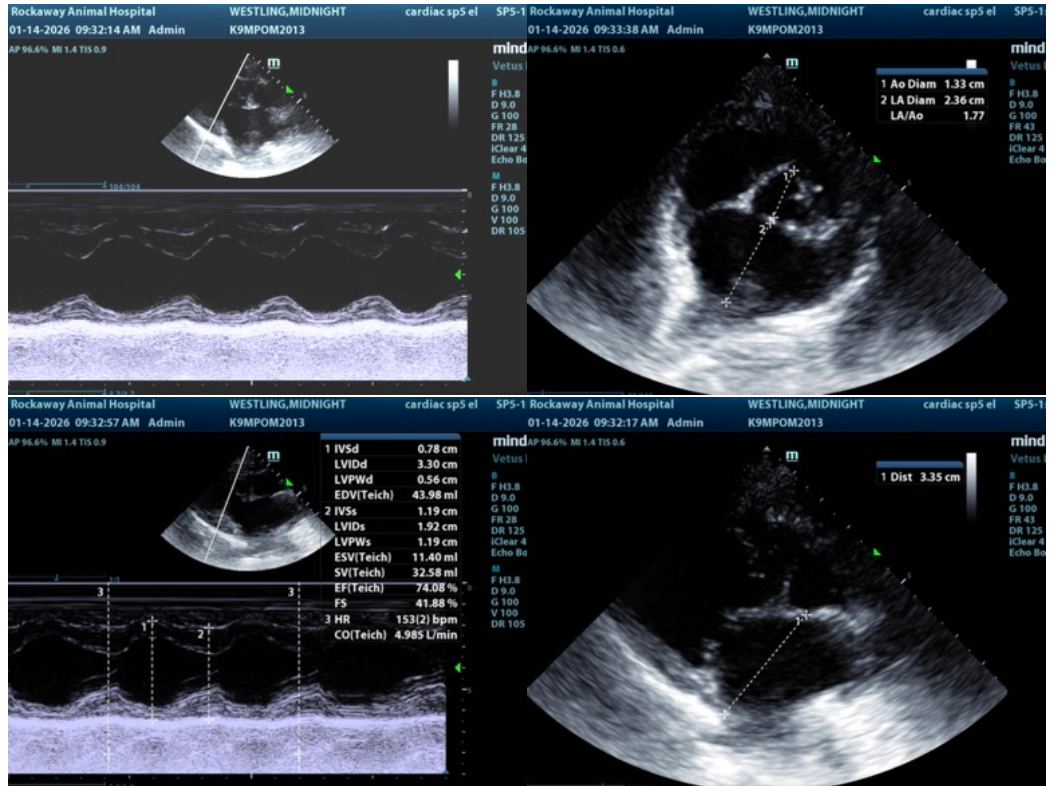
Dr. Salazar

INVOICE

70105

DATE

1/14/26





PATIENT

Midnight Westling

SPECIES

Canine

BREED

Pomeranian

SEX

Male

AGE

12 years

WEIGHT

18.2 lbs

INTERPRETED BY

Eric Lindquist, DMV
DABVP, Cert. IVUSS

IMAGING PERFORMED BY

Jenn

HOSPITAL NAME

Rockaway AH

REFERRING VET

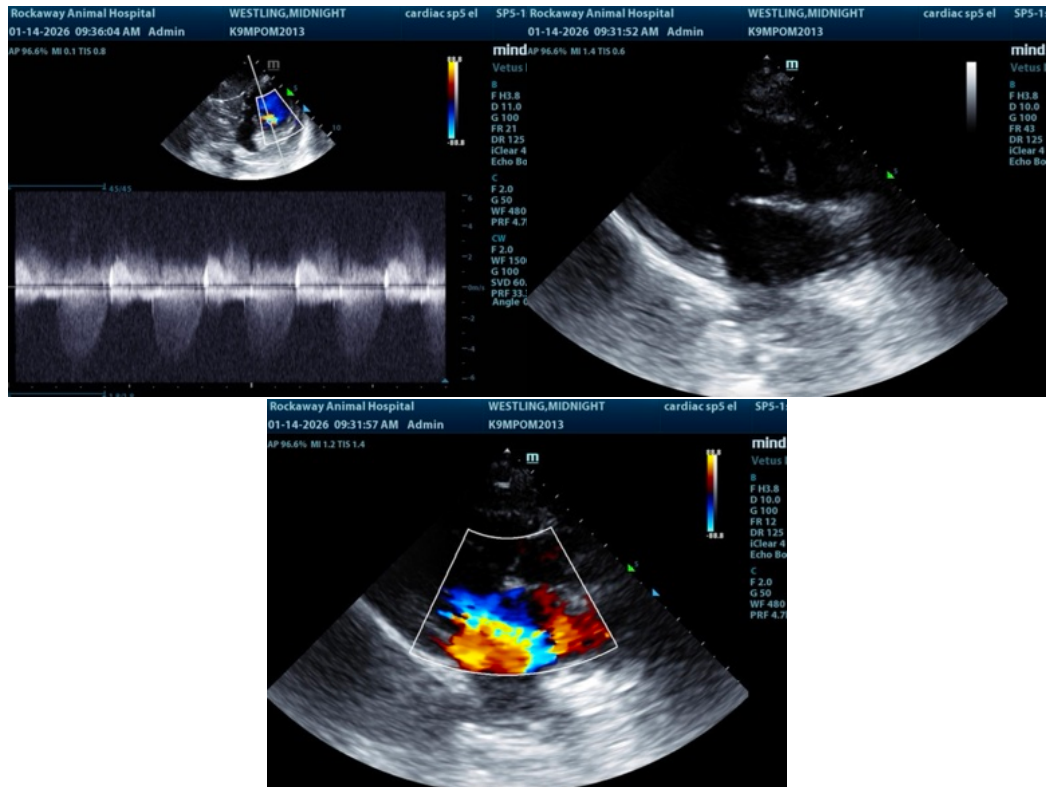
Dr. Salazar

INVOICE

70105

DATE

1/14/26



The information and recommendations provided are based on the images presented by the referring veterinarian/sonographer. No evaluation can be communicated regarding pathology that was not visible in the image/video clips provided.

Thank you for this referral. If the clinical or image interpretation does not parallel your findings or if I can be of any further assistance please contact me.

Eric Lindquist, DMV, DABVP, Cert. IVUSS, CEO of SonoPath.com

info@SonoPath.com