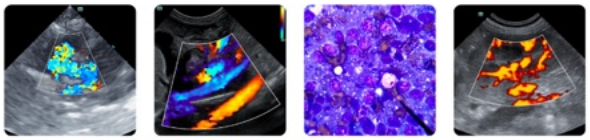



**PATIENT**
Daisy Gregory

**SPECIES**
Canine

**BREED**
Beagle Mix

**SEX**
Spayed female

**AGE**
13 years

**WEIGHT**
15.2 lbs

**INTERPRETED BY**
Eric Lindquist, DMV
DABVP, Cert. IVUSS

**IMAGING PERFORMED BY**
JK

**HOSPITAL NAME**
Hamburg VC

**REFERRING VET**
Dr. Martens

**INVOICE**
70109

**DATE**
1/14/26

## PRESENTING CLINICAL SIGNS

History: Grade 3/5 murmur, a symptomatic
Abnormal PE/Chem/CBC/UA Results: BP 114/84(89), 133/73(93)

## ULTRASONOGRAPHIC EXAMINATION OF THE HEART

The echocardiogram in this patient demonstrated normal **left atrial** size based on 3 different LA measurement methods. Chamber volumes and echogenicity were normal. The cranial and caudal **mitral** valve leaflets presented vegetative thickening consistent with endocardiosis. Doppler indicated measurable insufficiency. The **left ventricle** presented thicknesses with linear contour and was not dilated nor restricted. The **myocardium** presented normal echogenicity without subjective evidence of significant fibrotic or ischemic disease. **Contractility** of the ventricular walls was adequate and in normal range for this patient evidenced by the fractional shortening measurement and subjective evaluation of the different regions of the myocardium. The **left ventricular outflow** tract demonstrated normal laminar flow and subjective structural integrity. The **right atrium** and auricle revealed normal size, structure and content. No evidence of masses was noted or chamber overload. **Tricuspid** valvular assessment demonstrated adequate linear morphology. The **right ventricle** was of normal size (1/3 diameter of LV), chordae structure, myocardial echogenicity and thickness. **Pulmonic** tract assessment revealed normal valve structure, laminar flow, and diameter (approx.1:1 pa/ao ratio). No visible **pericardial** or free pleura fluid was noted. No echographically detectable evidence of infiltrative disease was visible. The cranial **mediastinum and pericardial regions** were free of masses in the visible window.

| CANINE CARDIAC PARAMETERS | MR VMAX (m/s) | TR VMAX (m/s) | LA/AO | LA/AO (Heart Base) | FS (%) | EF (%) | EPSS (cm) |
|---|---|---|---|---|---|---|---|
| NORMAL PARAMETER | 4.5-5.5 | <2.7 | 1.3 | <1.6 | 28-40 | 40-100 | <0.6 |
| PATIENT | 5.5 | 2.8 | NM | 1.5 | 51 | 83 | 0.4 |
| **CANINE CARDIAC PARAMETERS** | **HR** (BPM) | **AV VMAX** (m/s) | **PV MAX** (m/s) | **BODY WEIGHT** | **LA** 2D short axis Base view (cm) | **LVIDd** Avg; 2D and m-mode short axis (cm) | **LVIDs** Avg; 2D and m-mode short axis (cm) |
| NORMAL PARAMETER | 50-100 | 0.7-1.7 | 0.7-1.6 | BELOW | BELOW | BELOW | BELOW |
| PATIENT | 80 | 1.4 | 1.07 | 15.2 lbs | 2.7 | 2.75 | |

## ULTRASONOGRAPHIC FINDINGS

Stage B1 valvular disease.

**PATIENT**

Daisy Gregory

**SPECIES**

Canine

**BREED**

Beagle Mix

**SEX**

Spayed female

**AGE**

13 years

**WEIGHT**

15.2 lbs

**INTERPRETED BY**

Eric Lindquist, DMV
DABVP, Cert. IVUSS

**IMAGING PERFORMED BY**

JK

**HOSPITAL NAME**

Hamburg VC

**REFERRING VET**

Dr. Martens

**INVOICE**

70109

**DATE**

1/14/26

## INTERPRETATION OF THE FINDINGS & FURTHER RECOMMENDATIONS

The heart is stable without clinical disease. No overt contraindication for anesthesia of brief to moderate duration. I suggest Torbutrol premed, Propofol induction, Isoflo maintenance or similar protocol if anesthesia is desired. Blood pressure recommended if not already performed and target white coat negative systolic pressure of < 160 mmHg. If higher than this ACE-inhibitor is suggested to reach this level. Recheck echocardiogram is recommended in 6 months, earlier if murmur grade increases or clinical signs initiate.

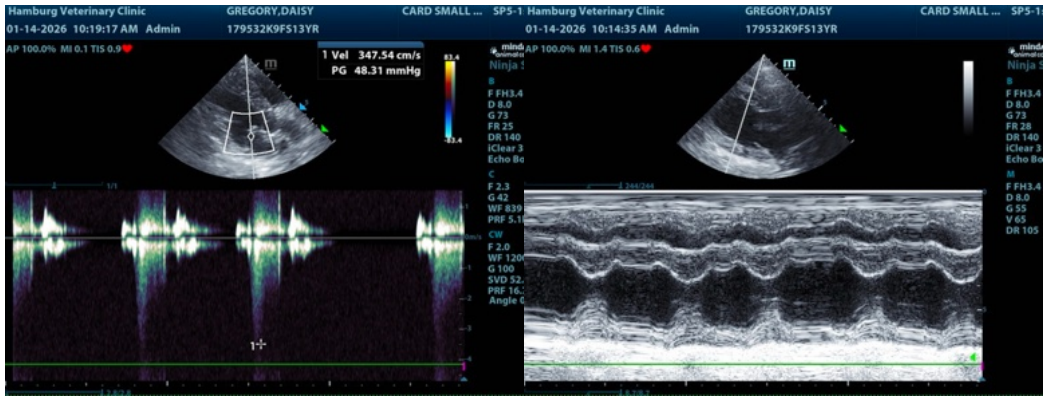


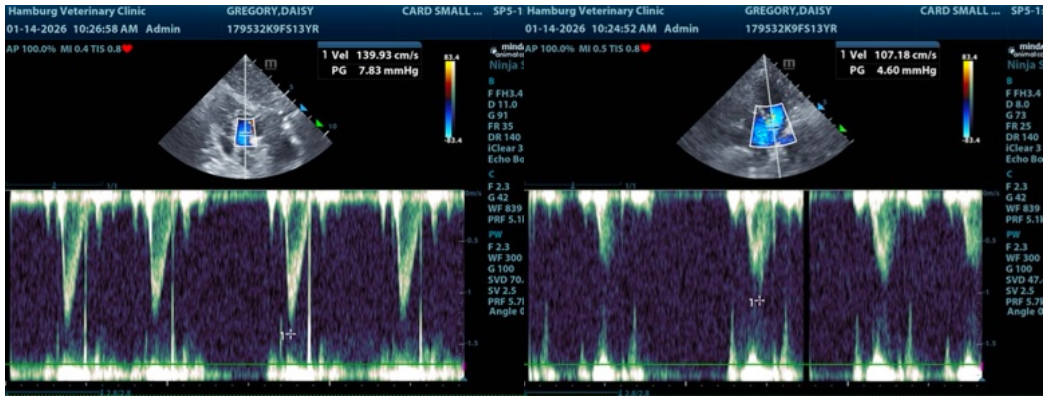


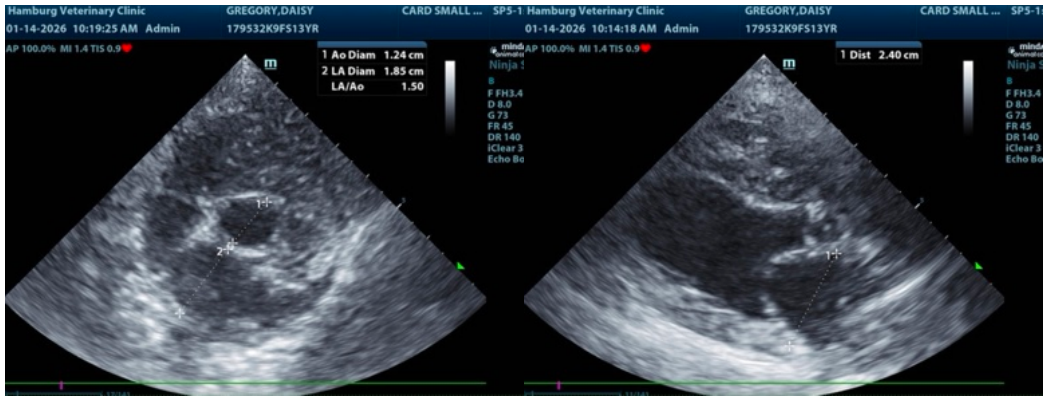

# SonoPath

FOSTERING THE ART OF VETERINARY MEDICINE™

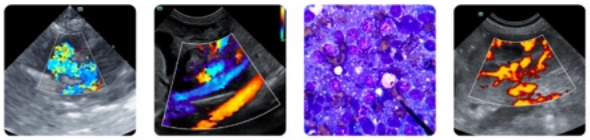

*Clinical Sonography & Telecytology*

*Educational Teleconsultation Services™*

SonoPath.com info@sonopath.com 1.800.838.4268

**PATIENT**

Daisy Gregory

**SPECIES**

Canine

**BREED**

Beagle Mix

**SEX**

Spayed female

**AGE**

13 years

**WEIGHT**

15.2 lbs

**INTERPRETED BY**

Eric Lindquist, DMV
DABVP, Cert. IVUSS

**IMAGING PERFORMED BY**

JK

**HOSPITAL NAME**

Hamburg VC

**REFERRING VET**

Dr. Martens

**INVOICE**

70109

**DATE**

1/14/26

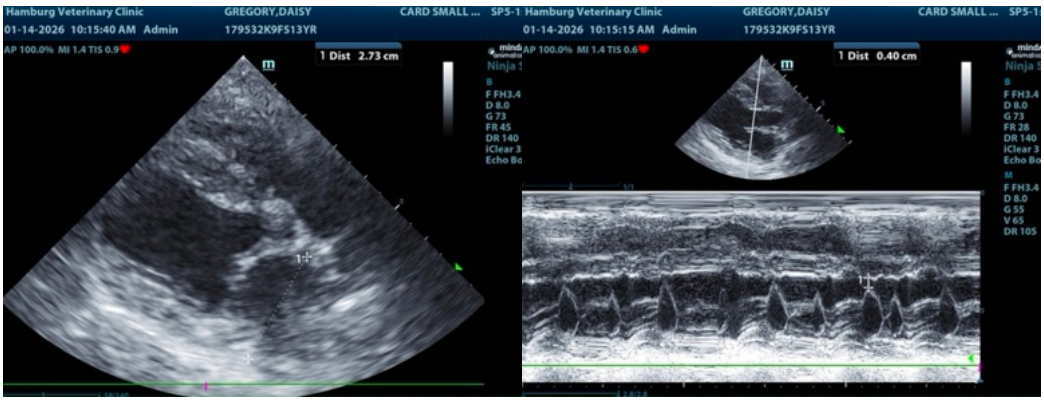


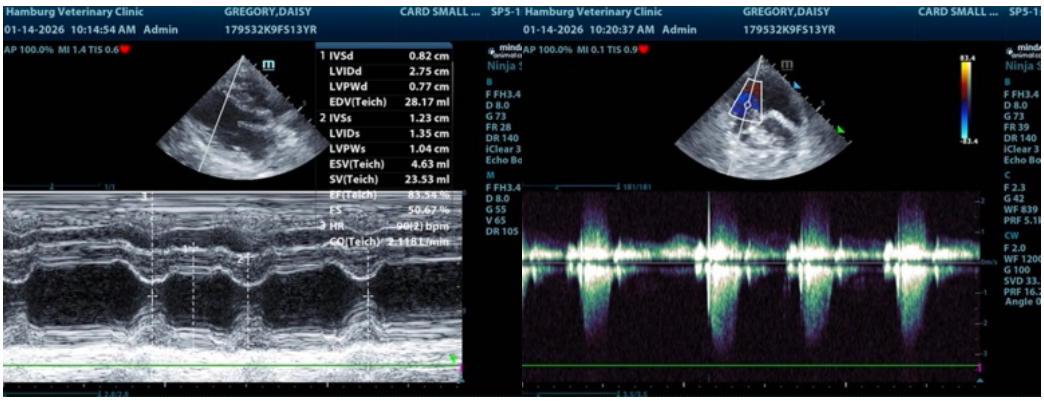


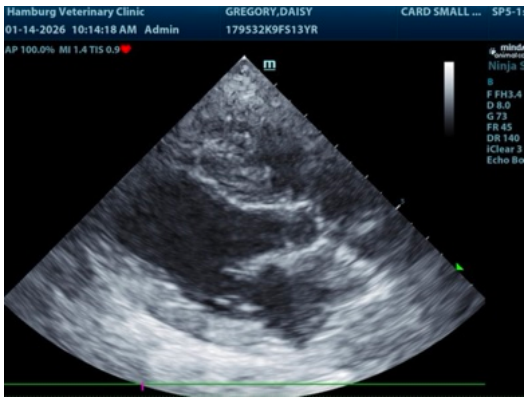


**The information and recommendations provided are based on the images presented by the referring veterinarian/sonographer. No evaluation can be communicated regarding pathology that was not visible in the image/video clips provided.**

Thank you for this referral. If the clinical or image interpretation does not parallel your findings or if I can be of any further assistance please contact me.

Eric Lindquist, DMV, DABVP (CFM), Cert. IVUSS, CEO of SonoPath.com

info@SonoPath.com