

PATIENT

Baron Sloan

SPECIES

Canine

BREED

Doberman

SEX

Male

AGE

5 Years

WEIGHT

80.7 lbs

INTERPRETED BY

Eric Lindquist, DMV,
DABVP (CFM), Cert.
IVUSS

**IMAGING
PERFORMED BY**

Greg Shaffer

HOSPITAL NAME

Pawley's Veterinary
Hospital

REFERRING VET

Dr. Kiningham

INVOICE

72210

DATE

1/14/26

PRESENTING CLINICAL SIGNS

Chronic hematuria/pyuria, seems to have resolved.

ULTRASONOGRAPHIC EXAMINATION OF THE ABDOMEN

Urinary System

The **urinary bladder**, trigone, and pelvic urethra presented normal thicknesses and normal tone. The ureters were not visible which is normal. No uroliths or sediment were visualized and anechoic urine was present. No evidence of inflammatory or neoplastic changes were noted. Ureteral papillae were normal.

The **prostate** was uniformly enlarged (5.4 cm in width) with lobar swelling appeared to impinge upon the urethra and mildly deviate the descending colon. The prostatic tissue was hyperechoic containing focal areas of decreased echogenicity. These changes are suggestive of either chronic inflammatory episodes, benign cystic pathology or both. Underlying neoplasia cannot be completely ruled-out but is lower on the differential list. Anechoic cysts or abscesses were noted at the caudal aspects of both the left and right lobes. Left lobe cyst/abscess measured 2.2 cm x 1.5 cm, right lobe cyst/abscess measured 1.6 cm. Edema lines noted in the prostate otherwise, consistent with prostatitis, BPH, and potential abscessation.

The **kidneys** revealed largely normal size and structure, corticomedullary definition and ratio (cortex 1/3 of medulla) were essentially maintained with some age-related loss of curvilinear patterns regarding the capsule and C/M junction. The cortices presented largely uniform texture with some increased echogenicity expected for his age patient. Medullary structure differed distinctly from that of the cortex and no evidence of pelvic dilation was present. Left kidney measured 8.24 cm. Right kidney measured 8.5 cm.

Adrenal Glands

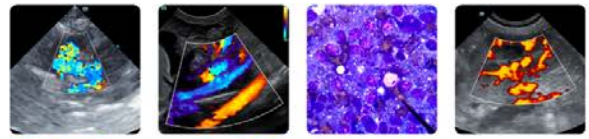
Both **adrenal glands** were visualized and recognized as having normal shape, size, position and echogenicity for this breed. The phrenic vasculature, glandular echogenicity and detail were unremarkable. Capsule, cortex, and medullary definition were normal for this age patient. Left measured 2.19 cm x 0.43 cm at the caudal pole and 0.33 cm at the cranial pole. Right measured 2.67 cm x 0.85 cm at the cranial pole and 0.69 cm at the caudal pole.

Spleen

The **spleen** presented a smooth homogeneous parenchyma hyperechoic to liver and renal cortical parenchyma. The capsule was smooth without noticeable expansion or deviation from within the spleen or adjacent pathology. The splenic vasculature demonstrated normal volume without signs of congestion or thrombosis. No sonographic evidence of acute or chronic inflammatory, neoplastic, or infarctual changes were noted.

Liver

The **liver** images submitted revealed subjectively normal liver size, contour, and structure. Parenchymal echogenicity was naturally coarse and hypoechoic to the spleen. Vascular and biliary tracts were of normal volume with no evidence of congestion. The gallbladder presented acceptably thin walls with primarily anechoic content. The cystic and common bile ducts were normal. No pathological hepatic



PATIENT

Baron Sloan

lymphadenopathy was evident. No overt structural evidence of inflammatory, infiltrative or regenerative pathology was evident.

SPECIES

Canine

Gastrointestinal

Examination of the **gastrointestinal tract** revealed a stomach and intestine free of stasis, of normal wall thickness, acceptable curvilinear mural detail, and peristaltic activity. Small and large intestine demonstrated normal luminal chyme and stool consistency respectively. No obstructive or overt infiltrative disease was noted. No associated abnormal lymphatic activity was noted.

BREED

Doberman

Pancreas

SEX

Male

The base and limbs of the **pancreas** were observed to be largely isoechoic to surrounding omental fat. Pancreatic duct and capsular contour were acceptably normal and parenchyma respected normal curvilinear patterns. No overt evidence of active inflammatory or neoplastic disease was noted.

AGE

5 Years

Other

The testicles were imaged and found to be uniform. No evidence of pathology in the testicular tissue or epididymis.

WEIGHT

80.7 lbs

ULTRASONOGRAPHIC FINDINGS

- BPH/prostatitis pattern with potential abscessation.
- Age related renal changes.

INTERPRETED BY

Eric Lindquist, DMV,
DABVP (CFM), Cert.
IVUSS

INTERPRETATION OF THE FINDINGS & FURTHER RECOMMENDATIONS

Ultrasound guided drainage may be difficult given the position of the pathology. However, drainage of the cysts or possible abscesses with neutering would be ideal. Enrofloxacin could be injected directly into the cyst or abscess if the material appears purulent. Neutering and Enrofloxacin/Clindamycin combination over a 3 week period may be adequate. However, ultrasound guided drainage and direct injection into the prostatic cavities may be ideal/ADAIN procedure. No evidence or suspicion of neoplasia.

IMAGING PERFORMED BY

Greg Shaffer

HOSPITAL NAME

Pawley's Veterinary
Hospital

REFERRING VET

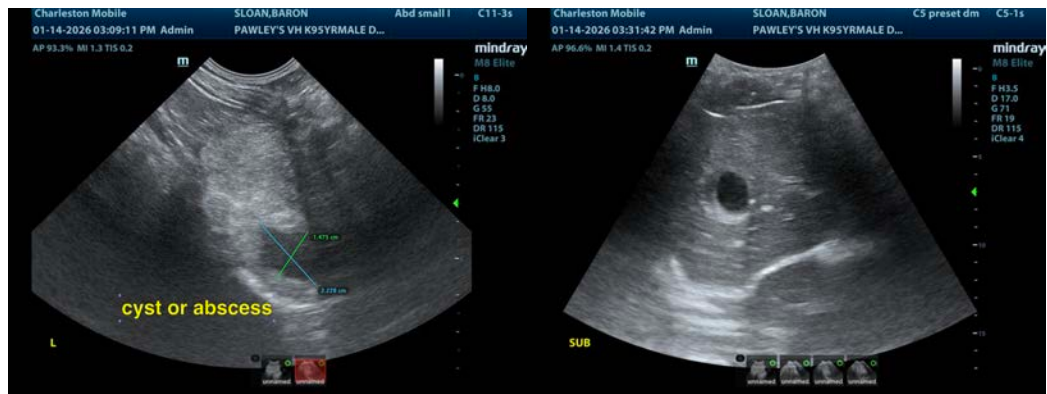Dr. Kiningham

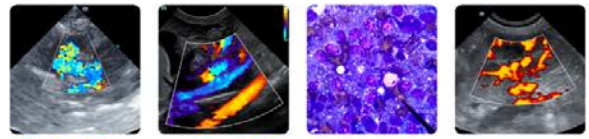
INVOICE

72210

DATE

1/14/26





PATIENT

Baron Sloan

SPECIES

Canine

BREED

Doberman

SEX

Male

AGE

5 Years

WEIGHT

80.7 lbs

INTERPRETED BY

Eric Lindquist, DMV,
 DABVP (CFM), Cert.
 IVUSS

IMAGING PERFORMED BY

Greg Shaffer

HOSPITAL NAME

Pawley's Veterinary
 Hospital

REFERRING VET

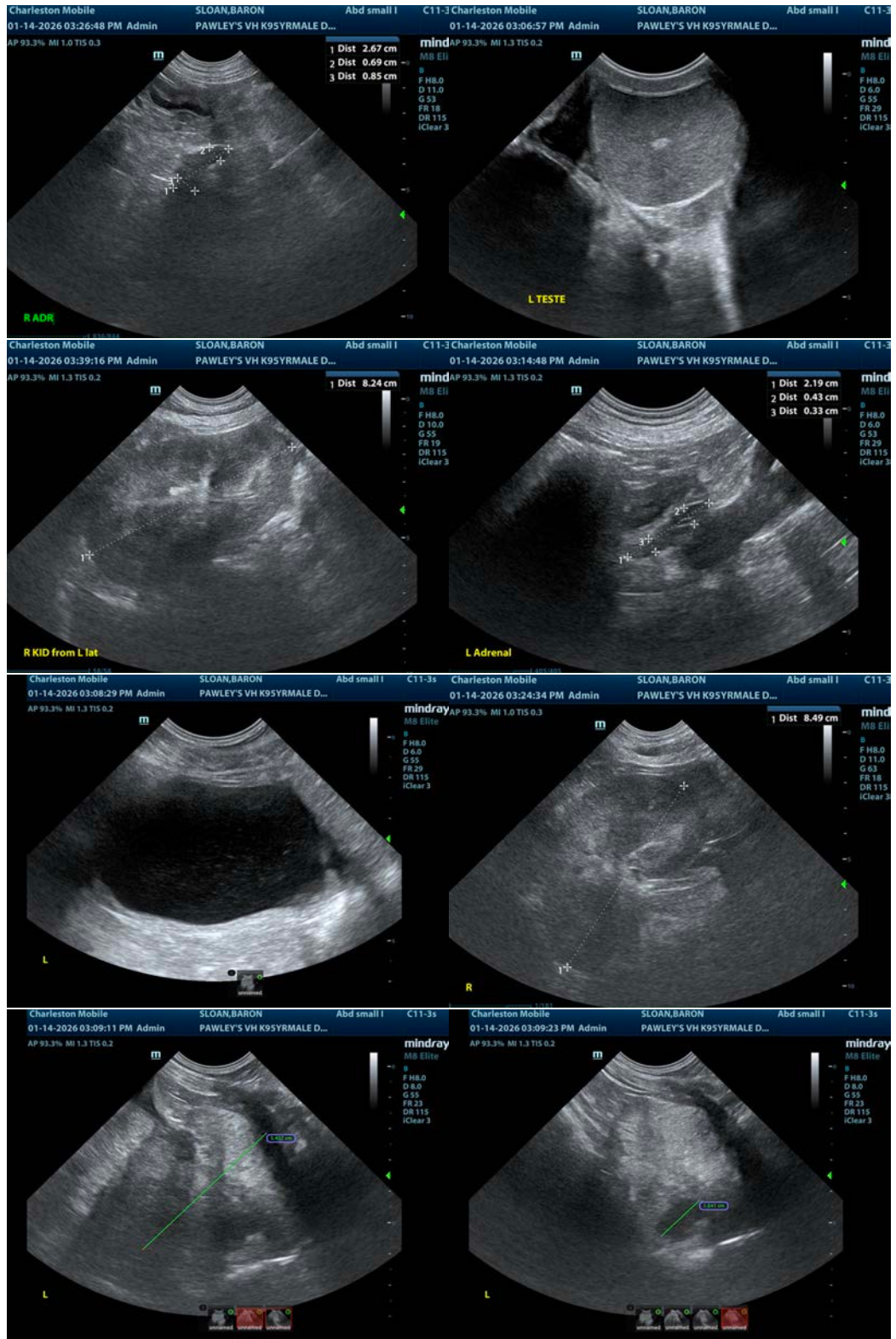
Dr. Kiningham

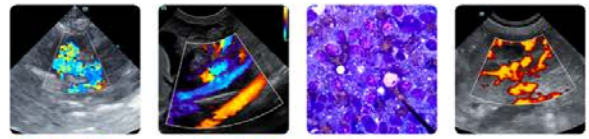
INVOICE

72210

DATE

1/14/26





PATIENT

Baron Sloan

SPECIES

Canine

BREED

Doberman

SEX

Male

AGE

5 Years

WEIGHT

80.7 lbs

INTERPRETED BY

Eric Lindquist, DMV,
 DABVP (CFM), Cert.
 IVUSS

IMAGING PERFORMED BY

Greg Shaffer

HOSPITAL NAME

Pawley's Veterinary
 Hospital

REFERRING VET

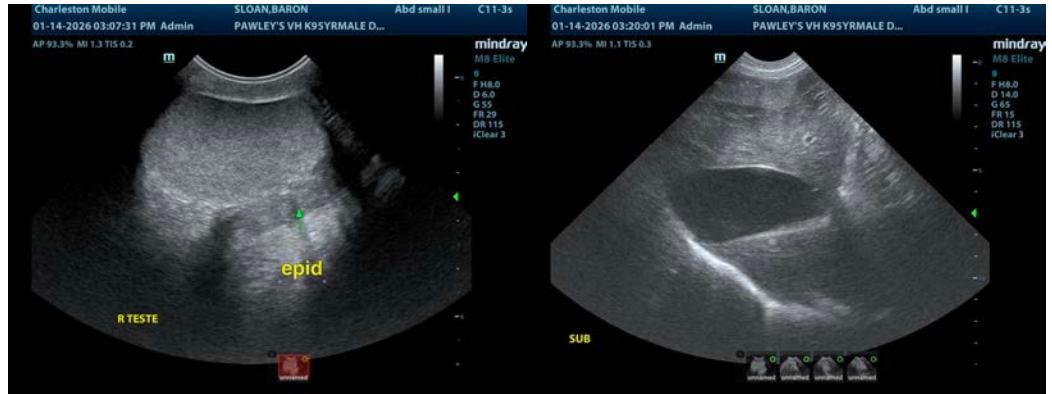Dr. Kiningham

INVOICE

72210

DATE

1/14/26



The information and recommendations provided are based on the images presented by the referring veterinarian/sonographer. No evaluation can be communicated regarding pathology that was not visible in the image/video clips provided.

Thank you for this referral. If the clinical or image interpretation does not parallel your findings or if I can be of any further assistance please contact me.

Eric Lindquist, DMV, DABVP(CFM), Cert. IVUSS,
 CEO, Owner, Founder -- SonoPath.com
info@SonoPath.com