



PATIENT

Sanchez Sebell

SPECIES

Canine

BREED

Mix

SEX

Neutered Male

AGE

12 Years

WEIGHT

12 kg

INTERPRETED BY

Eric Lindquist, DMV

DABVP, Cert. IVUSS

IMAGING PERFORMED BY

Dr. Meliasa Robinson

HOSPITAL NAME

St. Francis Veterinary Center of South Jersey

REFERRING VET

Dr. Meliasa Robinson

INVOICE

44235

DATE

1/14/23

PRESENTING CLINICAL SIGNS

SX 4 cm mast cell tumor ventral abdomen, high grade. Thoracic x-rays clear

Abnormal PE/Chem/CBC/UA Results: Elevated Alkp, Triglyceride, and Cholesterol, elevated Plt count Low USG

ULTRASONOGRAPHIC EXAMINATION OF THE ABDOMEN

Urinary System

The **urinary bladder**, trigone, and pelvic urethra presented normal thicknesses and normal tone. The ureters were not visible which is normal. No uroliths or sediment were visualized and anechoic urine was present. No evidence of inflammatory or neoplastic changes were noted. Ureteral papillae were normal. The pelvic urethra was imaged 2.0 cm beyond the cystourethral junction.

The **kidneys** revealed normal size and structure, corticomedullary definition and ratio for this age. The cortices presented largely uniform texture with normal echogenic relationship to liver and spleen. Medullary structure differed distinctly from the cortex and no evidence of pelvic dilation was present. The capsules were acceptably uniform without significant irregularities. The right kidney measured 5.52 cm. The left kidney measured 5.21 cm.

Adrenal Glands

Both **adrenal glands** were visualized and recognized as having normal shape, size, position and echogenicity for this breed. The phrenic vasculature, glandular echogenicity and detail were unremarkable. Capsule, cortex, and medullary definition were normal for this age patient. The right adrenal gland measured 0.51 cm. The left adrenal gland measured 0.40 cm.

Spleen

The **spleen** presented a smooth homogeneous parenchyma hyperechoic to liver and renal cortical parenchyma. The capsule was smooth without noticeable expansion or deviation from within the spleen or adjacent pathology. The splenic vasculature demonstrated normal volume without signs of congestion or thrombosis. No sonographic evidence of acute or chronic inflammatory, neoplastic, or infarctual changes were noted.

Liver

The **liver** was uniformly swollen with minor, excessive gallbladder debris and over distension with dependent and suspended bile without evidence of overt mucocele formation. However, excessive sludge was present. The liver presented coarse architecture with mildly increased portal markings and subtle, mixed echogenic changes. This is consistent with vacuolar hepatopathy and some level of remodeling and history of inflammatory component. There was no overt suspicion of neoplasia. Nodular changes noted, non-disruptive, most consistent with hyperplasia.

Gastrointestinal

Examination of the **gastrointestinal tract** revealed a stomach and intestine free of stasis, of normal wall thickness, acceptable curvilinear mural detail, and peristaltic activity. Small and large intestine demonstrated normal luminal chyme and stool consistency respectively. No obstructive or overt infiltrative disease was noted. No associated abnormal lymphatic activity was noted.



PATIENT

Sanchez Sebell

SPECIES

Canine

BREED

Mix

SEX

Neutered Male

AGE

12 Years

WEIGHT

12 kg

INTERPRETED BY

Eric Lindquist, DMV

DABVP, Cert. IVUSS

IMAGING PERFORMED BY

Dr. Meliasa Robinson

HOSPITAL NAME

St. Francis Veterinary Center of South Jersey

REFERRING VET

Dr. Meliasa Robinson

INVOICE

44235

DATE

1/14/23

Pancreas

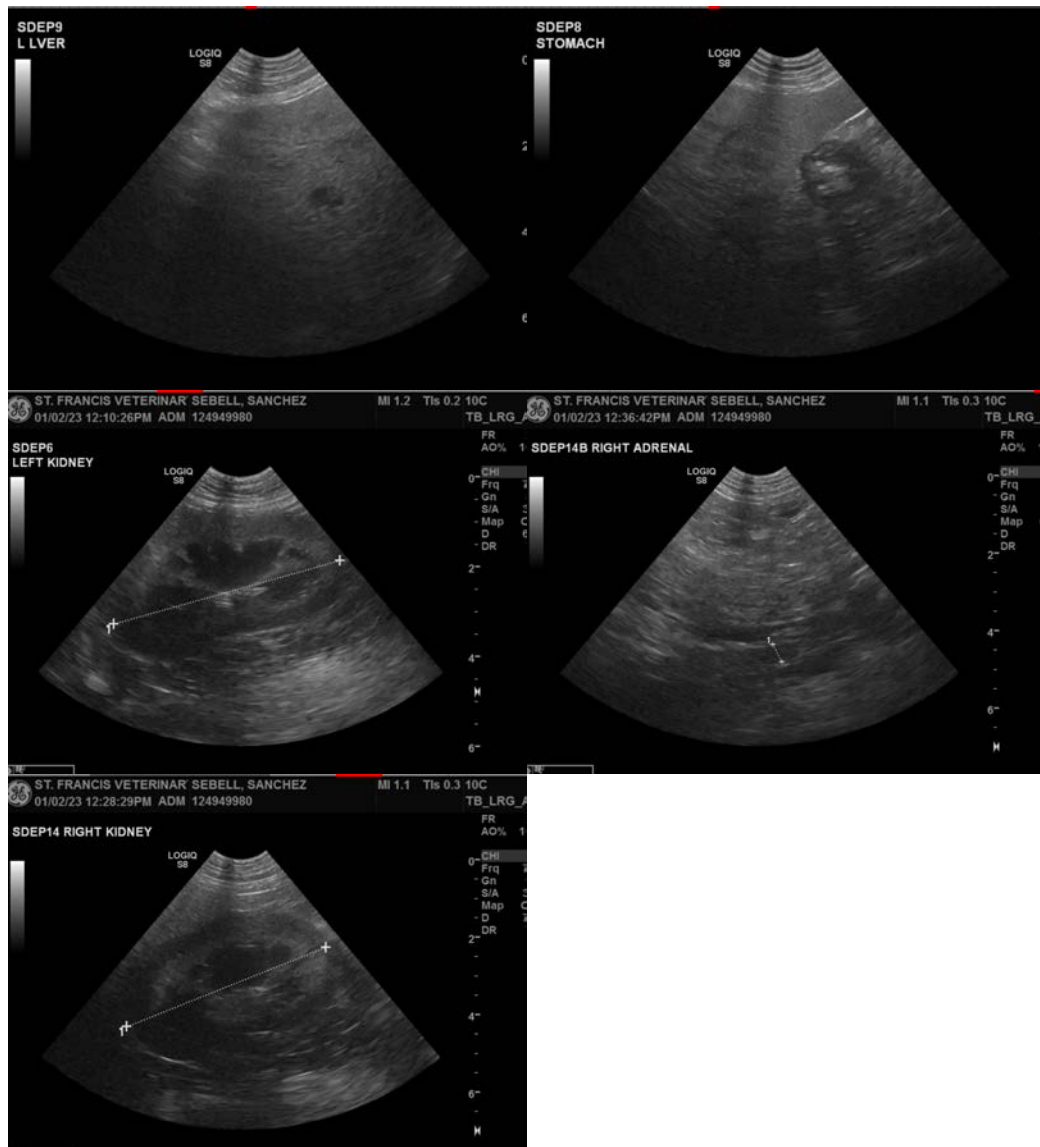
The base and limbs of the **pancreas** were observed to be largely isoechoic to surrounding omental fat. Pancreatic duct and capsular contour were acceptably normal and parenchyma respected normal curvilinear patterns. No overt evidence of active inflammatory or neoplastic disease was noted.

ULTRASONOGRAPHIC FINDINGS

- Benign hepatopathy with minor nodular changes

INTERPRETATION OF THE FINDINGS & FURTHER RECOMMENDATIONS

No overt evidence of mast cell disease. However, screening FNA of the liver warranted to ensure no significant pathology present, yet most consistent with benign hepatopathy with nodular hyperplasia.





PATIENT

Sanchez Sebell

The information and recommendations provided are based on the images presented by the referring veterinarian/sonographer. No evaluation can be communicated regarding pathology that was not visible in the image/video clips provided.

SPECIES

Canine

Thank you for this referral. If the clinical or image interpretation does not parallel your findings or if I can be of any further assistance please contact me.

BREED

Mix

Eric Lindquist, DMV, DABVP, Cert. IVUSS, CEO of SonoPath.com

info@SonoPath.com

SEX

Neutered Male

AGE

12 Years

WEIGHT

12 kg

INTERPRETED BY

Eric Lindquist, DMV

DABVP, Cert. IVUSS

**IMAGING
PERFORMED BY**

Dr. Meliasa Robinson

HOSPITAL NAME

St. Francis Veterinary
Center of South Jersey

REFERRING VET

Dr. Meliasa Robinson

INVOICE

44235

DATE

1/14/23