



## PATIENT

Roman McGrath

## SPECIES

Feline

## BREED

DSH

## SEX

Male

## AGE

6 Months

## WEIGHT

7.5

## INTERPRETED BY

Eric Lindquist, DMV  
DABVP, Cert. IVUSS

## IMAGING PERFORMED BY

Jenn

## HOSPITAL NAME

Rockaway AH

## REFERRING VET

Dr. Maniar

## INVOICE

20562

## DATE

1/14/23

## PRESENTING CLINICAL SIGNS

History: re check u/s from yesterday showed one dilated small intestinal segment re checking bowels

## LIMITED ULTRASONOGRAPHIC EXAMINATION

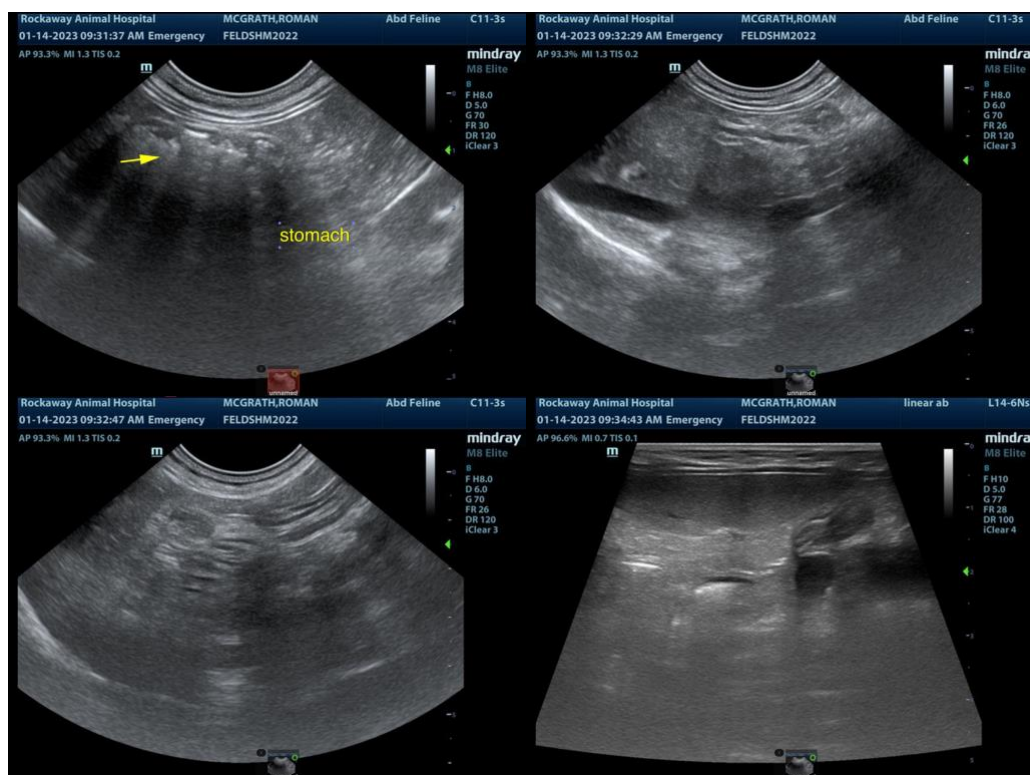
The **gastrointestinal tract** was largely normalized in this patient. Minor mesenteric lymphadenopathy was present, measuring up to 5.0 mm in width. No evidence of gastrointestinal intestinal dilation.

## ULTRASONOGRAPHIC FINDINGS

- Normalized GI tract

## INTERPRETATION OF THE FINDINGS & FURTHER RECOMMENDATIONS

Supportive care should prove effective.



The information and recommendations provided are based on the images presented by the referring veterinarian. No evaluation can be communicated regarding pathology that was not visible in the image/video clips provided.

Thank you for this referral. If the clinical or image interpretation does not parallel your findings or if I can be of any further assistance please contact me.

**Eric Lindquist**, DMV, DABVP, Cert. IVUSS, CEO of SonoPath.com  
info@SonoPath.com