

**PATIENT PRESENTING CLINICAL SIGNS**

**Truly Mangold** History: BAR, friendly. Presented for vomiting, diarrhea and decreased appetite. Potential exposure to coccidia. 2-3 cm reducible soft tissue mass in right inguinal fold. Mass is non-painful. Abnormal PE/Chem/CBC/UA Results: Waiting for owner to bring in fecal sample. Current Medications Dose of pyrantel given.

**SPECIES**

Feline

**ULTRASONOGRAPHIC EXAMINATION OF THE ABDOMEN**

**Urinary System**

**BREED**

DSH

The **urinary bladder**, trigone, and pelvic urethra presented normal thicknesses and normal tone. The ureters were not visible which is normal. No uroliths or sediment were visualized and anechoic urine was present. No evidence of inflammatory or neoplastic changes were noted. Ureteral papillae were normal.

**SEX**

Intact Female

The **kidneys** revealed normal size and structure, corticomedullary definition and ratio for this age. The cortices presented largely uniform texture with normal echogenic relationship to liver and spleen. Medullary structure differed distinctly from the cortex and no evidence of pelvic dilation was present. The capsules were acceptably uniform without significant irregularities. The left kidney measured 3.56 cm. The right kidney measured 4.0 cm.

**AGE**

14 Weeks

**Adrenal Glands**

Both **adrenal glands** were visualized and recognized as having normal shape, size, position and echogenicity for this breed. The phrenic vasculature, glandular echogenicity and detail were unremarkable. Capsule, cortex, and medullary definition were normal for this age patient. The right adrenal gland measured 0.3 cm. The left adrenal gland measured 0.39 cm.

**WEIGHT**

5.23 Lbs.

**Spleen**

The **spleen** presented a smooth homogeneous parenchyma hyperechoic to liver and renal cortical parenchyma. The capsule was smooth without noticeable expansion or deviation from within the spleen or adjacent pathology. The splenic vasculature demonstrated normal volume without signs of congestion or thrombosis. No sonographic evidence of acute or chronic inflammatory, neoplastic, or infarctual changes were noted.

**INTERPRETED BY**

Eric Lindquist, DMV,  
DABVP, Cert. IVUSS

**Liver**

The **liver** images submitted revealed subjectively normal liver size, contour, and structure. Parenchymal echogenicity was naturally coarse and hypoechoic to the spleen. Vascular and biliary tracts were of normal volume with no evidence of congestion. The gallbladder presented acceptably thin walls with primarily anechoic content. The cystic and common bile ducts were normal. No pathological hepatic lymphadenopathy was evident. No overt structural evidence of inflammatory, infiltrative or regenerative pathology was evident.

**HOSPITAL NAME**

West Eugene AH

**REFERRING VET**

Dr. Supan

**Gastrointestinal**

The **gastrointestinal tract** revealed normal chyme transit. A minor amount of chyme was noted in the stomach. No evidence of obstruction or intussusceptions. Gastrointestinal structure was unremarkable. The colon revealed normal stool consistency.

**INVOICE NUMBER**

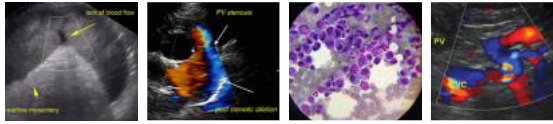
13442

**Pancreas**

The base and limbs of the **pancreas** were observed to be largely isoechoic to surrounding omental fat. Pancreatic duct and capsular contour were acceptably normal and parenchyma

**DATE**

1/14/22



**PATIENT** respected normal curvilinear patterns. No overt evidence of active inflammatory or neoplastic disease was noted.

Truly Mangold **ULTRASONOGRAPHIC FINDINGS**

- SPECIES**
- Some retention of ingesta in the stomach, consistent with postprandial presentation
  - Structurally normal abdomen

Feline **INTERPRETATION OF THE FINDINGS & FURTHER RECOMMENDATIONS**

No evidence of pathology.

**BREED**

DSH

**SEX**

Intact Female

**AGE**

14 Weeks

**WEIGHT**

5.23 Lbs.

**INTERPRETED BY**

Eric Lindquist, DMV,  
DABVP, Cert. IVUSS

**HOSPITAL NAME**

West Eugene AH

**REFERRING VET**

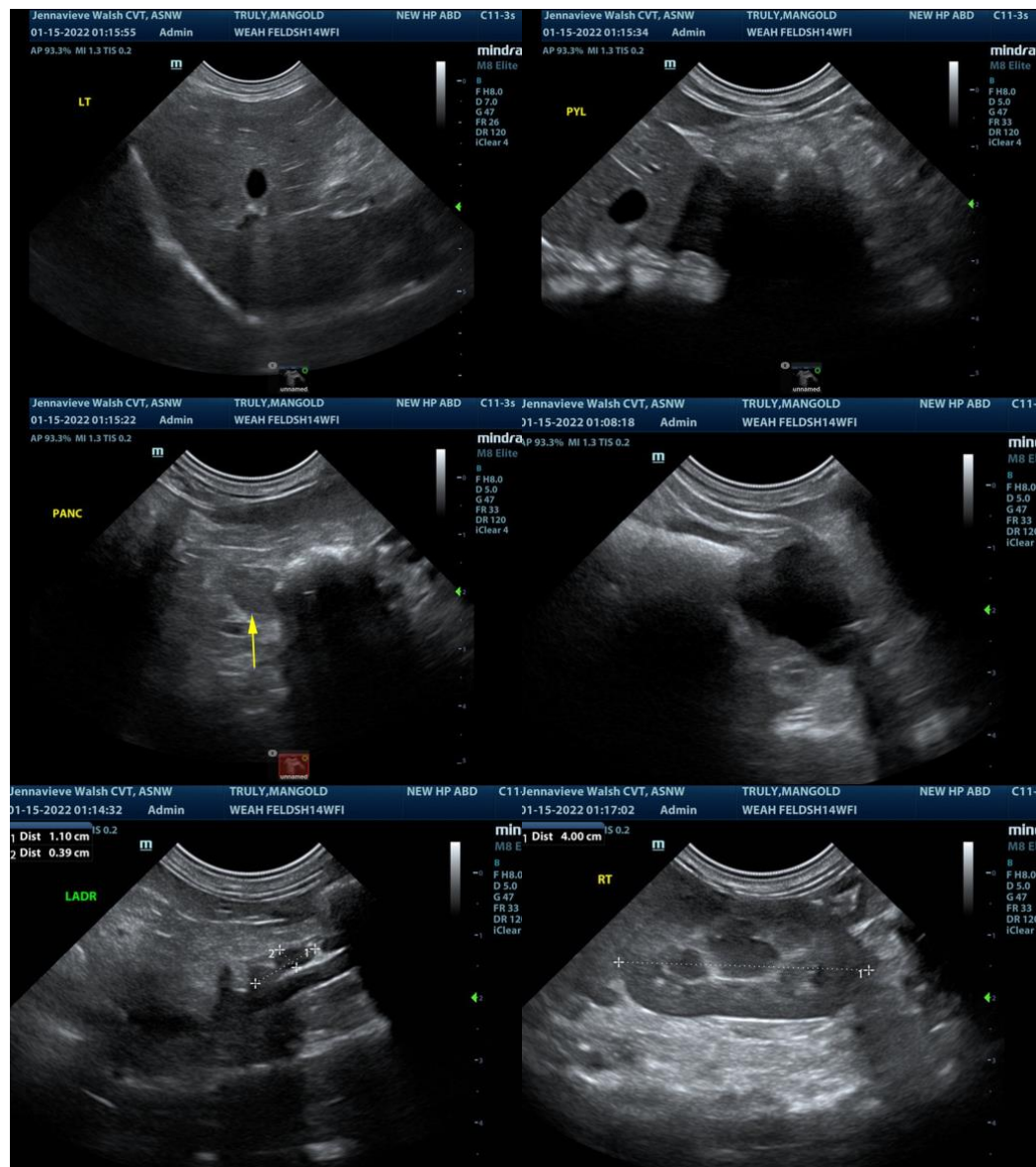
Dr. Supan

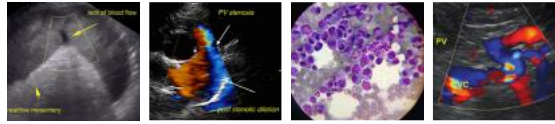
**INVOICE NUMBER**

13442

**DATE**

1/14/22





**PATIENT**  
Truly Mangold

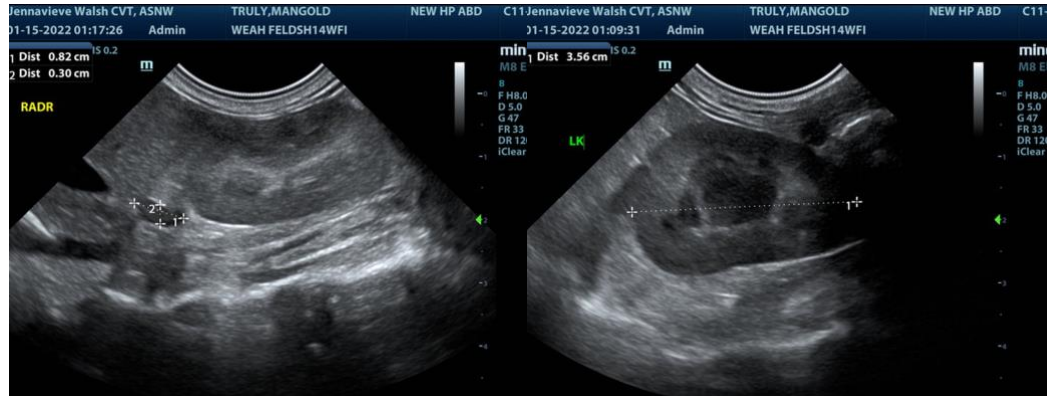
**SPECIES**  
Feline

**BREED**  
DSH

**SEX**  
Intact Female

**AGE**  
14 Weeks

**WEIGHT**  
5.23 Lbs.



The information and recommendations provided are based on the images presented by the referring veterinarian. No evaluation can be communicated regarding pathology that was not visible in the image/video clips provided.

Thank you for this referral. If the clinical or image interpretation does not parallel your findings or if I can be of any further assistance please contact me.

**Eric Lindquist**, DMV, DABVP, Cert. IVUSS, CEO of SonoPath.com  
Eric.Lindquist@SonoPath.com

**INTERPRETED BY**  
Eric Lindquist, DMV, DABVP, Cert. IVUSS

**HOSPITAL NAME**  
West Eugene AH

**REFERRING VET**  
Dr. Supan

**INVOICE NUMBER**  
13442

**DATE**  
1/14/22