



**PATIENT PRESENTING CLINICAL SIGNS**

Seema Hulsing Newly acquired murmur, asymptomatic  
 Abnormal PE/Chem/CBC/UA Results: Grade III/VI systolic heart murmur Average Dinamap  
 blood pressure measurements 160/123 (140 mean)

**SPECIES**

Feline

**ULTRASONOGRAPHIC EXAMINATION OF THE HEART**

**BREED**

Domestic Shorthair

**SEX**

Spayed Female

**AGE**

15 years

**WEIGHT**

9.2 lbs

The echocardiogram in this patient demonstrated normal **left atrial** size based on 3 separate LA measurements. The cranial and caudal **mitral** valve leaflets presented normal linear structure and kinetics.. The **left ventricle** presented normal thicknesses with linear contour and was not dilated nor restricted. The **myocardium** presented normal echogenicity without subjective evidence of significant fibrotic or ischemic disease. **Contractility** of the ventricular walls was adequate and in normal range for this patient evidenced by the fractional shortening measurement and subjective evaluation of the different regions and angles of the myocardium. The **left ventricular outflow** tract demonstrated normal laminar flow and subjective structural integrity. The **right atrium** and auricle revealed normal size, structure and content. No evidence of masses was noted or chamber overload. **Tricuspid** valvular assessment demonstrated adequate linear morphology and kinetics. The **right ventricle** was of normal size (1/3 diameter of LV), chordae structure, myocardial echogenicity and thickness. **Pulmonic** tract assessment revealed normal valve structure, laminar flow, and diameter (approx.1:1 pa/ao ratio). No visible **pericardial** or free pleura fluid was noted or extra cardiac pathology in the visible planes. The cranial **mediastinum** and **pericardial regions** were free of masses in the visible window.

**INTERPRETED BY**

Eric Lindquist, DMV  
 DABVP, Cert. IVUSS

**IMAGING PERFORMED BY**

Kelly Romero

**HOSPITAL NAME**

Midtown VMC

**REFERRING VET**

Dr. Hunter

| FELINE CARDIAC PARAMETERS  | BODY WEIGHT lbs | HR (BPM)                  | IVSd (cm)  | LVIDd (cm)      | LVWd (cm)       | FS (%)    | EF (%) |
|--|-----------------|---------------------------|--|-----------------|-----------------|-----------|--------|
| NORMAL PARAMETER   | -----           | 150-240                   | 0.3-0.6  | 1.0-2.1         | 0.25-0.6        | 35-67     | 80-100 |
| PATIENT  | 9.2             | 180                       | 0.4  | 1.2             | 0.5             | 55        | 90     |
| FELINE CARDIAC PARAMETERS  | LA/AO (Boon)    | LA/AO HEART BASE (Sisson) | LA 2D 4-chamber long axis AS to FW (Sisson) (cm) | LVOT VEL. (m/s) | RVOT VEL. (m/s) | IVRT (m/) |        |
| NORMAL PARAMETER   | <1.5            | 0.88-1.79                 | 0.7-1.7  |                 | <1.6            | <1.3      | 40-60  |
| PATIENT  | 1.08            | 1.04                      | 1.1  |                 |                 | 0.7       | NM     |
| Adapted from June Boon, Veterinary Echocardiography, 1998<br>Sisson D et al. JVIM 1991; 5: 232, Jacobs et al. Am J Vet Res 1985; 46:1705 |                 |                           |  |                 |                 |           |        |

**INVOICE**

95250

**DATE**

1/14/22

**ULTRASONOGRAPHIC FINDINGS**

Normal echocardiogram.  
 Likely flow murmur. No structural evidence of disease.  
 Normal laminar flow.



**PATIENT**

Seema Hulsing

**SPECIES**

Feline

**BREED**

Domestic Shorthair

**SEX**

Spayed Female

**AGE**

15 years

**WEIGHT**

9.2 lbs

**INTERPRETED BY**

Eric Lindquist, DMV  
DABVP, Cert. IVUSS

**IMAGING PERFORMED BY**

Kelly Romero

**HOSPITAL NAME**

Midtown VMC

**REFERRING VET**

Dr. Hunter

**INVOICE**

95250

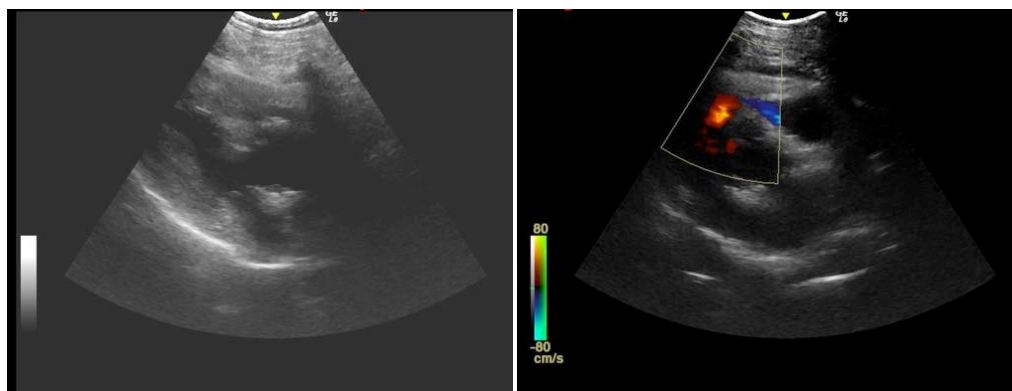
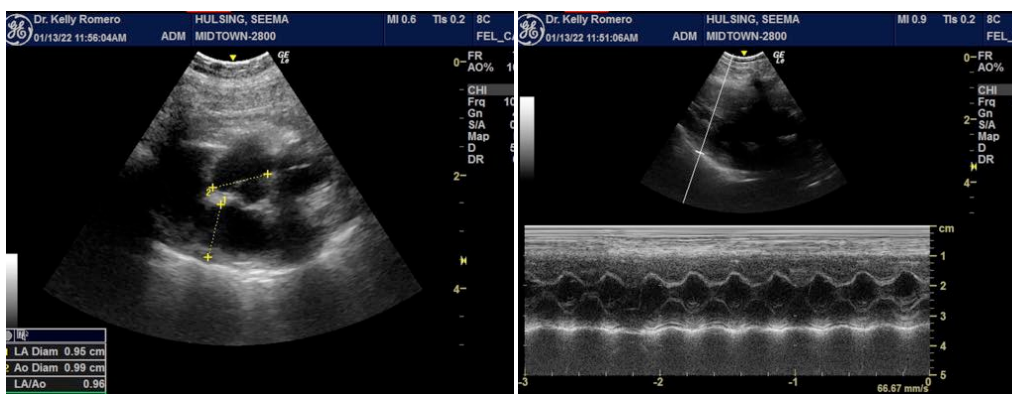
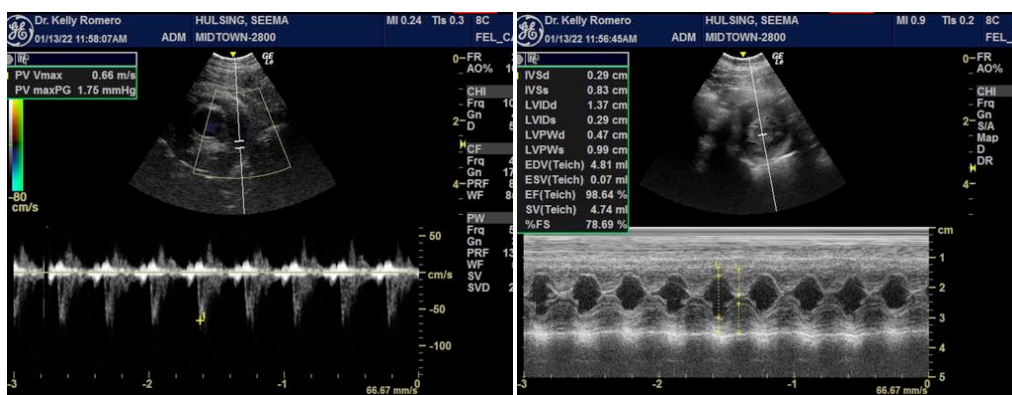
**DATE**

1/14/22

**INTERPRETATION OF THE FINDINGS & FURTHER RECOMMENDATIONS**

Benign flow murmurs are common in cats. This may be owing to volume shifts, tachycardia, benign (DRVOTO) right ventricular outflow changes, trivial turbulence in any of the valvular apparatuses, or possibly excessive stethoscope pressure against the chest according to a recent study These are physiologically benign and unrelated to specific pathology.

If the systolic blood pressure oscillates around or above 160 in a non-white coat effect environment then Amlodopine can be considered. However, structurally and functionally the heart is essentially normal.





**PATIENT**

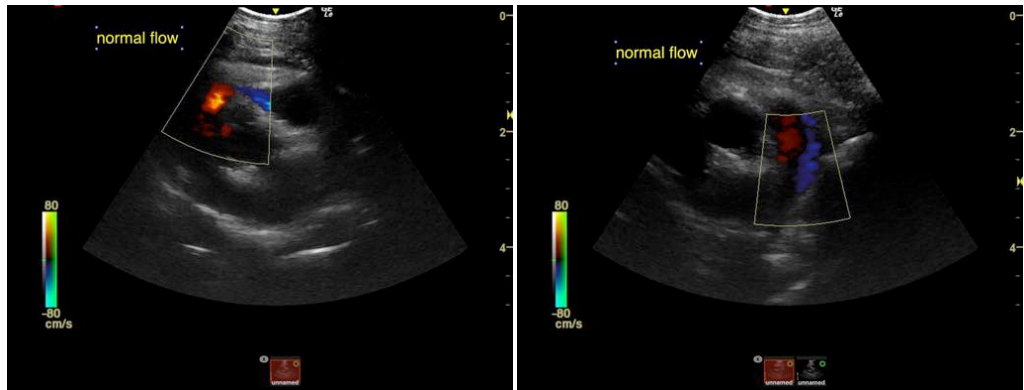
Seema Hulsing

**SPECIES**

Feline

**BREED**

Domestic Shorthair



**SEX**

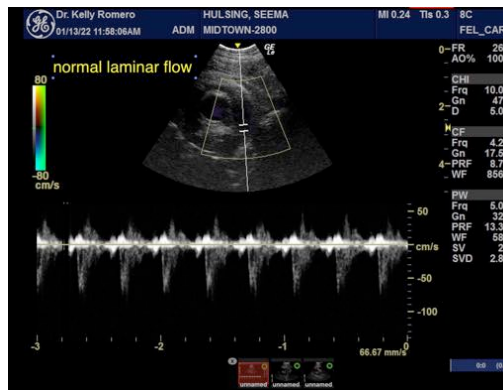
Spayed Female

**AGE**

15 years

**WEIGHT**

9.2 lbs



**INTERPRETED BY**

Eric Lindquist, DMV  
DABVP, Cert. IVUSS

**IMAGING PERFORMED BY**

Kelly Romero

**HOSPITAL NAME**

Midtown VMC

**REFERRING VET**

Dr. Hunter

**INVOICE**

95250

**DATE**

1/14/22

The information and recommendations provided are based on the images presented by the referring veterinarian. No evaluation can be communicated regarding pathology that was not visible in the image/video clips provided.

Thank you for this referral. If the clinical or image interpretation does not parallel your findings or if I can be of any further assistance please contact me.

Eric Lindquist, DMV, DABVP, Cert. IVUSS, CEO of SonoPath.com  
info@SonoPath.com