



**DATE**  
1/14/22

## PRESENTING CLINICAL SIGNS

History: cryptorchid.

**PATIENT**  
Scherzer Gleason

Date of Previous IntraPet Ultrasound: No previous IntraPet scans.  
Sedation: Dexdomitor/Torbugesic IV.  
Stat Report: Not requested.  
Imaging Performed By: Stephanie Pearce RDCS, RVT.

**SPECIES**

Canine

**BREED**

Collie Mixed Breed

**SEX**

Male Intact

**AGE**

5/23/21

**WEIGHT**

32.2 Lbs.

## LIMITED ULTRASONOGRAPHIC EXAMINATION

The urinary bladder, trigone, and pelvic urethra presented normal thicknesses and normal tone. The ureters were not visible which is normal. No uroliths or sediment were visualized and anechoic urine was present. No evidence of inflammatory or neoplastic changes were noted. Ureteral papillae were normal. The prostate was uniform, measuring 1.9 cm in width.

The kidneys revealed normal size and structure, corticomedullary definition and ratio for this age. The cortices presented largely uniform texture with normal echogenic relationship to liver and spleen. Medullary structure differed distinctly from the cortex and no evidence of pelvic dilation was present. The capsules were acceptably uniform without significant irregularities. The right kidney measured 5.17 cm.

The left testicle is descended, measuring 3.05 cm.

The right testicle measured 2.25 cm. The right testicle was extraabdominal in the right inguinal canal, outside the body wall.

## ULTRASONOGRAPHIC FINDINGS

- Extraabdominal position, right cryptorchid, just superficial to the abdominal inguinal canal and just to the right of the urinary bladder and prostate

**INTERPRETED BY**

Eric Lindquist, DMV  
DABVP, Cert. IVUSS

## INTERPRETATION OF THE FINDINGS & FURTHER RECOMMENDATIONS

Surgical removal recommended.

**HOSPITAL NAME**

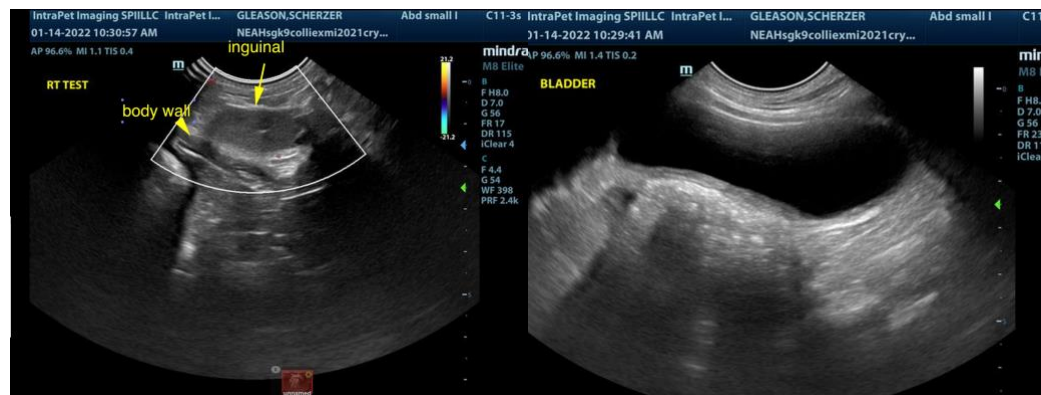Northeast AH

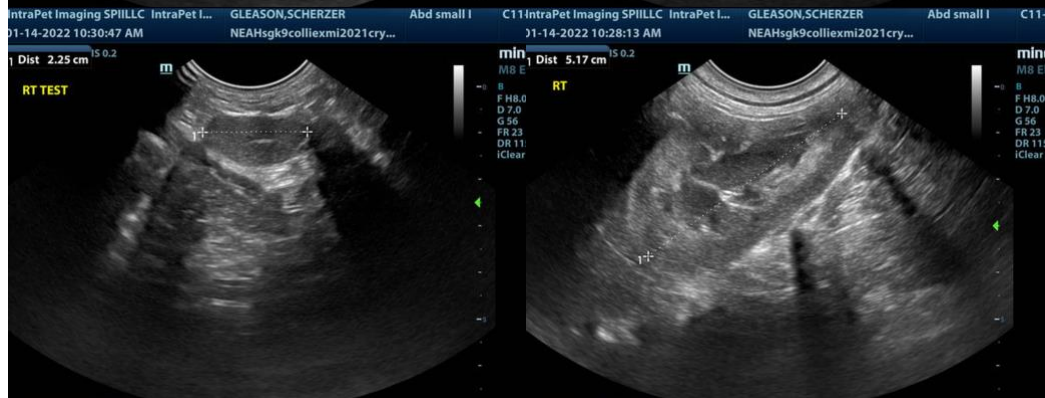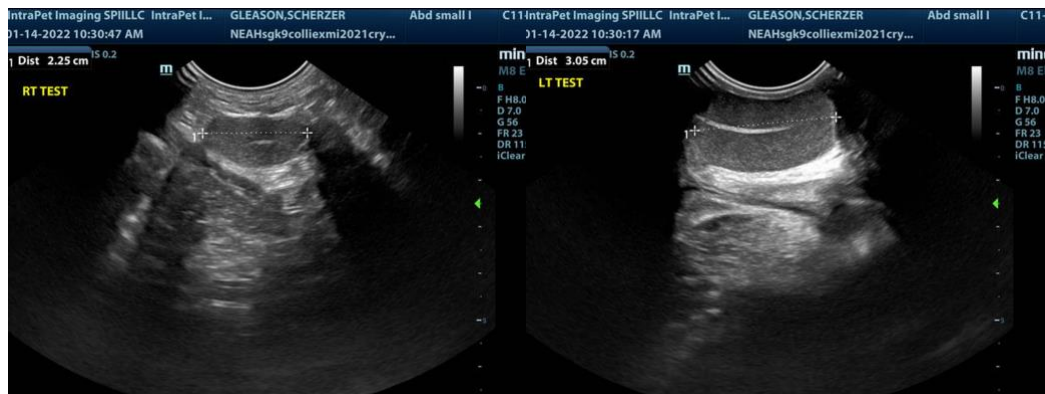
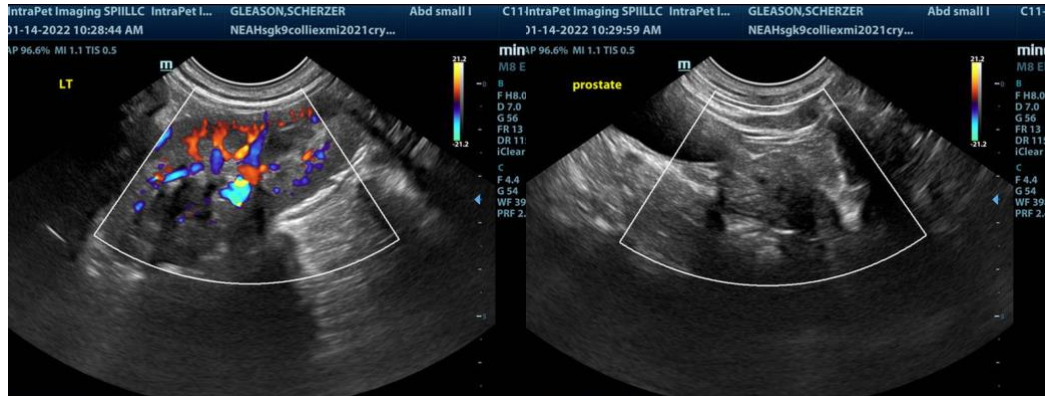
**REFERRING VET**

Dr. Simpson

**INVOICE**

13448





The information and recommendations provided are based on the images presented by the referring veterinarian. No evaluation can be communicated regarding pathology that was not visible in the image/video clips provided.

Thank you for this referral. If the clinical or image interpretation does not parallel your findings or if I can be of any further assistance please contact me.

Eric Lindquist, DMV, DABVP, Cert. IVUSS, CEO of SonoPath.com  
Eric.Lindquist@SonoPath.com