

**DATE**  
1/14/22

## PRESENTING CLINICAL SIGNS

History: Monocryptorchid.

## PATIENT

Ollie Paolicelli

Date of Previous IntraPet Ultrasound: No previous IntraPet scans.  
Sedation: Dexdomitor/Torbugesic IV.  
Stat Report: Not requested.  
Imaging Performed By: Stephanie Pearce RDCS, RVT.

## SPECIES

Canine

## BREED

English Setter

## SEX

Intact Male

## AGE

7/28/19

## WEIGHT

73 Lbs.

## INTERPRETED BY

Eric Lindquist, DMV  
DABVP, Cert. IVUSS

## HOSPITAL NAME

Northeast AH

## REFERRING VET

Dr. Simpson

## INVOICE

13447

## LIMITED ULTRASONOGRAPHIC EXAMINATION

The kidneys revealed normal size and structure, corticomedullary definition and ratio for this age. The cortices presented largely uniform texture with normal echogenic relationship to liver and spleen. Medullary structure differed distinctly from the cortex and no evidence of pelvic dilation was present. The capsules were acceptably uniform without significant irregularities. The left kidney measured 6.73 cm. The right kidney measured 6.73 cm.

The prostate was uniform, measuring 3.16 cm.

The left testicle was descended, uniform- no evident pathology.

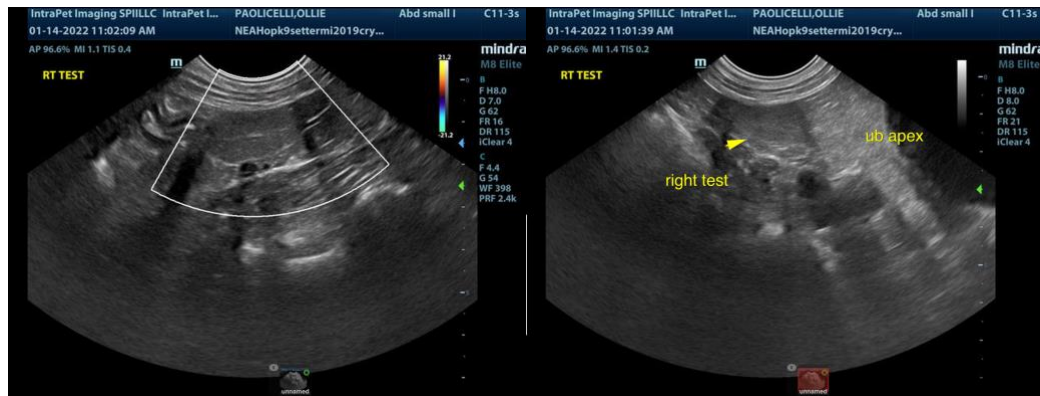
The right testicle was retained in the intraabdominal cavity, measuring 2.39 cm. The right testicle was cryptorchid 1.5 cm – 2.0 cm, just cranial to the apex of the urinary bladder at moderate repletion. Appeared to be adjacent to the body wall.

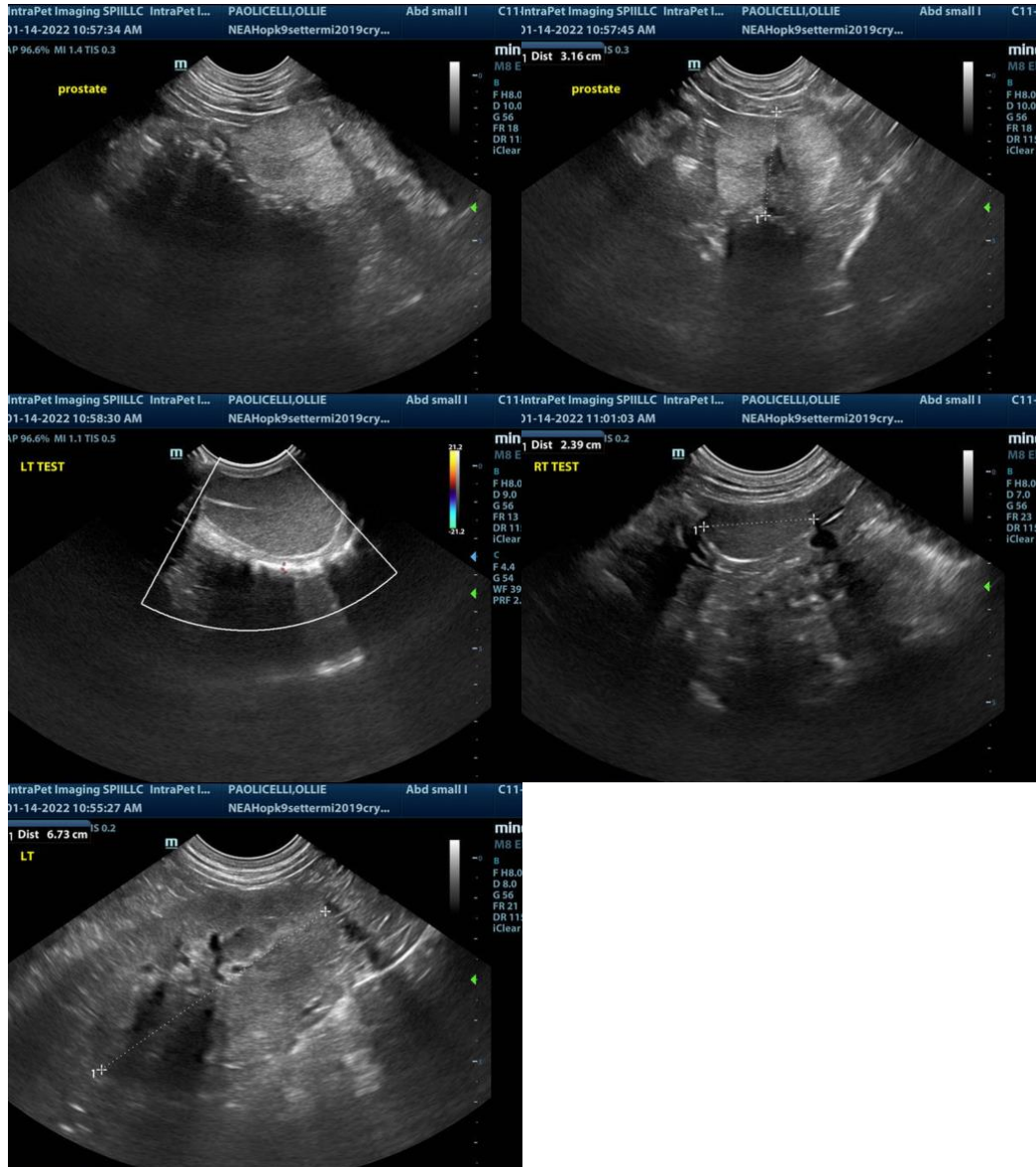
## ULTRASONOGRAPHIC FINDINGS

- Intraabdominal cryptorchid, just cranial to the urinary bladder
- Normal prostate
- Normal descended left testicle

## INTERPRETATION OF THE FINDINGS & FURTHER RECOMMENDATIONS

Intraabdominal approach recommended. Likely midline.





The information and recommendations provided are based on the images presented by the referring veterinarian. No evaluation can be communicated regarding pathology that was not visible in the image/video clips provided.

Thank you for this referral. If the clinical or image interpretation does not parallel your findings or if I can be of any further assistance please contact me.

**Eric Lindquist, DMV, DABVP, Cert. IVUSS, CEO of SonoPath.com**  
 Eric.Lindquist@SonoPath.com