SonoPath
Clinical Sonography & Telecytology

EDUCATIONAL TELECONSULTATION SERVICES™

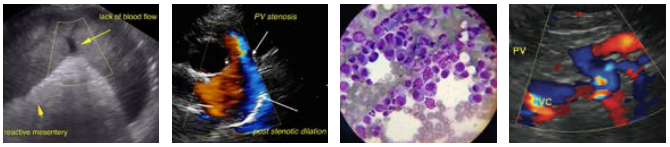

SonoPath.com
1-800-838-4268 info@sonopath.com

PATIENT

Lilly Belle Riccio

SPECIES

Canine

BREED

Golden Retriever

SEX

Spayed Female

AGE

13 years

WEIGHT

60 lbs

INTERPRETED BY

Eric Lindquist, DMV
DABVP, Cert. IVUSS

IMAGING PERFORMED BY

Diane McFadden, RVT

HOSPITAL NAME

Long Valley AH

INVOICE

95242

DATE

1/14/22

PRESENTING CLINICAL SIGNS

Hx of splenectomy (2020) - benign. Previous US on 12/30/20, 1/8/21, 2/3/21, 11/15/21. Liver nodule noted on past US (not conducive to FNA). chest rads Nov 2020 clean. On galliprant 60 mg sid
ACTH 12/9/21: pre 5.4, post 16.5 CBC/chem/UA not performed.

ULTRASONOGRAPHIC EXAMINATION OF THE ABDOMEN

Urinary System

The **urinary bladder** presented chronic cystitis pattern with bladder wall hypertrophy and coalescing, non-shadowing concretion that measured 1.3 cm.

The **kidneys** revealed largely normal size and structure, corticomedullary definition and ratio (cortex 1/3 of medulla) were essentially maintained with some age-related loss of curvilinear patterns regarding the capsule and C/M junction. The cortices presented largely uniform texture with some increased echogenicity expected for this age patient. Medullary structure differed distinctly from that of the cortex and no evidence of pelvic dilation was present. The right kidney measured 5.92 cm. The left kidney measured 5.4 cm.

Adrenal Glands

Both **adrenal glands** were visualized and recognized as having normal shape, size, position and echogenicity for this breed. The phrenic vasculature, glandular echogenicity and detail were unremarkable. Capsule, cortex, and medullary definition were normal for this age patient. The left adrenal gland measured 2.26 x 0.63 cm at the caudal pole and 0.57 cm at the cranial pole. The right adrenal gland measured 2.14 x 1.15 cm at the cranial pole and 0.78 cm at the caudal pole.

Spleen

The **spleen** was not visualized in this patient as it was previously removed.

Liver

The **liver** revealed heterogenous parenchymal changes with a mildly subnormal size. A hypoechoic nodule was noted in the left medial liver. This is similar to the prior sonogram. There was no evidence of progression. The nodule measured 3.5 x 2.9 cm. The gallbladder was unremarkable.

Gastrointestinal

Examination of the **gastrointestinal tract** revealed a stomach and intestine free of stasis, of normal wall thickness, acceptable curvilinear mural detail, and peristaltic activity. Small and large intestine demonstrated normal luminal chyme and stool consistency respectively. No obstructive or overt infiltrative disease was noted. No associated abnormal lymphatic activity was noted.

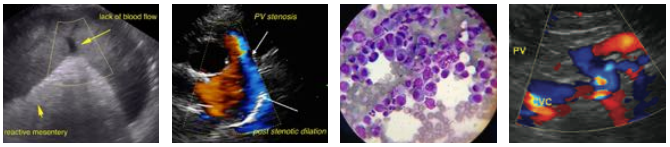

SonoPath.com
1-800-838-4268 info@sonopath.com

PATIENT

Lilly Belle Riccio

SPECIES

Canine

BREED

Golden Retriever

SEX

Spayed Female

AGE

13 years

WEIGHT

60 lbs

INTERPRETED BY

Eric Lindquist, DMV
DABVP, Cert. IVUSS

IMAGING PERFORMED BY

Diane McFadden, RVT

HOSPITAL NAME

Long Valley AH

INVOICE

95242

DATE

1/14/22

Pancreas

The base and limbs of the **pancreas** were observed to be largely isoechoic to surrounding omental fat. Pancreatic duct and capsular contour were acceptably normal and parenchyma respected normal curvilinear patterns. No overt evidence of active inflammatory or neoplastic disease was noted.

ULTRASONOGRAPHIC FINDINGS

Chronic cystitis bladder pattern with coalesced debris.

Persistent stable hyperplastic nodule in the liver. Mild to moderate hepatic remodeling.

Moderate degenerative renal changes.

INTERPRETATION OF THE FINDINGS & FURTHER RECOMMENDATIONS

Urinalysis is warranted. Geriatric diet is recommended. The renal values should be monitored fairly frequently as the kidneys appear to be 50-60% compromised from a subjective standpoint.

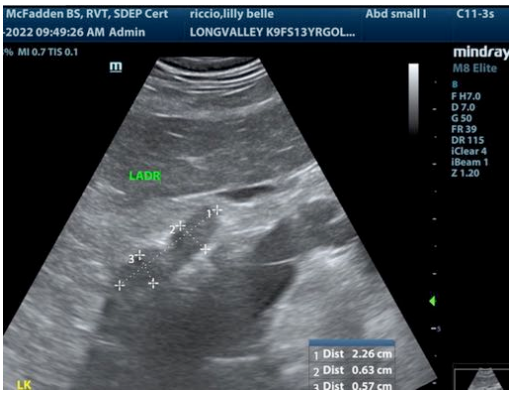

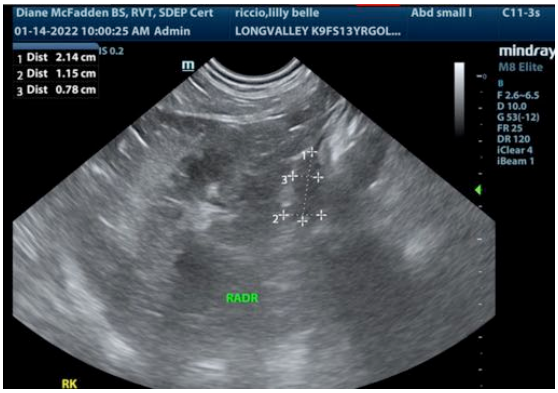

SonoPath

Clinical Sonography & Telecytology

EDUCATIONAL TELECONSULTATION SERVICES™

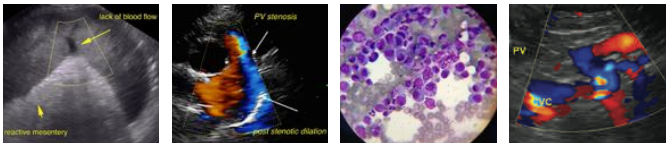

SonoPath.com™
1-800-838-4268 info@sonopath.com

PATIENT

Lilly Belle Riccio

SPECIES

Canine

BREED

Golden Retriever

SEX

Spayed Female

AGE

13 years

WEIGHT

60 lbs

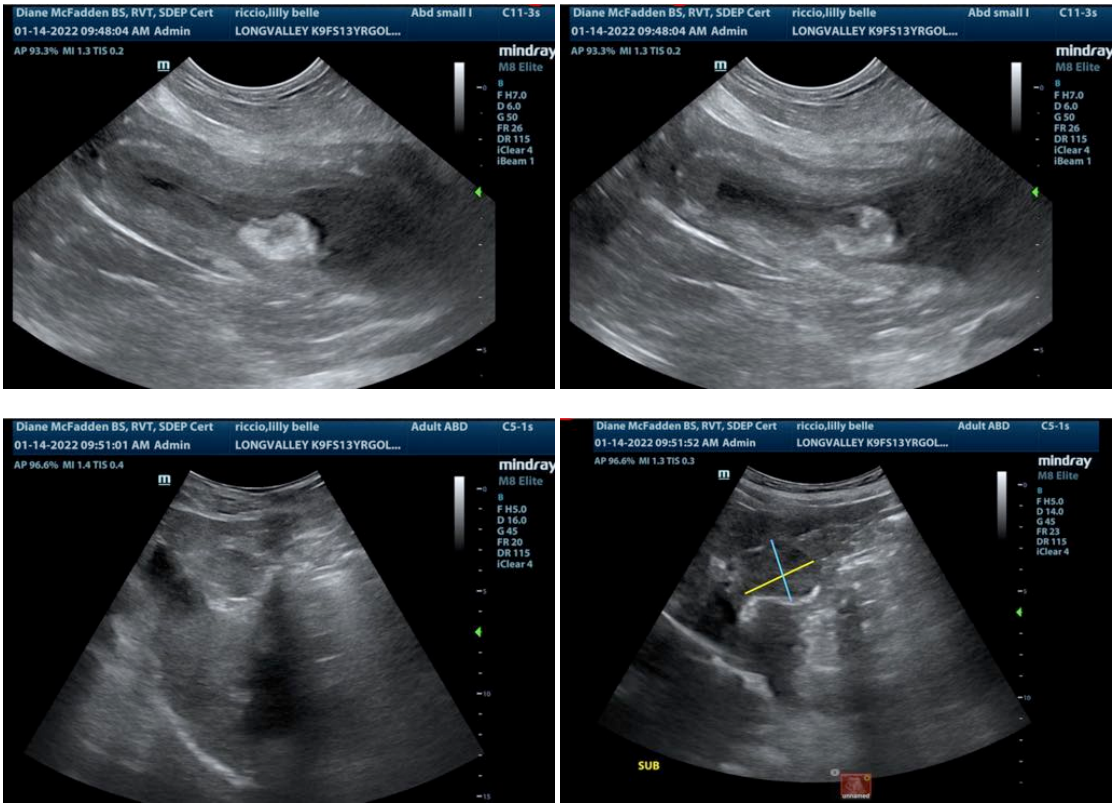

The information and recommendations provided are based on the images presented by the referring veterinarian. No evaluation can be communicated regarding pathology that was not visible in the image/video clips provided.

Thank you for this referral. If the clinical or image interpretation does not parallel your findings or if I can be of any further assistance please contact me.

Eric Lindquist, DMV, DABVP, Cert. IVUSS, CEO of SonoPath.com
Info@SonoPath.com

INTERPRETED BY

Eric Lindquist, DMV
DABVP, Cert. IVUSS

IMAGING PERFORMED BY

Diane McFadden, RVT

HOSPITAL NAME

Long Valley AH

INVOICE

95242

DATE

1/14/22