



**PATIENT PRESENTING CLINICAL SIGNS**

Harley Wolf Radiographs show possible abdominal mass; history of hematuria. No current meds. U/A: Elevated rods, USG: 1.027.

**SPECIES ULTRASONOGRAPHIC EXAMINATION OF THE ABDOMEN**

Canine

**Urinary System**

BREED

The **urinary bladder** revealed a polypoid mass that measured 2.27 x 0.78 cm. The mass and other polypoid changes appeared to derive from the ventral lateral wall and impinges upon the cystourethral junction. The mass is moderately vascular. No ureteral obstruction was noted at this point. However, the mass encompasses the area of the ureteral papillae. It may be resectable as the stock appears to be small. The pelvic urethra was imaged 3.0 cm beyond the cystourethral junction and was unremarkable.

Terrier

SEX

Spayed Female

The **kidneys** revealed largely normal size and structure, corticomedullary definition and ratio (cortex 1/3 of medulla) were essentially maintained with some age-related loss of curvilinear patterns regarding the capsule and C/M junction. The cortices presented largely uniform texture with some increased echogenicity expected for this age patient. Medullary structure differed distinctly from that of the cortex and no evidence of pelvic dilation was present. Mineralization was noted in the kidneys. The left kidney measured 5.92 cm.

AGE

12 years

WEIGHT

16 lbs

**Adrenal Glands**

INTERPRETED BY

Eric Lindquist, DMV  
DABVP, Cert. IVUSS

Both **adrenal glands** were visualized and recognized as having normal shape, size, position and echogenicity for this breed. The phrenic vasculature, glandular echogenicity and detail were unremarkable. Capsule, cortex, and medullary definition were normal for this age patient. The right adrenal gland measured 1.48 x 0.47 cm at the caudal pole and 0.46 cm at the cranial pole. The left adrenal gland measured 1.63 x 0.54 cm at the caudal pole and 0.56 cm at the cranial pole.

IMAGING PERFORMED BY

Kelly Vazquez, CVT

**Spleen**

HOSPITAL NAME

North Jersey AH

The **spleen** presented a smooth homogeneous parenchyma hyperechoic to liver and renal cortical parenchyma. The capsule was smooth without noticeable expansion or deviation from within the spleen or adjacent pathology. The splenic vasculature demonstrated normal volume without signs of congestion or thrombosis. No sonographic evidence of acute or chronic inflammatory, neoplastic, or infarctual changes was noted.

REFERRING VET

Dr. Reidel

**Liver**

INVOICE

95245

The **liver** images submitted revealed subjectively normal liver size, contour, and structure. Parenchymal echogenicity was naturally coarse and hypoechoic to the spleen. A hypoechoic nodule was noted in the mid liver and measured 0.96 x 0.58 cm and 1.42 x 1.27 cm at the cranial liver. Vascular and biliary tracts were of normal volume with no evidence of congestion. The gallbladder was mildly over distended with suspended and dependent debris, yet not to the level of emerging mucocele. However, the sludge appears to be mildly excessive. No adjunctive inflammation was noted.

DATE

1/13/22



**PATIENT**

**Gastrointestinal**

Harley Wolf

Examination of the **gastrointestinal tract** revealed a stomach and intestine free of stasis, of normal wall thickness, acceptable curvilinear mural detail, and peristaltic activity. Small and large intestine demonstrated normal luminal chyme and stool consistency respectively. No obstructive or overt infiltrative disease was noted. No associated abnormal lymphatic activity was noted.

**SPECIES**

Canine

**BREED**

Terrier

**Pancreas**

The base and limbs of the **pancreas** were observed to be largely isoechoic to surrounding omental fat. Pancreatic duct and capsular contour were acceptably normal and parenchyma respected normal curvilinear patterns. No overt evidence of active inflammatory or neoplastic disease was noted.

**SEX**

Spayed Female

**ULTRASONOGRAPHIC FINDINGS**

Ventral caudal bladder mass, potentially resectable.

**AGE**

12 years

Nodular liver changes.

Age related renal changes.

**WEIGHT**

16 lbs

**INTERPRETATION OF THE FINDINGS & FURTHER RECOMMENDATIONS**

The bladder mass is potentially resectable; however, space for closing the resection may be difficult. The cystourethral junction mass is polypoid and large vascular. The mass also encompasses transmural penetration into the wall, which would be suggestive for transitional cell carcinoma. There was no evidence of metastatic disease. Traumatic catheterization is recommended to confirm suspicion of transitional cell carcinoma or direct exploratory surgery can be considered. Eventual urethral stent placement could be placed if necessary.

**INTERPRETED BY**

Eric Lindquist, DMV  
DABVP, Cert. IVUSS

**IMAGING PERFORMED BY**

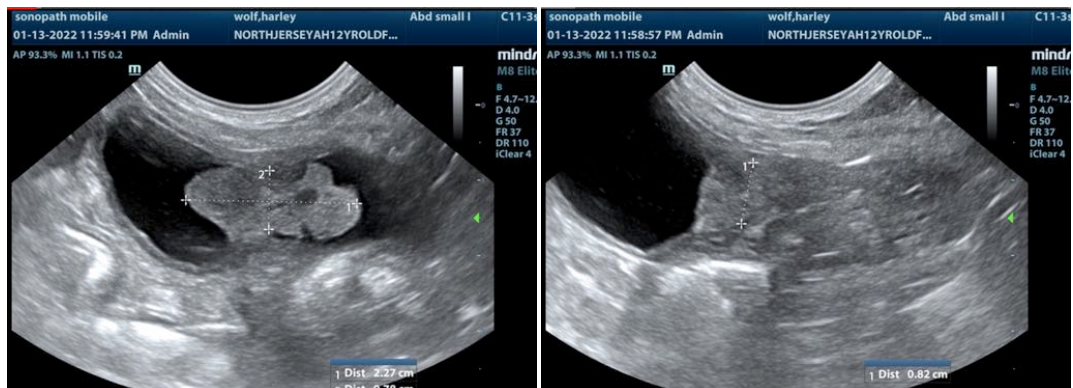
Kelly Vazquez, CVT

**HOSPITAL NAME**

North Jersey AH

**REFERRING VET**

Dr. Reidel



**INVOICE**

95245

**DATE**

1/13/22



**PATIENT**

Harley Wolf

**SPECIES**

Canine

**BREED**

Terrier

**SEX**

Spayed Female

**AGE**

12 years

**WEIGHT**

16 lbs

**INTERPRETED BY**

Eric Lindquist, DMV  
DABVP, Cert. IVUSS

**IMAGING PERFORMED BY**

Kelly Vazquez, CVT

**HOSPITAL NAME**

North Jersey AH

**REFERRING VET**

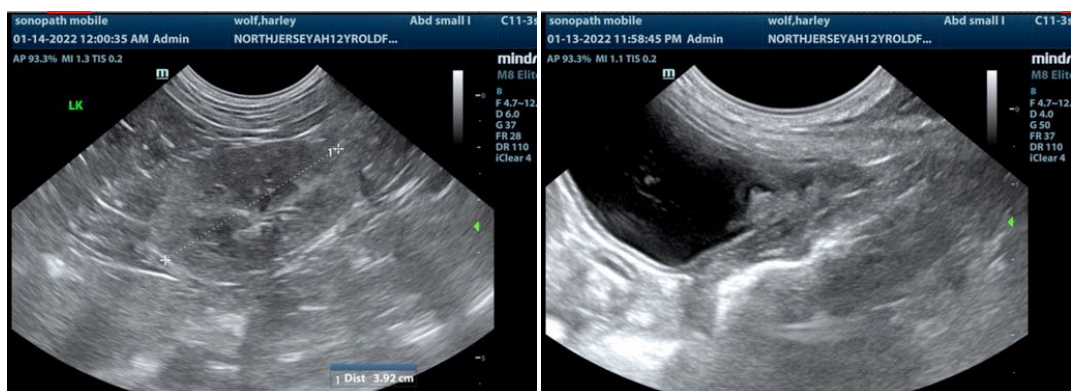
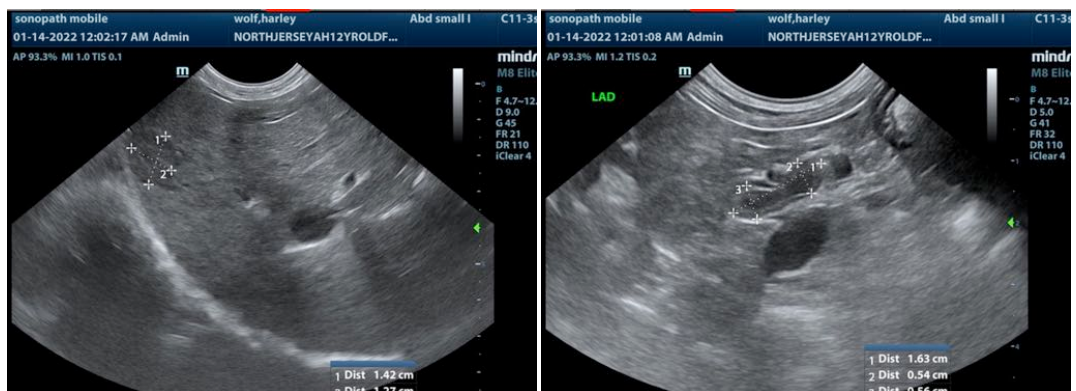
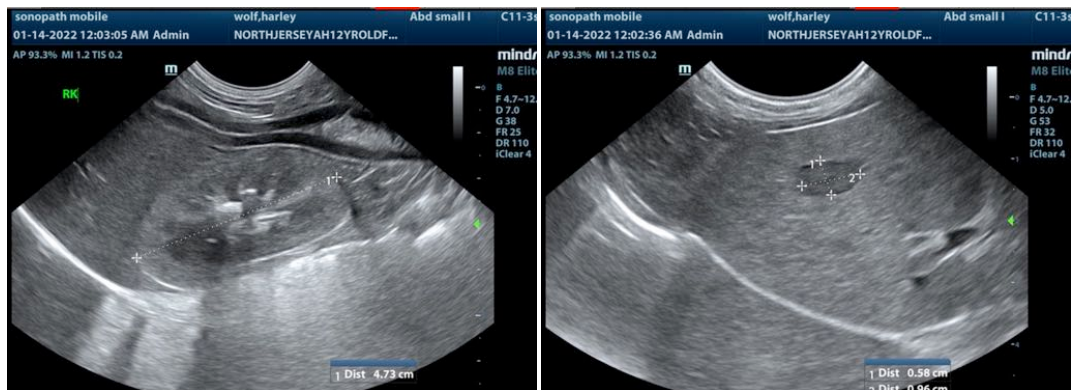
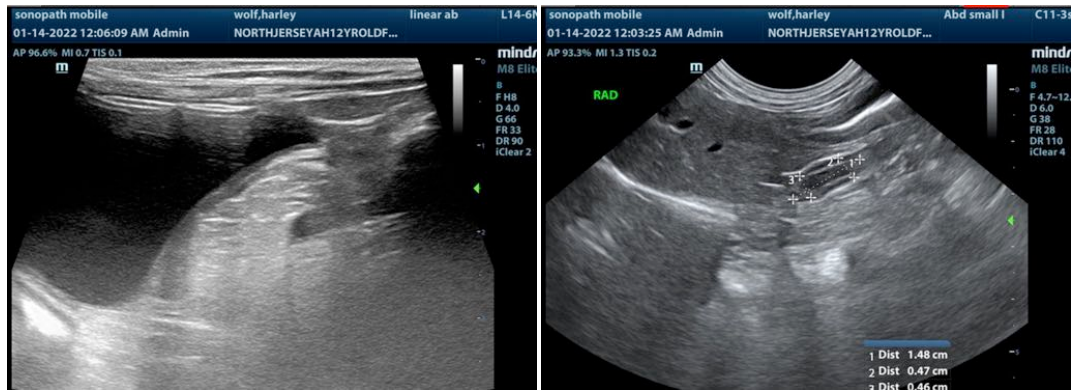
Dr. Reidel

**INVOICE**

95245

**DATE**

1/13/22





**PATIENT**

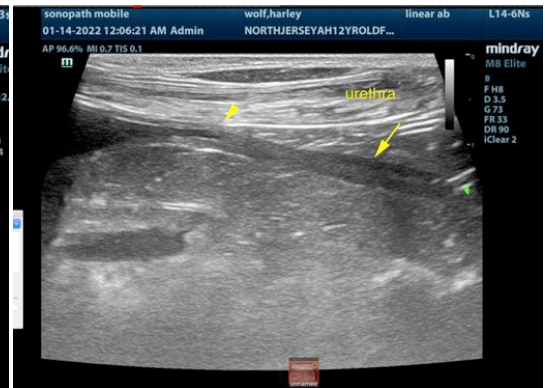
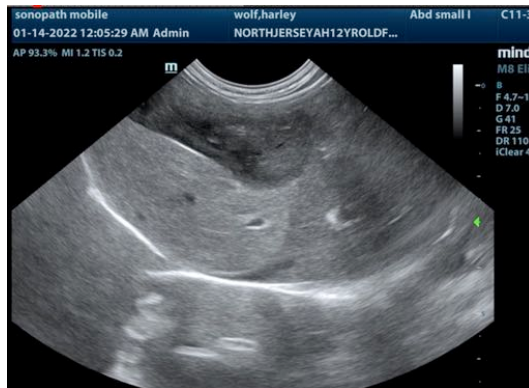Harley Wolf

**SPECIES**

Canine

**BREED**

Terrier



**SEX**

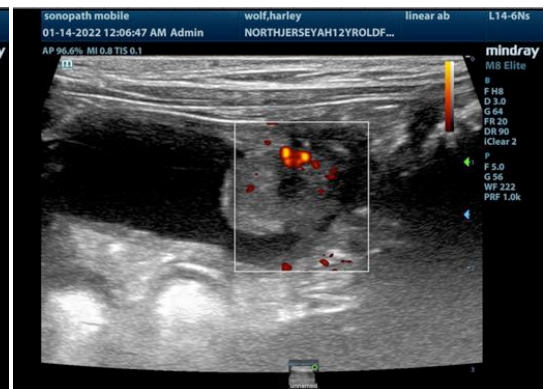
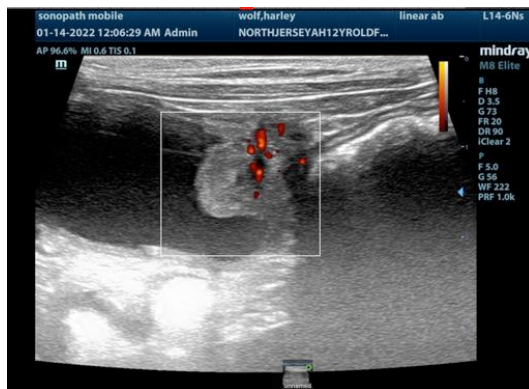Spayed Female

**AGE**

12 years

**WEIGHT**

16 lbs



**INTERPRETED BY**

Eric Lindquist, DMV  
DABVP, Cert. IVUSS

The information and recommendations provided are based on the images presented by the referring veterinarian. No evaluation can be communicated regarding pathology that was not visible in the image/video clips provided.

**IMAGING PERFORMED BY**

Kelly Vazquez, CVT

Thank you for this referral. If the clinical or image interpretation does not parallel your findings or if I can be of any further assistance please contact me.

Eric Lindquist, DMV, DABVP, Cert. IVUSS, CEO of SonoPath.com  
info@SonoPath.com

**HOSPITAL NAME**

North Jersey AH

**REFERRING VET**

Dr. Reidel

**INVOICE**

95245

**DATE**

1/13/22