



**PATIENT**

Chloe Kawaleuski

**PRESENTING CLINICAL SIGNS**

nausea, gagging, coughing, on enrofloxacin, sucralfate, ondansetron

**SPECIES**

Canine

**ULTRASONOGRAPHIC EXAMINATION OF THE ABDOMEN**

**Urinary System**

The **urinary bladder**, trigone, and pelvic urethra presented normal thicknesses and normal tone. The ureters were not visible which is normal. No uroliths or sediment were visualized and anechoic urine was present. No evidence of inflammatory or neoplastic changes were noted. Ureteral papillae were normal.

**BREED**

Mixed

**SEX**

Spayed Female

The **kidneys** revealed normal size and structure, corticomedullary definition and ratio for this age. The cortices presented largely uniform texture with normal echogenic relationship to liver and spleen. Medullary structure differed distinctly from the cortex and no evidence of pelvic dilation was present. The capsules were acceptably uniform without significant irregularities. The right kidney measured 5.11 cm. The left kidney measured 5.38 cm.

**AGE**

8 Years

**Adrenal Glands**

Both **adrenal glands** were visualized and recognized as having normal shape, size, position and echogenicity for this breed. The phrenic vasculature, glandular echogenicity and detail were unremarkable. Capsule, cortex, and medullary definition were normal for this age patient. The left adrenal gland measured 2.27 cm x 0.53 cm at the caudal pole and 0.31 cm at the cranial pole. The right adrenal gland measured 2.98 cm x 0.42 cm at the caudal pole and 0.94 cm at the cranial pole.

**WEIGHT**

38 Pounds

**Spleen**

The **spleen** presented a smooth homogeneous parenchyma hyperechoic to liver and renal cortical parenchyma. The spleen was folded upon itself cranially. The capsule was smooth without noticeable expansion or deviation from within the spleen or adjacent pathology. The splenic vasculature demonstrated normal volume without signs of congestion or thrombosis. No sonographic evidence of acute or chronic inflammatory, neoplastic, or infarctual changes were noted.

**INTERPRETED BY**

Eric Lindquist, DMV  
DABVP, Cert. IVUSS

**Liver**

The **liver** images submitted revealed subjectively normal liver size, contour, and structure. Parenchymal echogenicity was naturally coarse and hypoechoic to the spleen. Vascular and biliary tracts were of normal volume with no evidence of congestion. Minor gallbladder debris noted.

**IMAGING PERFORMED BY**

Diane McFadden

**HOSPITAL NAME**

North Warren AH

**Gastrointestinal**

The **stomach** revealed a progressively shadowing structure measuring 2.82 cm. The small intestine and colon were unremarkable.

**REFERRING VET**

Dr. Corrado

**Pancreas**

The base and limbs of the **pancreas** were observed to be largely isoechoic to surrounding omental fat. Pancreatic duct and capsular contour were acceptably normal and parenchyma respected normal curvilinear patterns. No overt evidence of active inflammatory or neoplastic disease was noted.

**INVOICE**

34228

**ULTRASONOGRAPHIC FINDINGS**

**DATE**

1/14/22

- Shadowing gastric structure, non-obstructive



**PATIENT**

Chloe Kawaleuski

**INTERPRETATION OF THE FINDINGS & FURTHER RECOMMENDATIONS**

If the patient was NPO at the time of the sonogram, gastrotomy would be warranted.

**SPECIES**

Canine

**BREED**

Mixed

**SEX**

Spayed Female

**AGE**

8 Years

**WEIGHT**

38 Pounds

**INTERPRETED BY**

Eric Lindquist, DMV  
DABVP, Cert. IVUSS

**IMAGING PERFORMED BY**

Diane McFadden

**HOSPITAL NAME**

North Warren AH

**REFERRING VET**

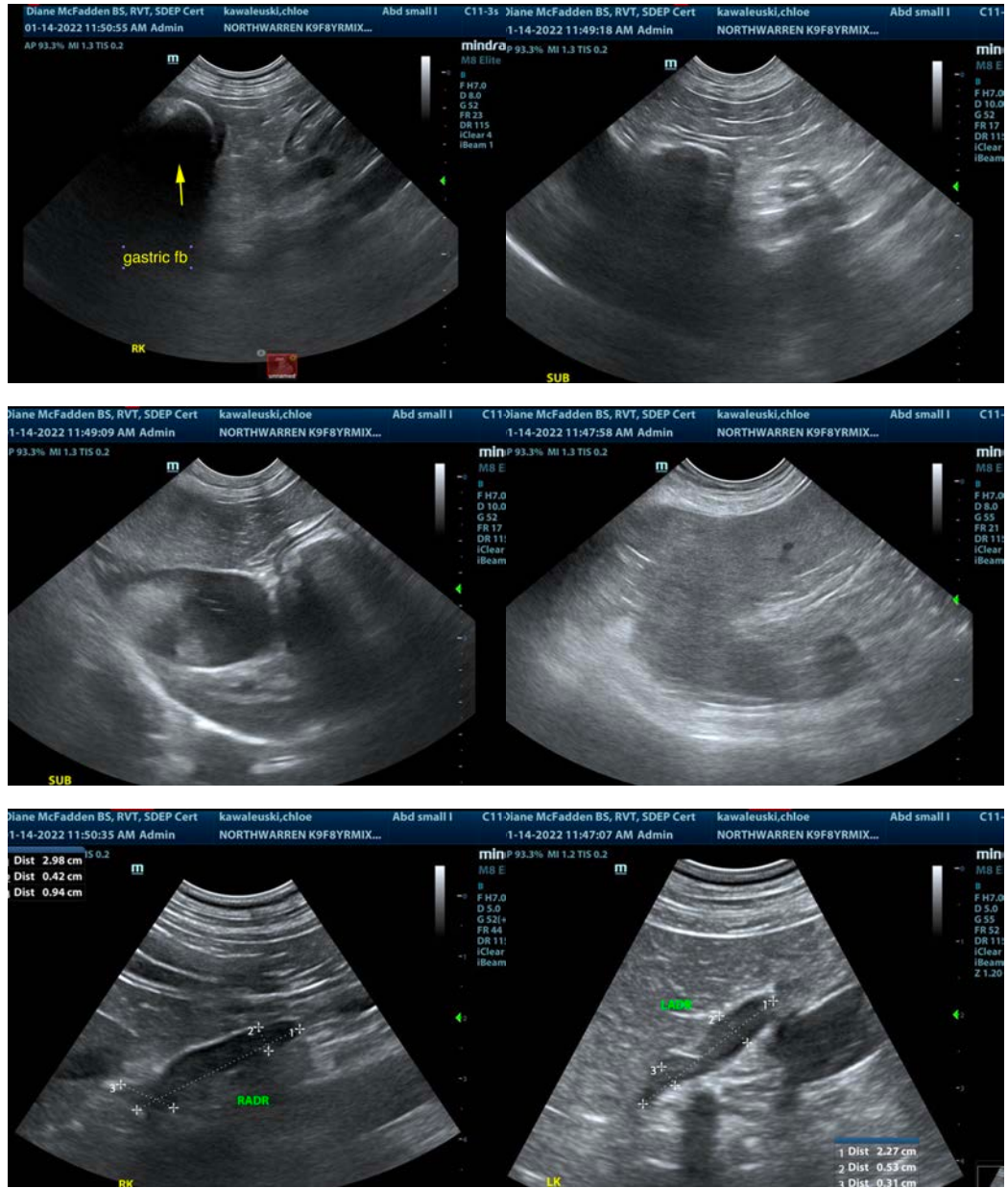
Dr. Corrado

**INVOICE**

34228

**DATE**

1/14/22





**PATIENT**

Chloe Kawaleuski

**SPECIES**

Canine

**BREED**

Mixed

**SEX**

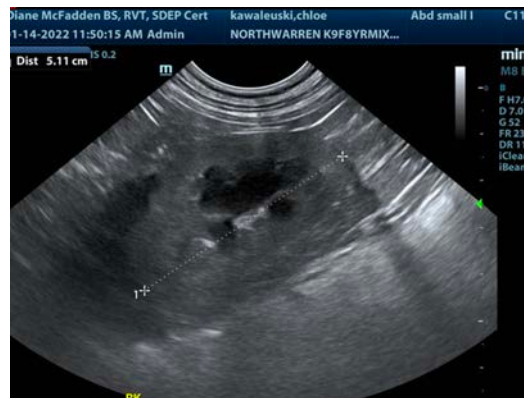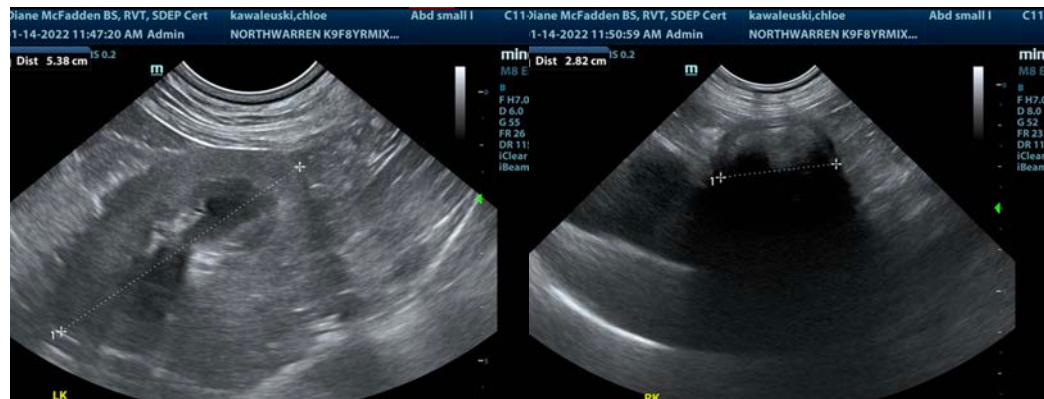
Spayed Female

**AGE**

8 Years

**WEIGHT**

38 Pounds



**INTERPRETED BY**

Eric Lindquist, DMV  
DABVP, Cert. IVUSS

The information and recommendations provided are based on the images presented by the referring veterinarian. No evaluation can be communicated regarding pathology that was not visible in the image/video clips provided.

**IMAGING PERFORMED BY**

Diane McFadden

Thank you for this referral. If the clinical or image interpretation does not parallel your findings or if I can be of any further assistance please contact me.

**HOSPITAL NAME**

North Warren AH

**Eric Lindquist**, DMV, DABVP, Cert. IVUSS, CEO of SonoPath.com  
[info@SonoPath.com](mailto:info@SonoPath.com)

**REFERRING VET**

Dr. Corrado

**INVOICE**

34228

**DATE**

1/14/22