



**PATIENT**

China McMannus

**PRESENTING CLINICAL SIGNS**

Pre-sx echo for dental. Grade III/VI murmur. Coughs in am. Current meds: Clavamox  
Abnormal PE/Chem/CBC/UA Results: Borderline elevated bun/creat. USG 1.023, UTI

**SPECIES**

Canine

**ULTRASONOGRAPHIC EXAMINATION OF THE HEART**

**BREED**

Pitbull Mix

The echocardiogram in this patient demonstrated normal **left atrial** size based on 3 different LA measurement methods. Chamber volumes and echogenicity were normal. The cranial and caudal **mitral** valve leaflets presented vegetative thickening consistent with endocardiosis. Doppler indicated measurable insufficiency. Complete filling of the left atrium was noted on color flow Doppler of the mitral valve. The **left ventricle** presented thicknesses with linear contour and was not dilated nor restricted. The **myocardium** presented normal echogenicity without subjective evidence of significant fibrotic or ischemic disease. **Contractility** of the ventricular walls was adequate and in normal range for this patient evidenced by the fractional shortening measurement and subjective evaluation of the different regions of the myocardium. The **left ventricular outflow** tract demonstrated normal laminar flow and subjective structural integrity. The **right atrium** and auricle revealed normal size, structure and content. No evidence of masses was noted or chamber overload. **Tricuspid** valvular assessment demonstrated adequate linear morphology. The **right ventricle** was of normal size (1/3 diameter of LV), chordae structure, myocardial echogenicity and thickness. **Pulmonic** tract assessment revealed normal valve structure, laminar flow, and diameter (approx. 1:1 pa/ao ratio). No visible **pericardial** or free pleura fluid was noted. No echographically detectable evidence of infiltrative disease was visible. The cranial **mediastinum** and **pericardial** regions were free of masses in the visible window.

**SEX**

Spayed Female

**AGE**

14 years

**WEIGHT**

-

**INTERPRETED BY**

Eric Lindquist, DMV  
DABVP, Cert. IVUSS

CANINE CARDIAC PARAMETERS	MR VMAX (m/s)	TR VMAX (m/s)	LA/AO (Boon method)	LA/AO (Heart Base; Swe)	FS (%)	EF (%)	EPSS (cm)
NORMAL PARAMETER	4.5-5.5	<2.7	1.3	<1.6	28-40	40-100	<0.6
PATIENT	5.33	2.51	1.35	1.3	29	57	NM
CANINE CARDIAC PARAMETERS	HR (BPM)	AV VMAX (m/s)	PV MAX (m/s)	BODY WEIGHT (kg)	LA 2D short axis Base view (cm)	LVIDd Avg; 2D and m- mode short axis (cm)	LVIDs Avg; 2D and m- mode short axis (cm)
NORMAL PARAMETER	50-100	0.7-1.7	0.7-1.6				
PATIENT	133	1.0	0.56		4.32	3.96	

**IMAGING  
PERFORMED BY**

Shari Reffi, CVT

**HOSPITAL NAME**

Parsippany Troy Hills  
AH

**REFERRING VET**

Dr. Dulude

**INVOICE**

95247

**DATE**

1/14/22

**ULTRASONOGRAPHIC FINDINGS**

Stage B1 valvular disease.

Mitral and tricuspid insufficiency, compensated.



**PATIENT**

China McMannus

**SPECIES**

Canine

**BREED**

Pitbull Mix

**SEX**

Spayed Female

**AGE**

14 years

**WEIGHT**

-

**INTERPRETED BY**

Eric Lindquist, DMV  
DABVP, Cert. IVUSS

**IMAGING PERFORMED BY**

Shari Reffi, CVT

**HOSPITAL NAME**

Parsippany Troy Hills  
AH

**REFERRING VET**

Dr. Dulude

**INVOICE**

95247

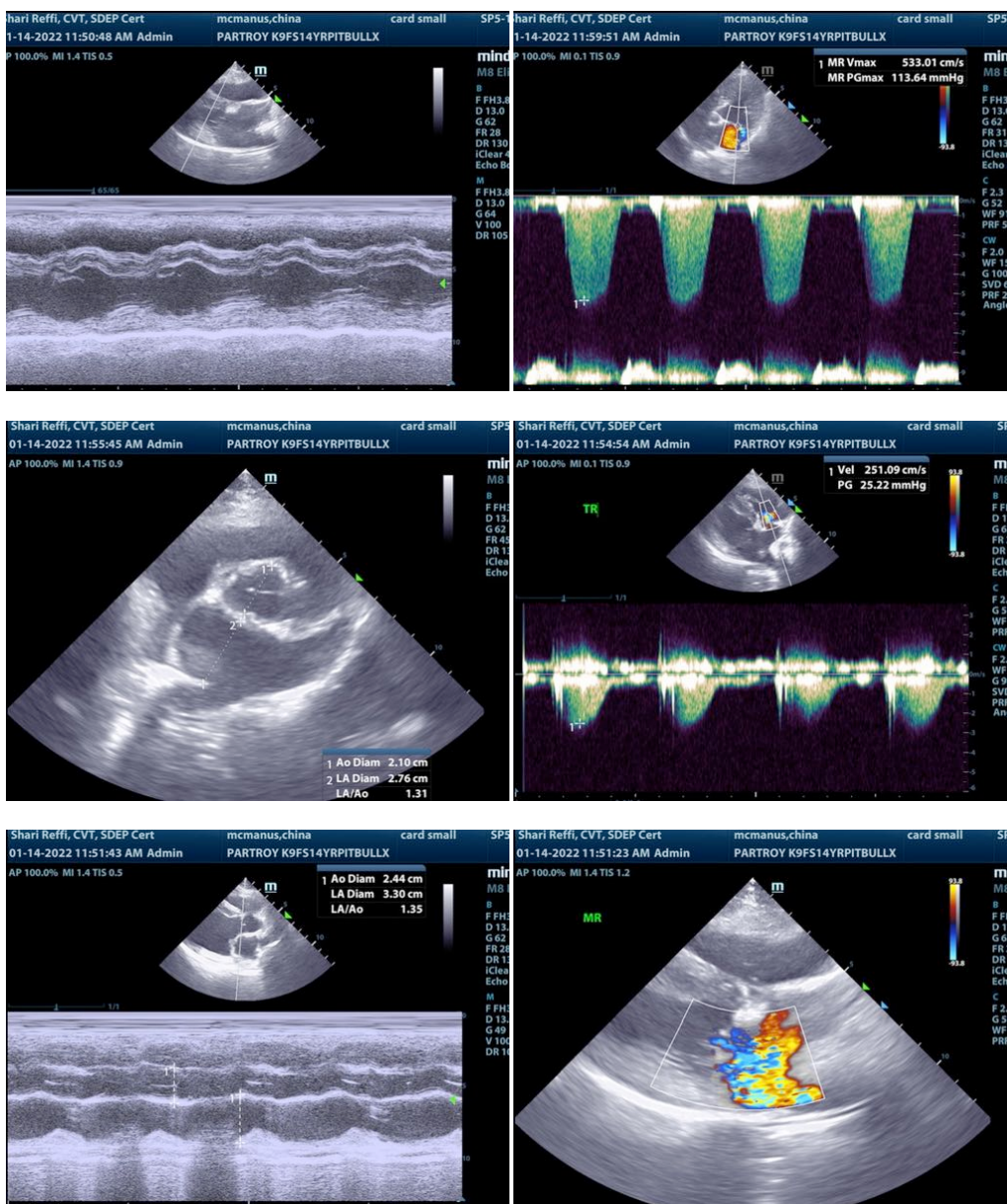
**DATE**

1/14/22

**INTERPRETATION OF THE FINDINGS & FURTHER RECOMMENDATIONS**

There was no significant evidence of volume overload.

B1: The heart is stable without clinical disease. No overt contraindication for anesthesia of brief to moderate duration. I suggest Torbutrol premed, Propofol induction, Isoflurane maintenance or similar protocol if anesthesia is desired. Blood pressure recommended if not already performed and target white coat negative systolic pressure of < 160 mmHg. If higher than this ACE-inhibitor is suggested to reach this level. Recheck echocardiogram is recommended in 6 months, earlier if murmur grade increases or clinical signs initiate.





**PATIENT**

China McManus

**SPECIES**

Canine

**BREED**

Pitbull Mix

**SEX**

Spayed Female

**AGE**

14 years

**WEIGHT**

-

**INTERPRETED BY**

Eric Lindquist, DMV  
DABVP, Cert. IVUSS

**IMAGING PERFORMED BY**

Shari Reffi, CVT

**HOSPITAL NAME**

Parsippany Troy Hills  
AH

**REFERRING VET**

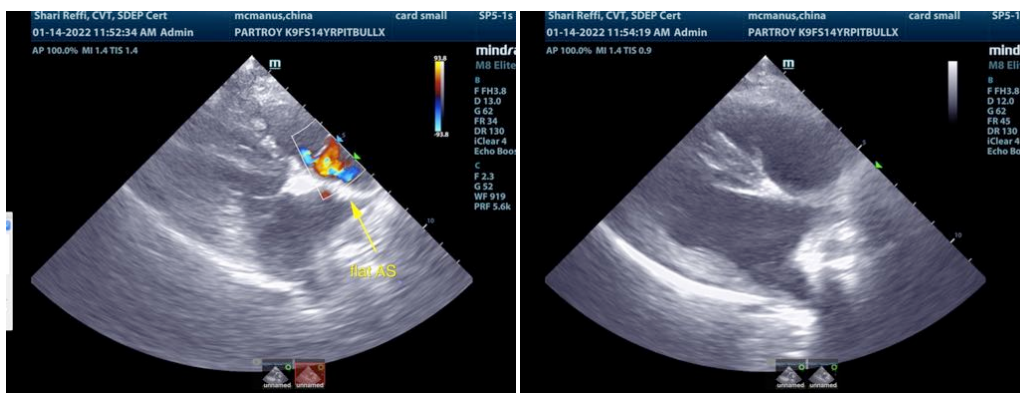
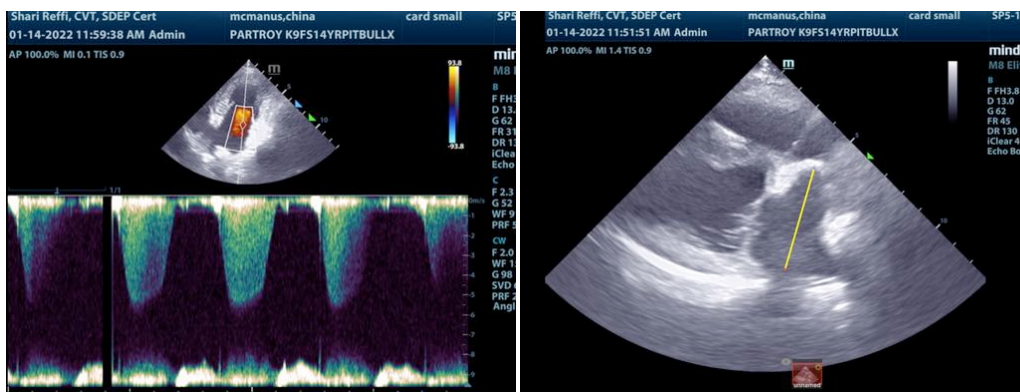
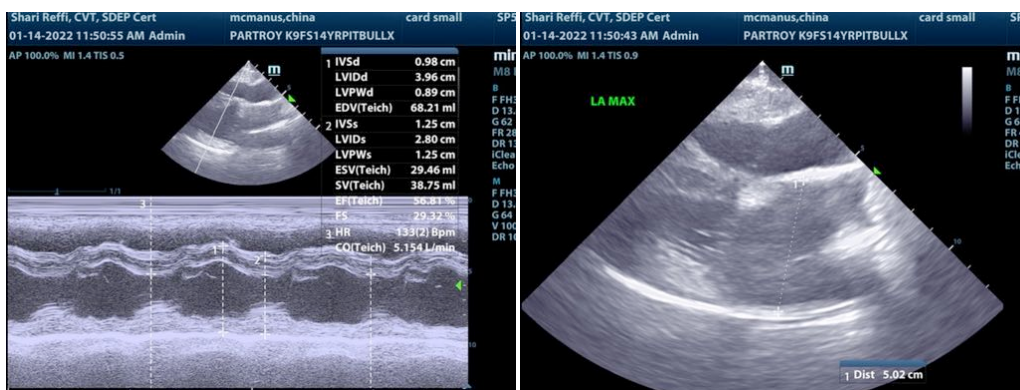
Dr. Dulude

**INVOICE**

95247

**DATE**

1/14/22



The information and recommendations provided are based on the images presented by the referring veterinarian. No evaluation can be communicated regarding pathology that was not visible in the image/video clips provided.

Thank you for this referral. If the clinical or image interpretation does not parallel your findings or if I can be of any further assistance please contact me.

Eric Lindquist, DMV, DABVP, Cert. IVUSS, CEO of SonoPath.com  
Info@SonoPath.com