


DATE
 1/14/22

PRESENTING CLINICAL SIGNS

History: p present for advanced dental needing extractions. pre-op bloodwork revealed ALT elevation. Bloodwork from 9/2020 normal. PE unremarkable.

PATIENT

Bailey McGreevy

Current Medications: Denamarin 225mg PO SID.
 Lab Results: ALT 440, Bile Acids pre-7.9, Post 44.4.
 Date of Previous IntraPet Ultrasound: No previous IntraPet scans.
 Sedation: Not required to complete full diagnostic ultrasound.
 Stat Report: Not requested.
 Imaging Performed By: Stephanie Pearce RDCS, RVT.

SPECIES

Canine

BREED

Miniature Poodle

ULTRASONOGRAPHIC EXAMINATION OF THE ABDOMEN
SEX

Neutered Male

Urinary System

The **urinary bladder**, trigone, and pelvic urethra presented normal thicknesses and normal tone. The ureters were not visible which is normal. No uroliths or sediment were visualized and anechoic urine was present. No evidence of inflammatory or neoplastic changes were noted. Ureteral papillae were normal.

AGE

3/25/10

The **kidneys** revealed normal size and structure, corticomedullary definition and ratio for this age. The cortices presented largely uniform texture with normal echogenic relationship to liver and spleen. Medullary structure differed distinctly from the cortex and no evidence of pelvic dilation was present. The capsules were acceptably uniform without significant irregularities. The right kidney measured 4.17 cm. The left kidney measured 3.9 cm.

WEIGHT

13.1 Lbs.

Adrenal Glands

Both **adrenal glands** were visualized and recognized as having normal shape, size, position and echogenicity for this breed. The phrenic vasculature, glandular echogenicity and detail were unremarkable. Capsule, cortex, and medullary definition were normal for this age patient. The right adrenal gland measured 1.62 cm x 0.42 cm at the caudal pole and 0.52 cm at the cranial pole. The left adrenal gland measured 1.78 cm x 0.52 cm at the caudal pole and 0.59 cm at the cranial pole.

INTERPRETED BY
Eric Lindquist, DMV
DABVP, Cert. IVUSS
Spleen

The **spleen** presented a smooth homogeneous parenchyma hyperechoic to liver and renal cortical parenchyma. The capsule was smooth without noticeable expansion or deviation from within the spleen or adjacent pathology. The splenic vasculature demonstrated normal volume without signs of congestion or thrombosis. No sonographic evidence of acute or chronic inflammatory, neoplastic, or infarctual changes were noted.

HOSPITAL NAME

Northwind AH

REFERRING VET

Dr. Cross

Liver

The **liver** images submitted revealed subjectively normal liver size, contour, and structure. Parenchymal echogenicity was naturally coarse and hypoechoic to the spleen. Vascular and biliary tracts were of normal volume with no evidence of congestion. The gallbladder presented acceptably thin walls with primarily anechoic content. The cystic and common bile ducts were normal. No pathological hepatic lymphadenopathy was evident. No overt structural evidence of inflammatory, infiltrative or regenerative pathology was evident. The portal vein to vena cava ratio was 1:1. No evidence of intrahepatic or extrahepatic shunting.

INVOICE

13450

Gastrointestinal

The **stomach** was filled with ingesta. The small intestine and colon were unremarkable.

Pancreas

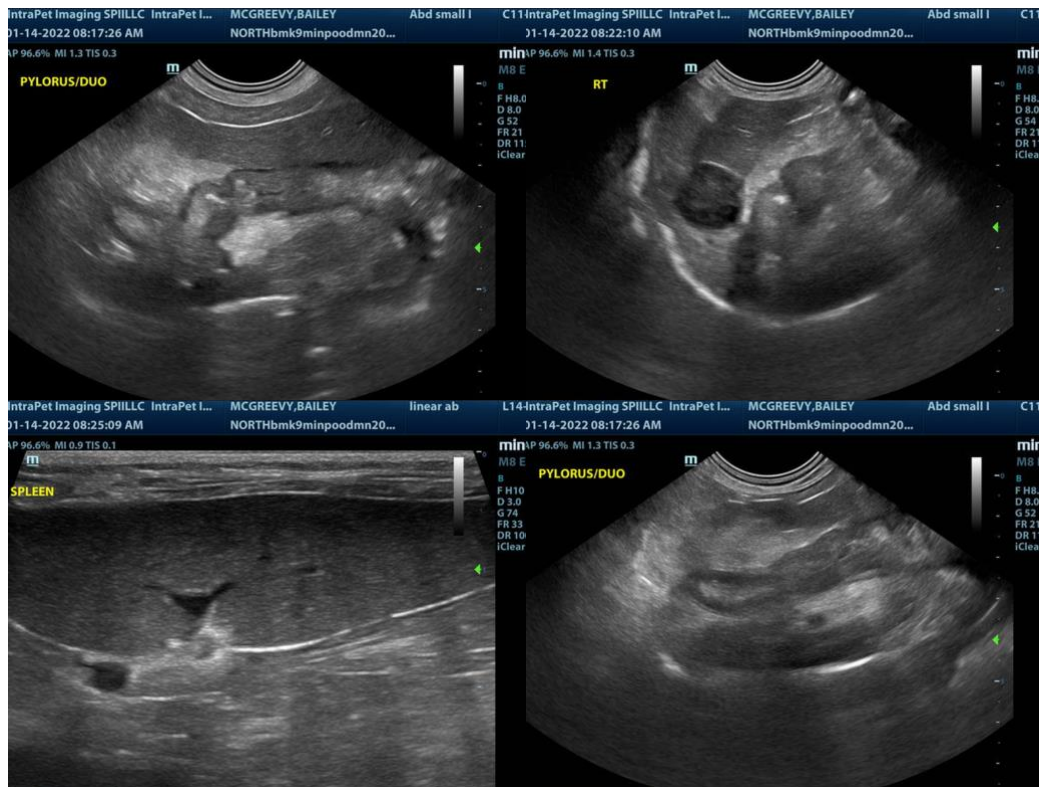
Minor heterogeneous **pancreatic** changes noted.

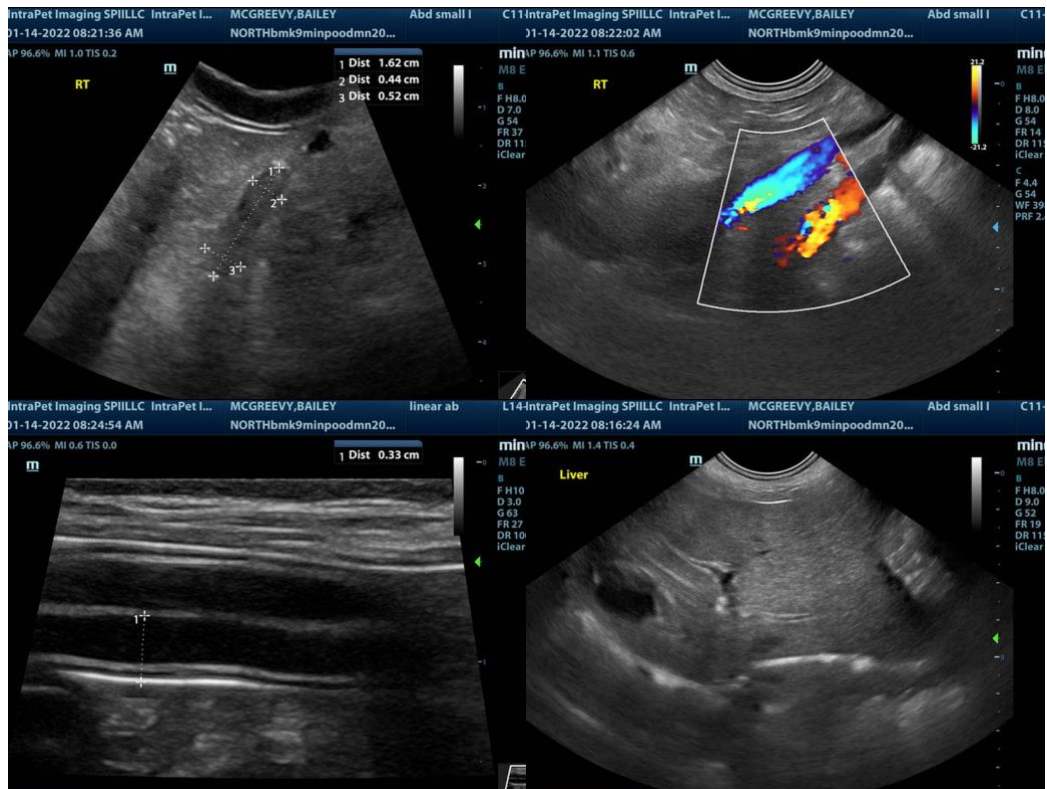
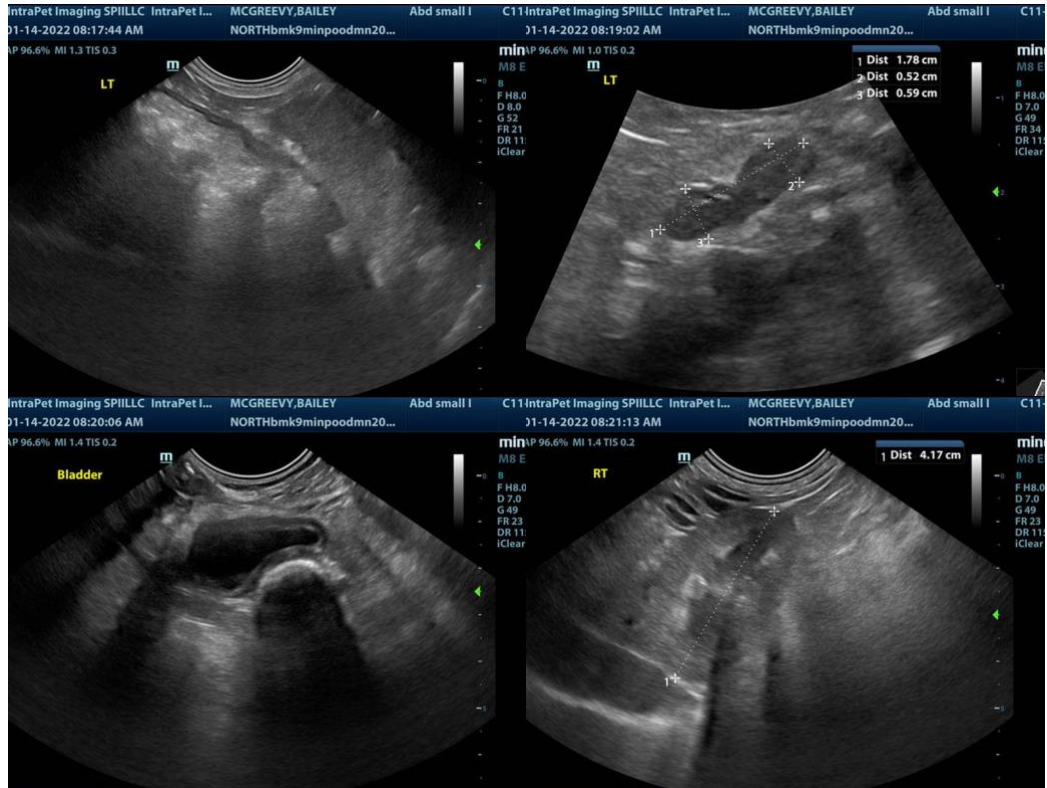
ULTRASONOGRAPHIC FINDINGS

- Structurally normal liver. Nonspecific inflammatory hepatopathy likely.
- Minor retention of ingesta in the stomach
- Heterogeneous pancreatic changes

INTERPRETATION OF THE FINDINGS & FURTHER RECOMMENDATIONS

FNA of the liver could be considered for further definition. Spurious elevation of the bile acids may be an issue in this patient. Portal hypoplasia possible, however, structurally the liver is unremarkable, including normal size. Resolving pancreatitis may be an inciting event for the inflammatory hepatopathy/reactive hepatopathy presentation. Ampicillin/Metronidazole combination, hepatic support diet would be appropriate and reassessment of the clinical signs.





The information and recommendations provided are based on the images presented by the referring veterinarian. No evaluation can be communicated regarding pathology that was not visible in the image/video clips provided.

Thank you for this referral. If the clinical or image interpretation does not parallel your findings or if I can be of any further assistance please contact me.

Eric Lindquist, DMV, DABVP, Cert. IVUSS, CEO of SonoPath.com
Eric.Lindquist@SonoPath.com