



PATIENT

Maya Bradley

SPECIES

Canine

BREED

Husky

SEX

Spayed female

AGE

4 years

WEIGHT

54.8 lbs

INTERPRETED BY

Eric Lindquist, DMV
DABVP, Cert. IVUSS

IMAGING PERFORMED BY

Breanna Wokatsch

HOSPITAL NAME

Underdog Pet Rescue

REFERRING VET

Dr. Wokatsch

INVOICE

70095

DATE

1/13/26

PRESENTING CLINICAL SIGNS

History: Patient presented as a referral from their pDVM for an abdominal ultrasound due to repeat episodes of hematuria. No stones seen on abdominal radiographs (per pDVM). Patient has had multiple urinary tract infections and struvite crystals in the past.

Abnormal PE/Chem/CBC/UA Results: Patient's current examination is within normal limits.

ULTRASONOGRAPHIC EXAMINATION OF THE ABDOMEN

Urinary System

The **urinary bladder**, trigone, and pelvic urethra presented normal thicknesses and normal tone. The pelvic urethra was imaged 3.0 cm beyond the cystourethral junction and appeared normal. The ureters were not visible which is normal. A large calculus was noted and measured 2.5 cm with mild suspended debris noted. No evidence of inflammatory or neoplastic changes was noted. Ureteral papillae were normal.

The **kidneys** revealed normal size and structure, corticomedullary definition and ratio for this age. The cortices presented largely uniform texture with normal echogenic relationship to liver and spleen. Medullary structure differed distinctly from the cortex and no evidence of pelvic dilation was present. The capsules were acceptably uniform without significant irregularities. The left kidney measured 6.3 cm. The right kidney measured 4.75 cm with slight pinpoint mineralization.

Adrenal Glands

Both **adrenal glands** were visualized and recognized as having normal shape, size, position and echogenicity for this breed. The phrenic vasculature, glandular echogenicity and detail were unremarkable. Capsule, cortex, and medullary definition were normal for this age patient.

Spleen

The **spleen** presented a smooth homogeneous parenchyma hyperechoic to liver and renal cortical parenchyma. The capsule was smooth without noticeable expansion or deviation from within the spleen or adjacent pathology. The splenic vasculature demonstrated normal volume without signs of congestion or thrombosis. No sonographic evidence of acute or chronic inflammatory, neoplastic, or infarctual changes was noted.

Liver

The **liver** images submitted revealed subjectively normal liver size, contour, and structure. Parenchymal echogenicity was naturally coarse and hypoechoic to the spleen. Vascular and biliary tracts were of normal volume with no evidence of congestion. The gallbladder presented acceptably thin walls with primarily anechoic content. The cystic and common bile ducts were normal. No pathological hepatic lymphadenopathy was evident. No overt structural evidence of inflammatory, infiltrative or regenerative pathology was evident.



PATIENT

Maya Bradley

SPECIES

Canine

BREED

Husky

SEX

Spayed female

AGE

4 years

WEIGHT

54.8 lbs

INTERPRETED BY

Eric Lindquist, DMV
DABVP, Cert. IVUSS

IMAGING PERFORMED BY

Breanna Wokatsch

HOSPITAL NAME

Underdog Pet Rescue

REFERRING VET

Dr. Wokatsch

INVOICE

70095

DATE

1/13/26

Gastrointestinal

Examination of the **gastrointestinal tract** revealed a stomach and intestine free of stasis, of normal wall thickness, acceptable curvilinear mural detail, and peristaltic activity. Small and large intestine demonstrated normal luminal chyme and stool consistency respectively. No obstructive or overt infiltrative disease was noted. No associated abnormal lymphatic activity was noted.

Pancreas

The base and limbs of the **pancreas** were observed to be largely isoechoic to surrounding omental fat. Pancreatic duct and capsular contour were acceptably normal and parenchyma respected normal curvilinear patterns. No overt evidence of active inflammatory or neoplastic disease was noted.

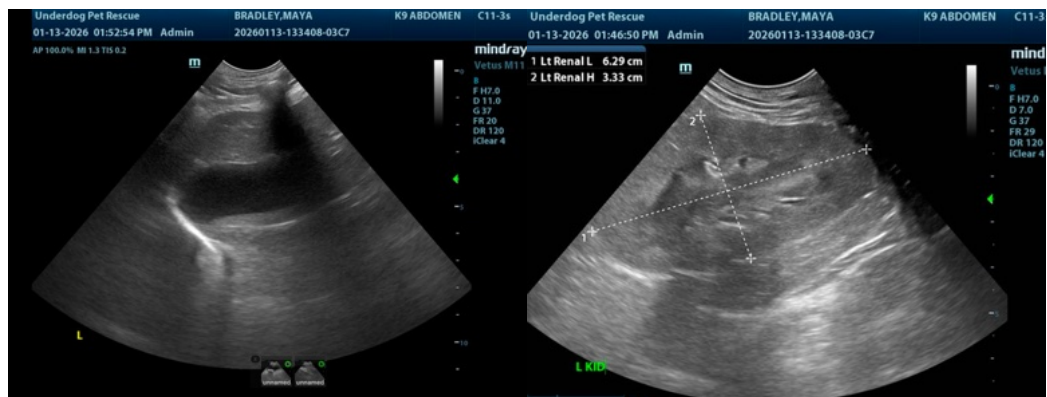ULTRASONOGRAPHIC FINDINGS

Bladder calculus.

Slight renal pinpoint mineralization.

INTERPRETATION OF THE FINDINGS & FURTHER RECOMMENDATIONS

Cystotomy, stone analysis and culture are indicated.





PATIENT

Maya Bradley

SPECIES

Canine

BREED

Husky

SEX

Spayed female

AGE

4 years

WEIGHT

54.8 lbs

INTERPRETED BY

Eric Lindquist, DMV
DABVP, Cert. IVUSS

IMAGING PERFORMED BY

Breanna Wokatsch

HOSPITAL NAME

Underdog Pet Rescue

REFERRING VET

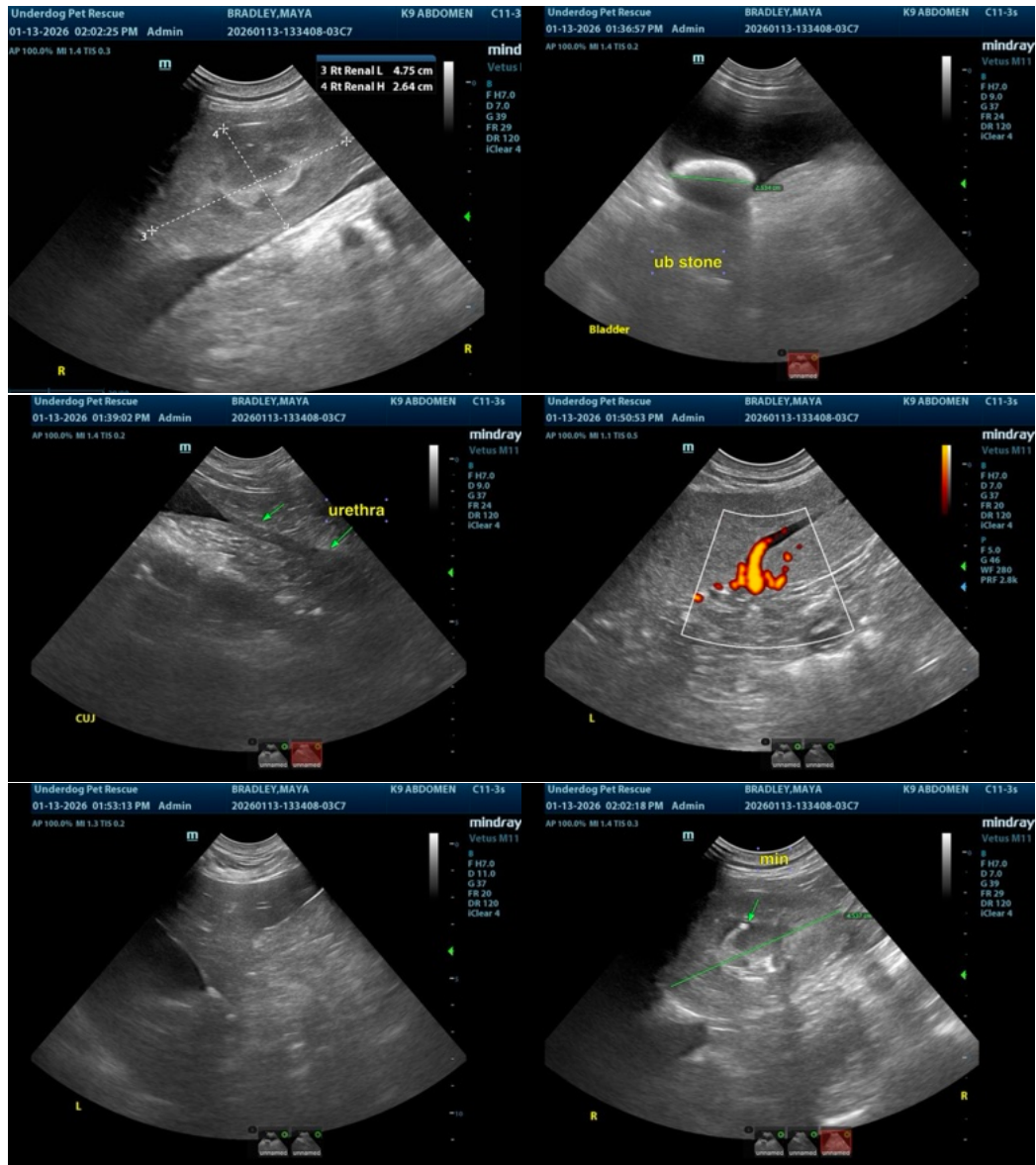
Dr. Wokatsch

INVOICE

70095

DATE

1/13/26



The information and recommendations provided are based on the images presented by the referring veterinarian/sonographer. No evaluation can be communicated regarding pathology that was not visible in the image/video clips provided.

Thank you for this referral. If the clinical or image interpretation does not parallel your findings or if I can be of any further assistance please contact me.

Eric Lindquist, DMV, DABVP (CFM), Cert. IVUSS, CEO of SonoPath.com

info@SonoPath.com