



PATIENT

Louie Bolkema

SPECIES

Feline

BREED

DSH

SEX

Neutered Male

AGE

16 Years 9 Months

WEIGHT

11.4

INTERPRETED BY

Eric Lindquist, DMV,
 DABVP (CFM), Cert.
 IVUSS

IMAGING PERFORMED BY

Vincent Ravancho, CVT

HOSPITAL NAME

Ramapo Valley AH

REFERRING VET

Dr. Katara

INVOICE

35368

DATE

1/12/26

PRESENTING CLINICAL SIGNS

History: Neoplasia check Clinical findings: Had echo 12/11 and heart is ok. Atelectasis in lungs and mild cough; this is persistent. Has been on clavamox w/ pradofloxacin, convenia, doxycycline, Primary neoplasia as cause?

ULTRASONOGRAPHIC EXAMINATION OF THE ABDOMEN

Urinary System

The **urinary bladder**, trigone, and pelvic urethra presented normal thicknesses and normal tone. The ureters were not visible which is normal. No uroliths or sediment were visualized and anechoic urine was present. No evidence of inflammatory or neoplastic changes was noted. Ureteral papillae were normal. The pelvic urethra was imaged 2.0 cm beyond the cystourethral junction.

The **kidneys** revealed largely normal size and structure, corticomedullary definition and ratio (cortex 1/3 of medulla) were essentially maintained with some minor age-related loss of curvilinear patterns regarding the capsule and C/M junction. The cortices presented largely uniform texture with some increased echogenicity expected for this age patient. Medullary structure differed distinctly from that of the cortex, and no evidence of pelvic dilation was present. The left kidney measured 4.16 cm. The right kidney measured 4.43 cm.

Adrenal Glands

Both **adrenal glands** were visualized and recognized as having normal shape, size, position and echogenicity for this breed. The phrenic vasculature, glandular echogenicity and detail were unremarkable. Capsule, cortex, and medullary definition were normal for this age patient. The right adrenal gland measured 0.56 cm. The left adrenal gland measured 0.34 cm.

Spleen

The **spleen** presented a smooth homogeneous parenchyma hyperechoic to liver and renal cortical parenchyma. The capsule was smooth without noticeable expansion or deviation from within the spleen or adjacent pathology. The splenic vasculature demonstrated normal volume without signs of congestion or thrombosis. Slight hyperechoic lipid plaques noted in the spleen.

Liver

The **liver** images from right and left intercostal as well as subcostal views revealed subjectively normal liver size, contour, and structure. Some minor age-related parenchymal remodeling was noted but likely not clinically significant at this time. Vascular and biliary tracts were of normal volume, and no evidence of congestion was noted. The gallbladder presented some dependent debris with essentially normal contour. The cystic and common bile ducts were normal. No overt evidence of active inflammatory, infiltrative or regenerative pathology was noted but should be paired with current or past LE elevations regarding any clinical significance to this presentation. The hepatic lymph nodes were unremarkable.

Gastrointestinal



PATIENT

Louie Bolkema

SPECIES

Feline

BREED

DSH

SEX

Neutered Male

AGE

16 Years 9 Months

WEIGHT

11.4

INTERPRETED BY

Eric Lindquist, DMV,
DABVP (CFM), Cert.
IUUSS

IMAGING PERFORMED BY

Vincent Ravancho, CVT

HOSPITAL NAME

Ramapo Valley AH

REFERRING VET

Dr. Katara

INVOICE

35368

DATE

1/12/26

The **gastrointestinal tract** revealed minor variable thickening and echogenic submucosal changes most consistent with low grade end result of chronic GI disease such as IBD and may be related to malassimilation of nutrients if any weight loss is present. No obvious neoplastic patterns were noted and luminal content as unremarkable. This is a mild change.

Pancreas

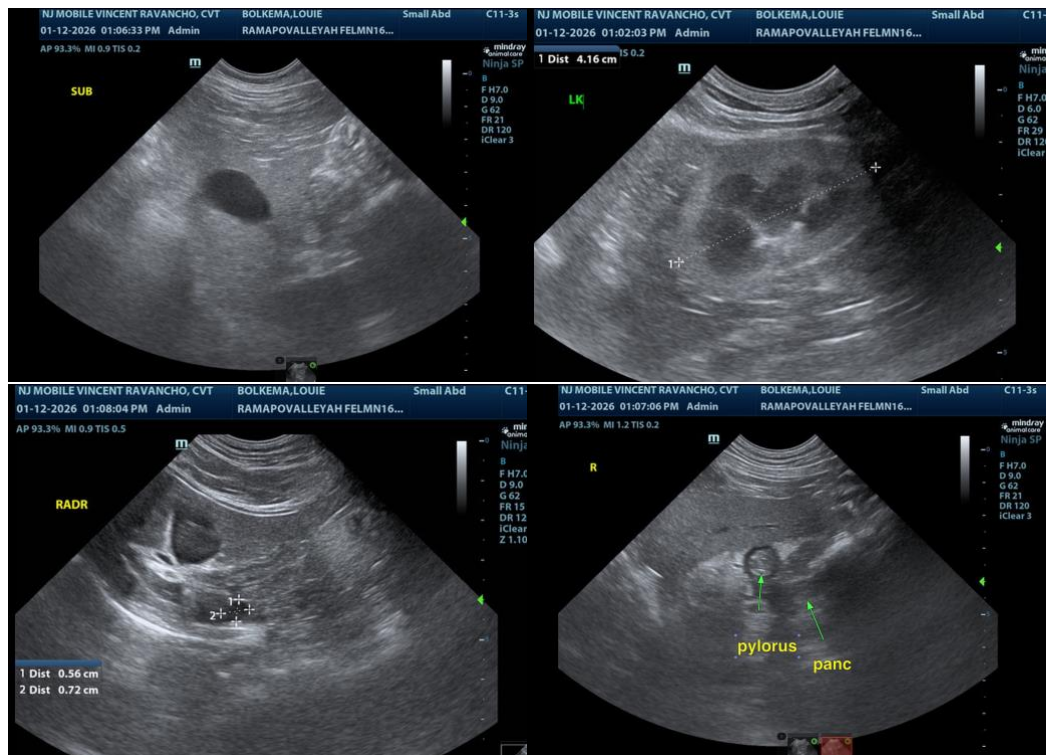
The base and limbs of the **pancreas** were observed to be largely isoechoic to surrounding omental fat. Some mild parenchymal remodeling, however, with mild deviation from curvilinear normalcy was observed. Pancreatic duct and capsular irregularities were present consistent with age related changes. If pain upon imaging (+ Murphy sign) was present or if the patient is focally painful in subxiphoid palpation, then low-grade smoldering chronic pancreatitis should be suspected.

ULTRASONOGRAPHIC FINDINGS

- Minor intestinal thickening
- No evidence of neoplastic criteria
- Slight hyperechoic lipid plaques in the spleen
- Geriatric abdomen

INTERPRETATION OF THE FINDINGS & FURTHER RECOMMENDATIONS

Occult inflammatory bowel or age related chronic inflammatory bowel presentation likely.





PATIENT

Louie Bolkema

SPECIES

Feline

BREED

DSH

SEX

Neutered Male

AGE

16 Years 9 Months

WEIGHT

11.4

INTERPRETED BY

Eric Lindquist, DMV,
 DABVP (CFM), Cert.
 IVUSS

IMAGING PERFORMED BY

Vincent Ravancho, CVT

HOSPITAL NAME

Ramapo Valley AH

REFERRING VET

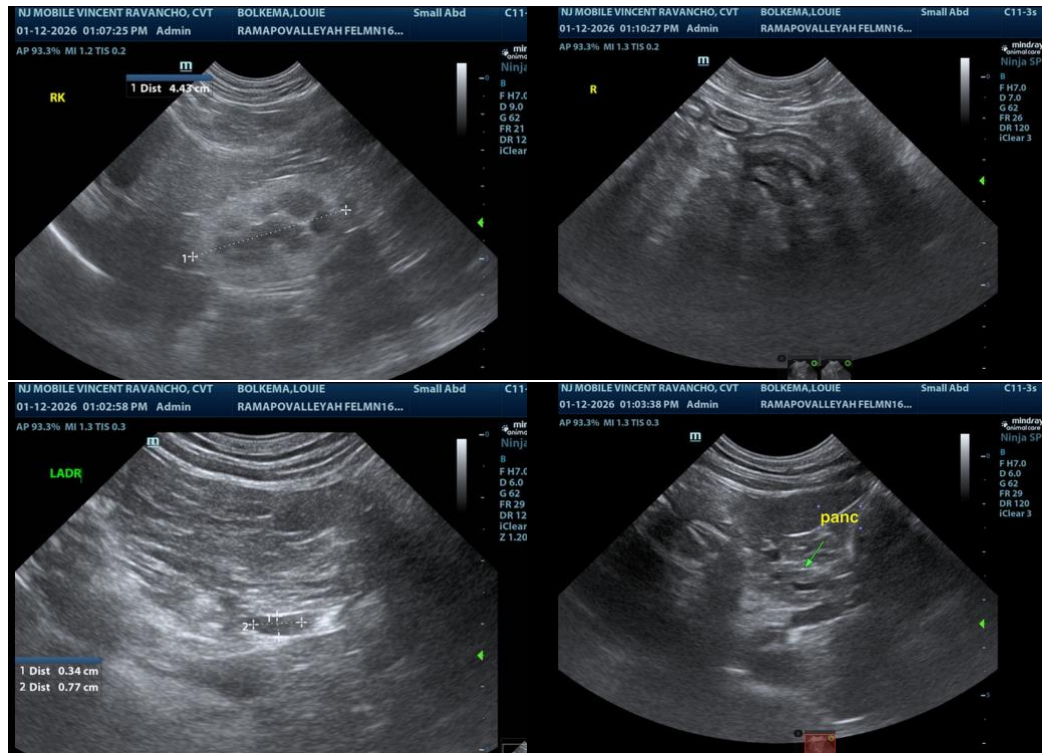
Dr. Katara

INVOICE

35368

DATE

1/12/26



The information and recommendations provided are based on the images presented by the referring veterinarian/sonographer. No evaluation can be communicated regarding pathology that was not visible in the image/video clips provided.

Thank you for this referral. If the clinical or image interpretation does not parallel your findings or if I can be of any further assistance please contact me.

Eric Lindquist, DMV, DABVP(CFM), Cert. IVUSS,
 CEO, Owner, Founder -- SonoPath.com
info@SonoPath.com