



PATIENT

Gracie Wood

SPECIES

Canine

BREED

Yorkie

SEX

Spayed female

AGE

11 years

WEIGHT

6 lbs

INTERPRETED BY

Eric Lindquist, DMV
DABVP, Cert. IVUSS

IMAGING PERFORMED BY

Jill Rumachik

HOSPITAL NAME

Clarity Imaging LLC

REFERRING VET

Dr. Hoffman

INVOICE

70075

DATE

1/13/26

PRESENTING CLINICAL SIGNS

History: Diarrhea and weight loss recently. Known to only have 1 kidney
Abnormal PE/Chem/CBC/UA Results: 1/2/26: SDMA = 15; CREAT and BUN wnl; lipase 433; slight elevation in ALT/AST.

ULTRASONOGRAPHIC EXAMINATION OF THE ABDOMEN

Urinary System

The **urinary bladder**, trigone, and pelvic urethra presented normal thicknesses and normal tone. The ureters were not visible which is normal. No uroliths or sediment were visualized and anechoic urine was present. No evidence of inflammatory or neoplastic changes was noted. Ureteral papillae were normal.

The **right kidney** revealed normal size and structure, corticomedullary definition and ratio for this age. The cortices presented largely uniform texture with normal echogenic relationship to liver and spleen. Medullary structure differed distinctly from the cortex and no evidence of pelvic dilation was present. The capsule was acceptably uniform without significant irregularities. Idiopathic, hyperechoic medullary rim sign was noted. The right kidney measured 3.4 cm. The left kidney was not visualized.

Adrenal Glands

The left **adrenal gland** was not visualized, and the region of the right adrenal gland was imaged with no evidence of pathology.

Spleen

The **spleen** presented a smooth homogeneous parenchyma hyperechoic to liver and renal cortical parenchyma. The capsule was smooth without noticeable expansion or deviation from within the spleen or adjacent pathology. The splenic vasculature demonstrated normal volume without signs of congestion or thrombosis. No sonographic evidence of acute or chronic inflammatory, neoplastic, or infarctual changes was noted.

Liver

The **liver** images from right and left intercostal as well as subcostal views revealed subjectively normal liver size, contour, and structure. Some age-related parenchymal remodeling was noted but likely not clinically significant at this time. Vascular and biliary tracts were of normal volume and no evidence of congestion was noted. Gallbladder polyps were noted.



PATIENT

Gastrointestinal

Gracie Wood

Examination of the **gastrointestinal tract** revealed a stomach and intestine free of stasis, of normal wall thickness, acceptable curvilinear mural detail, and peristaltic activity. Small and large intestine demonstrated normal luminal chyme and stool consistency respectively. No obstructive or overt infiltrative disease was noted. No associated abnormal lymphatic activity was noted.

SPECIES

Canine

BREED

Yorkie

SEX

Spayed female

AGE

11 years

WEIGHT

6 lbs

Pancreas

The base and limbs of the **pancreas** were observed to be largely isoechoic to surrounding omental fat. Pancreatic duct and capsular contour were acceptably normal and parenchyma respected normal curvilinear patterns. No overt evidence of active inflammatory or neoplastic disease was noted.

ULTRASONOGRAPHIC FINDINGS

Aplastic left kidney.

INTERPRETATION OF THE FINDINGS & FURTHER RECOMMENDATIONS

Structurally unremarkable abdomen with non-specific inflammatory hepatopathy. FNA of the liver can be considered for further definition.

Maldigestion panel, three view chest radiographs and full CNS examination is recommended to examine for occult disease that could be responsible for the weight loss. Evaluation for competitive eating environments should also be considered.

INTERPRETED BY

Eric Lindquist, DMV
DABVP, Cert. IVUSS

IMAGING PERFORMED BY

Jill Rumachik

HOSPITAL NAME

Clarity Imaging LLC

REFERRING VET

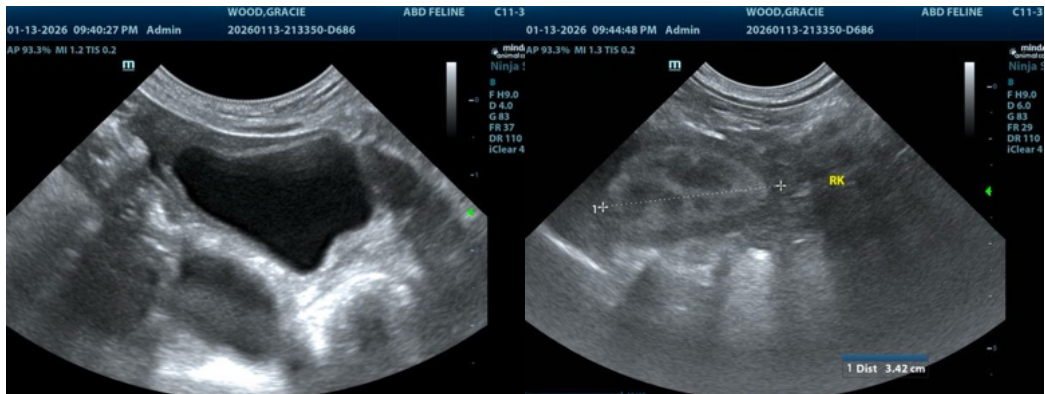
Dr. Hoffman

INVOICE

70075

DATE

1/13/26





PATIENT

Gracie Wood

SPECIES

Canine

BREED

Yorkie

SEX

Spayed female

AGE

11 years

WEIGHT

6 lbs

INTERPRETED BY

Eric Lindquist, DMV
DABVP, Cert. IVUSS

IMAGING PERFORMED BY

Jill Rumachik

HOSPITAL NAME

Clarity Imaging LLC

REFERRING VET

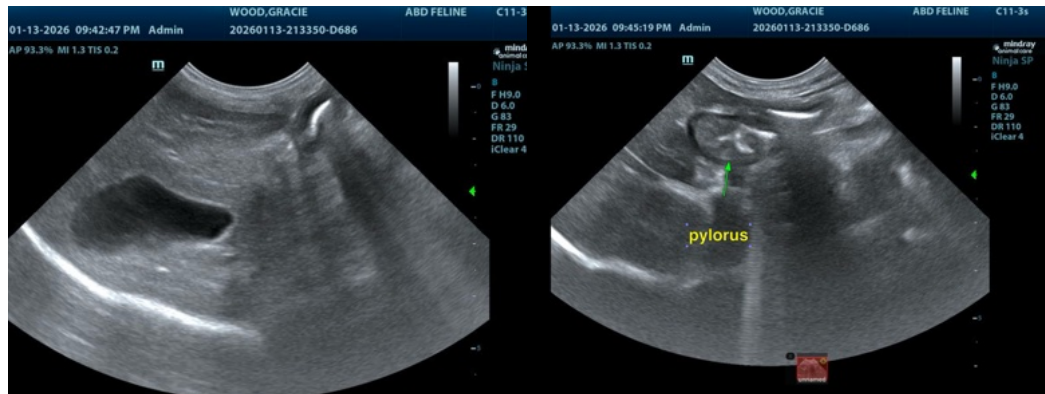
Dr. Hoffman

INVOICE

70075

DATE

1/13/26



The information and recommendations provided are based on the images presented by the referring veterinarian/sonographer. No evaluation can be communicated regarding pathology that was not visible in the image/video clips provided.

Thank you for this referral. If the clinical or image interpretation does not parallel your findings or if I can be of any further assistance please contact me.

Eric Lindquist, DMV, DABVP (CFM), Cert. IVUSS, CEO of SonoPath.com

info@SonoPath.com