



PATIENT

Ethel Jimerson

SPECIES

Canine

BREED

Maltipoo

SEX

Spayed female

AGE

6 years

WEIGHT

4 lbs

INTERPRETED BY

Eric Lindquist, DMV
DABVP, Cert. IVUSS

IMAGING PERFORMED BY

Alicia Walter, DVM

HOSPITAL NAME

Alicia Walter

REFERRING VET

Alicia Walter, DVM

INVOICE

70044

DATE

1/13/26

PRESENTING CLINICAL SIGNS

History: PC:CHRONIC HYPOREXIA for dog food, will eat bacon, pork, beef, chicken. CHRONIC INTERMITTENT VOMITING +/- DIARRHEA, usually resolves on it's own. WT LOSS, -9% body wt in 9 months. BCS 3/9 Ddx include dietary allergy/intolerance, inflammatory bowel dz, PLE, neoplasia, other. (Note: pt lives w/ littermate who weighs 7.5lb, BCS 7/9 and always has strong appetite.)
Abnormal PE/Chem/CBC/UA Results: PLT increased at 572K. ALB decreased from 3.2 to 2.9 in 9 months. ALT increased from 51 to 73, in 9mos. USG 1.066, 2+ proteinuria. PCR fecal all neg. TLI/PLI/cobalamin/folate all wnl. Resting cortisol 2.7. ABD RADS nsf except decreased serosal detail.

ULTRASONOGRAPHIC EXAMINATION OF THE ABDOMEN

Urinary System

The **urinary bladder**, trigone, and pelvic urethra presented normal thicknesses and normal tone. The pelvic urethra was imaged 1.0 cm beyond the cystourethral junction and appeared normal. The ureters were not visible which is normal. No uroliths or sediment were visualized and anechoic urine was present. No evidence of inflammatory or neoplastic changes was noted. Ureteral papillae were normal.

The **kidneys** revealed normal size and structure, corticomedullary definition and ratio for this age. The cortices presented largely uniform texture with normal echogenic relationship to liver and spleen. Medullary structure differed distinctly from the cortex and no evidence of pelvic dilation was present. The capsules were acceptably uniform without significant irregularities. The right kidney measured 3.3 cm. The left kidney measured 2.9 cm.

Adrenal Glands

Both **adrenal glands** were visualized and recognized as having normal shape, size, position and echogenicity for this breed. The phrenic vasculature, glandular echogenicity and detail were unremarkable. Capsule, cortex, and medullary definition were normal for this age patient. The left adrenal gland measured 1.5 x 0.3 cm at the cranial pole and 0.33 cm at the caudal pole. The right adrenal gland measured 0.74 cm at the cranial pole and 0.53 cm at the caudal pole.

Spleen

The **spleen** in this patient was mildly enlarged with uniform parenchyma and was folded upon itself caudally. This is a positional variant and is not pathological. There was no evidence of significant disease.

Liver

The **liver** images submitted revealed subjectively normal liver size, contour, and structure. Parenchymal echogenicity was naturally coarse and hypoechoic to the spleen. Vascular and biliary tracts were of normal volume with no evidence of congestion. The gallbladder presented acceptably thin walls with primarily anechoic content. The cystic and common bile ducts were normal. No pathological hepatic



PATIENT

Ethel Jimerson

lymphadenopathy was evident. No overt structural evidence of inflammatory, infiltrative or regenerative pathology was evident.

SPECIES

Canine

Gastrointestinal

Examination of the **gastrointestinal tract** revealed a stomach and intestine free of stasis, of normal wall thickness, acceptable curvilinear mural detail, and peristaltic activity. Small and large intestine demonstrated normal luminal chyme and stool consistency respectively. No obstructive or overt infiltrative disease was noted. No associated abnormal lymphatic activity was noted.

BREED

Maltipoo

SEX

Spayed female

Pancreas

The base and limbs of the **pancreas** were observed to be largely isoechoic to surrounding omental fat. Pancreatic duct and capsular contour were acceptably normal and parenchyma respected normal curvilinear patterns. No overt evidence of active inflammatory or neoplastic disease was noted.

AGE

6 years

WEIGHT

4 lbs

ULTRASONOGRAPHIC FINDINGS

Structurally unremarkable abdomen.

INTERPRETED BY

Eric Lindquist, DMV
DABVP, Cert. IVUSS

INTERPRETATION OF THE FINDINGS & FURTHER RECOMMENDATIONS

There was no evidence of pathology in this patient.

IMAGING PERFORMED BY

Alicia Walter, DVM

HOSPITAL NAME

Alicia Walter

REFERRING VET

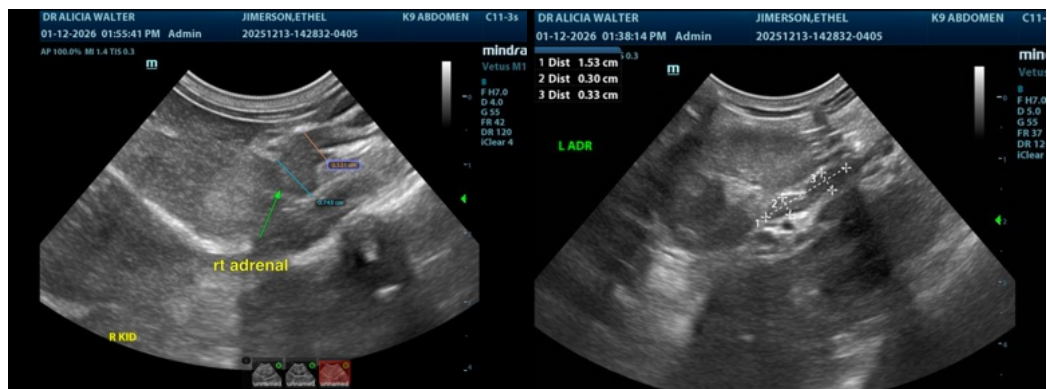
Alicia Walter, DVM

INVOICE

70044

DATE

1/13/26





PATIENT

Ethel Jimerson

SPECIES

Canine

BREED

Maltipoo

SEX

Spayed female

AGE

6 years

WEIGHT

4 lbs

INTERPRETED BY

Eric Lindquist, DMV
DABVP, Cert. IVUSS

IMAGING PERFORMED BY

Alicia Walter, DVM

HOSPITAL NAME

Alicia Walter

REFERRING VET

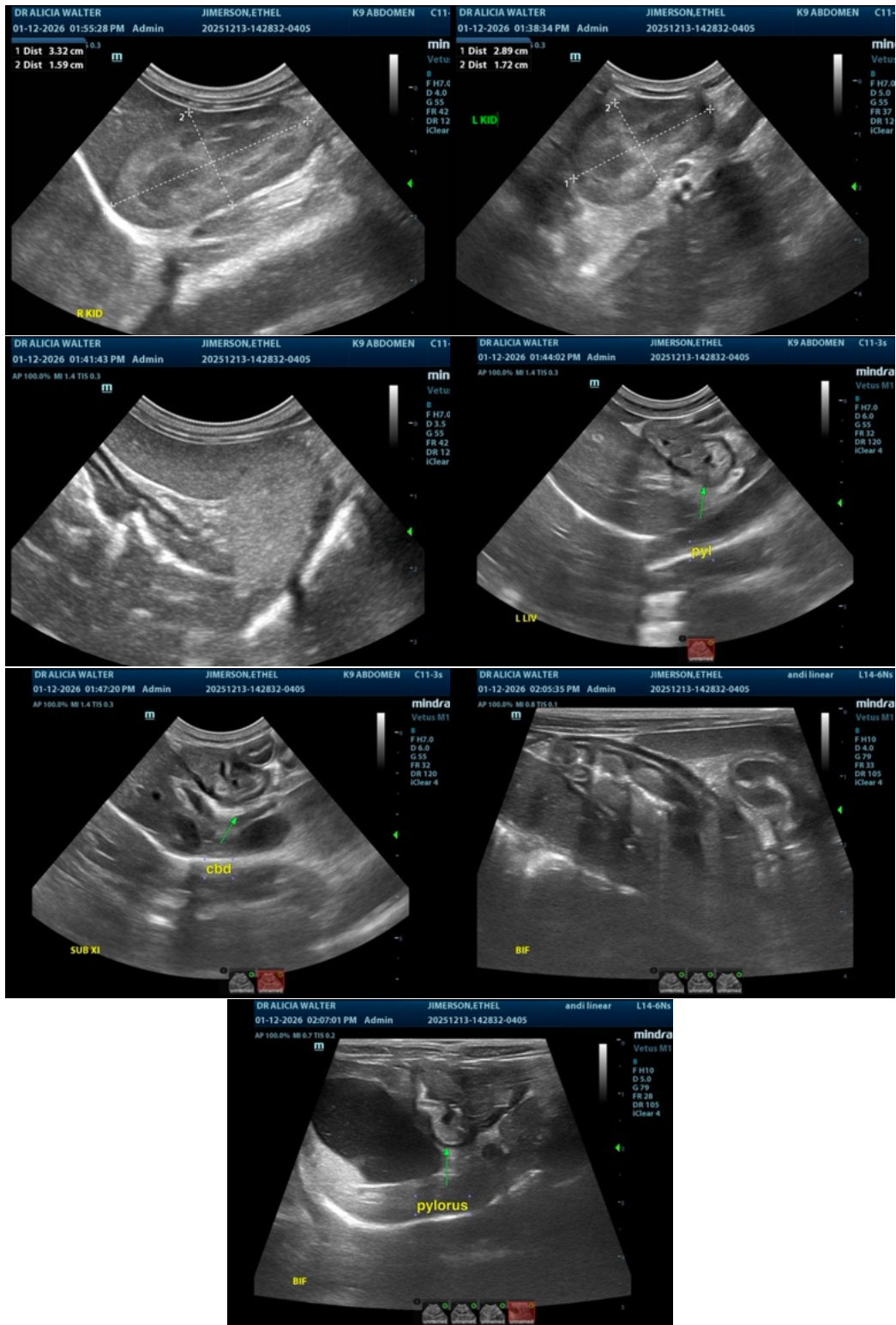
Alicia Walter, DVM

INVOICE

70044

DATE

1/13/26





PATIENT

Ethel Jimerson

The information and recommendations provided are based on the images presented by the referring veterinarian/sonographer. No evaluation can be communicated regarding pathology that was not visible in the image/video clips provided.

SPECIES

Canine

Thank you for this referral. If the clinical or image interpretation does not parallel your findings or if I can be of any further assistance please contact me.

Eric Lindquist, DMV, DABVP (CFM), Cert. IVUSS, CEO of SonoPath.com

BREED

Maltipoo

info@SonoPath.com

SEX

Spayed female

AGE

6 years

WEIGHT

4 lbs

INTERPRETED BY

Eric Lindquist, DMV
DABVP, Cert. IVUSS

IMAGING PERFORMED BY

Alicia Walter, DVM

HOSPITAL NAME

Alicia Walter

REFERRING VET

Alicia Walter, DVM

INVOICE

70044

DATE

1/13/26