

PATIENT

Buddy Matthews

SPECIES

Canine

BREED

Labrador Mix

SEX

Neutered male

AGE

13 years

WEIGHT

55 lbs

INTERPRETED BY

Eric Lindquist, DMV
DABVP, Cert. IVUSS

IMAGING PERFORMED BY

James Hornbuckle

HOSPITAL NAME

Golden Isles AH

REFERRING VET

Dr. Hornbukckle

INVOICE

70097

DATE

1/13/26

PRESENTING CLINICAL SIGNS

History: 01-06-2026 4:05:37pm, Coughing up hair balls, overgrooms historically Now a deeper cough over the past 3-4 weeks Longer episodes of coughing hx of heartworm disease 8 years ago Radiology consult attached- right sided enlargement Heart disease vs neoplasia Inappetence x a few days , usually very food motivated Coughed up white foam within the week Lethargic x a few days Started lasix 12.5 mg and clavamox presumptively a week ago, now getting increasingly difficult to administer the antibiotic o trying many different high value food items Ultrasound was ordered to further evaluate the radiographic changes and ongoing cough

ULTRASONOGRAPHIC EXAMINATION OF THE HEART

The echocardiogram in this patient demonstrated normal **left atrial** and **left ventricle** with mildly thickened **mitral** valve. The left ventricular septum was flattened owing to volume overload. The **left ventricular outflow** tract demonstrated normal laminar flow and subjective structural integrity. The **right atrium** and **right ventricle** presented volume overload. **Tricuspid** insufficiency was not visualized, yet suspected. **Pulmonary artery** was mildly dilated. The **pyloric outflow** tract assessment revealed normal valve structure, laminar flow, and diameter (approx.1:1 pa/ao ratio). No visible **pericardial** or free pleura fluid was noted. The cranial **mediastinum** and **pericardial and extra-cardiac regions** were free of masses in the visible window. Occasional arrhythmogenic activity was noted.

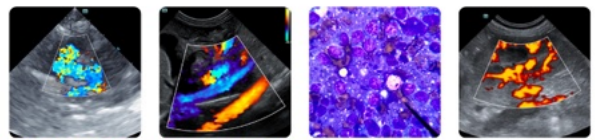
CANINE CARDIAC PARAMETERS	MR VMAX (m/s)	TR VMAX (m/s)	LA/AO	LA/AO (Heart Base)	FS (%)	EF (%)	EPSS (cm)
NORMAL PARAMETER	4.5-5.5	<2.7	1.3	<1.6	28-40	40-100	<0.6
PATIENT	-	-	1.3	1.5	40	72	0.1
CANINE CARDIAC PARAMETERS	HR (BPM)	AV VMAX (m/s)	PV MAX (m/s)	BODY WEIGHT	LA 2D short axis Base view (cm)	LVIDd Avg; 2D and m-mode short axis (cm)	LVIDs Avg; 2D and m-mode short axis (cm)
NORMAL PARAMETER	50-100	0.7-1.7	0.7-1.6	BELOW	BELOW	BELOW	BELOW
PATIENT	80	-	0.6	55 lbs	3.4 max	2.82	

ULTRASONOGRAPHIC FINDINGS

Pulmonary hypertension pattern, likely owing to primary respiratory disease.

INTERPRETATION OF THE FINDINGS & FURTHER RECOMMENDATIONS

Heartworm cannot be ruled out. Heartworm testing is indicated. No left-sided cardiac enlargement was



PATIENT

Buddy Matthews

SPECIES

Canine

BREED

Labrador Mix

SEX

Neutered male

AGE

13 years

WEIGHT

55 lbs

INTERPRETED BY

Eric Lindquist, DMV
DABVP, Cert. IVUS

IMAGING PERFORMED BY

James Hornbuckle

HOSPITAL NAME

Golden Isles AH

REFERRING VET

Dr. Hornbuckle

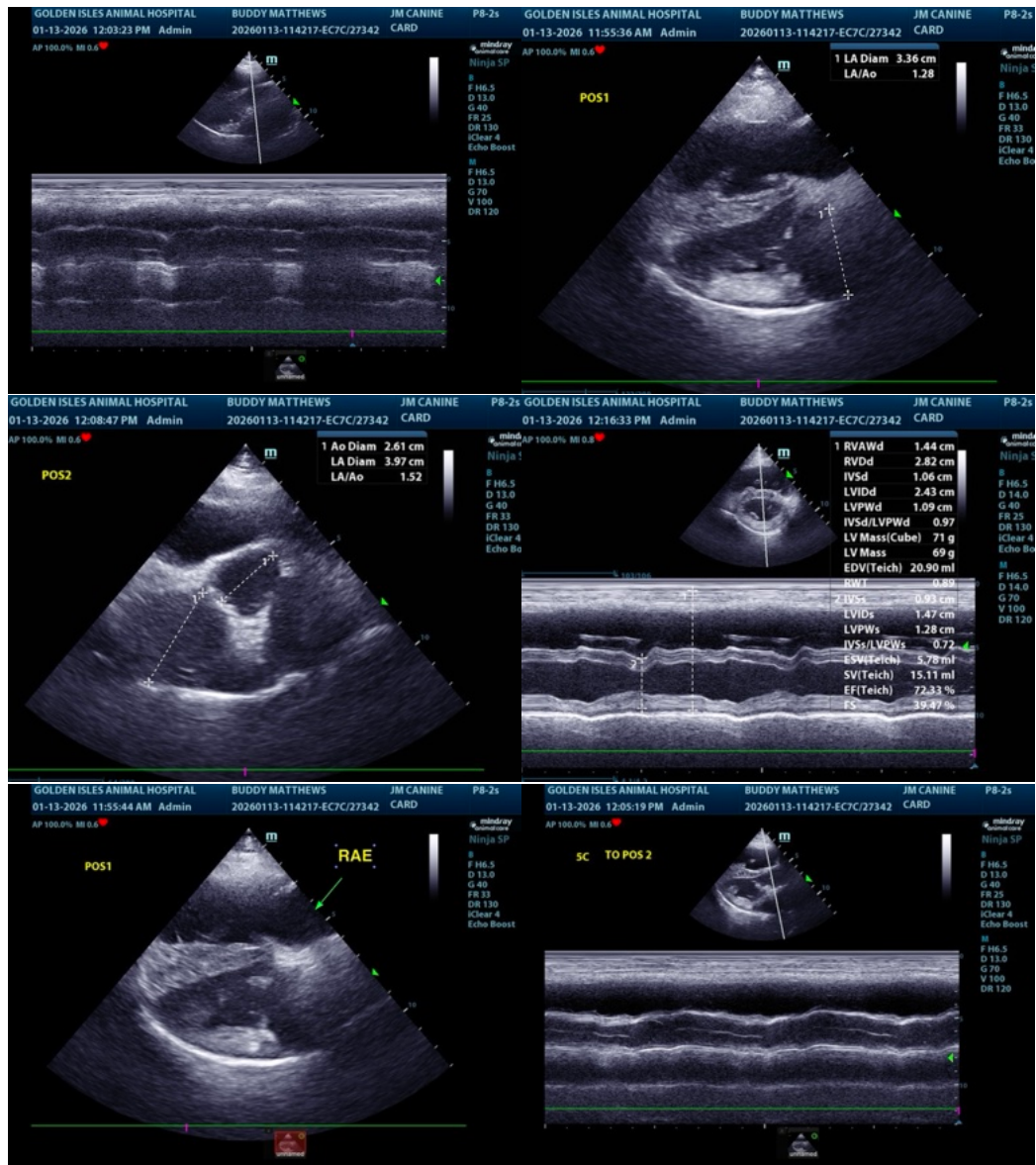
INVOICE

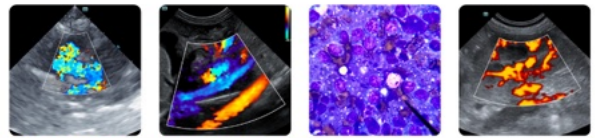
70097

DATE

1/13/26

noted. Given the exercise intolerance, I recommend initiating Sildenafil at 1 mg/kg b.i.d. increasing to 1.5 mg/kg b.i.d. after 2 weeks. Ace inhibitor at 0.5 mg/kg s.i.d. progressing to b.i.d. and Spironolactone at 1-2 mg/kg s.i.d. would be indicated. Recheck echocardiogram is recommended in a month. Primary respiratory protocol is recommended based on radiographic finding. Screening of the hepatic veins and vena cava are warranted as well as assessing for ascites in the abdomen.





PATIENT

Buddy Matthews

SPECIES

Canine

BREED

Labrador Mix

SEX

Neutered male

AGE

13 years

WEIGHT

55 lbs

INTERPRETED BY

Eric Lindquist, DMV
DABVP, Cert. IVUSS

IMAGING PERFORMED BY

James Hornbuckle

HOSPITAL NAME

Golden Isles AH

REFERRING VET

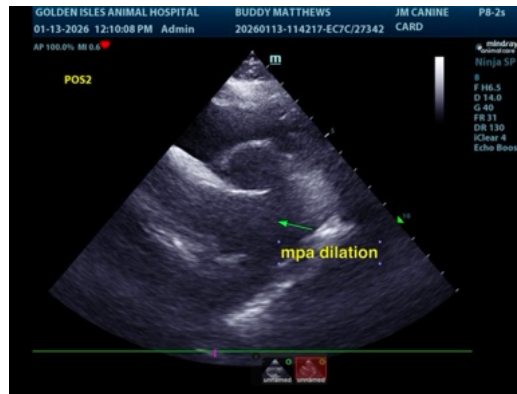Dr. Hornbukckle

INVOICE

70097

DATE

1/13/26



The information and recommendations provided are based on the images presented by the referring veterinarian/sonographer. No evaluation can be communicated regarding pathology that was not visible in the image/video clips provided.

Thank you for this referral. If the clinical or image interpretation does not parallel your findings or if I can be of any further assistance please contact me.

Eric Lindquist, DMV, DABVP (CFM), Cert. IVUSS, CEO of SonoPath.com

info@SonoPath.com