



**PATIENT PRESENTING CLINICAL SIGNS**

Toby Bustamante New murmur, 2-3/6 HM tachypnea.

**SPECIES ULTRASONOGRAPHIC EXAMINATION OF THE HEART**

Canine

**BREED**

Poodle X

**SEX**

Neutered Male

**AGE**

8

**WEIGHT**

35

| CANINE CARDIAC PARAMETERS | MR VMAX (m/s) | TR VMAX (m/s) | LA/AO (Boon method) | LA/AO (Heart Base; Swe) | FS (%)                          | EF (%)                                   | EPSS (cm)                                |
|---------------------------|---------------|---------------|---------------------|-------------------------|---------------------------------|--|--|
| NORMAL PARAMETER          | 4.5-5.5       | <2.7          | 1.3                 | <1.6                    | 28-40                           | 40-100                                   | <0.6                                     |
| PATIENT                   | 5.8           |               | 1.3                 | 1.8                     | 35                              | 65                                       | NM                                       |
| CANINE CARDIAC PARAMETERS | HR (BPM)      | AV VMAX (m/s) | PV MAX (m/s)        | BODY WEIGHT (kg)        | LA 2D short axis Base view (cm) | LVIDd Avg; 2D and m-mode short axis (cm) | LVIDs Avg; 2D and m-mode short axis (cm) |
| NORMAL PARAMETER          | 50-100        | 0.7-1.7       | 0.7-1.6             | BELOW                   | BELOW                           | BELOW                                    | BELOW                                    |
| PATIENT                   | 125           |               | 1.3                 |                         | 4.2                             | 3.57                                     |  |

**INTERPRETED BY**

Eric Lindquist, DMV

DABVP, Cert. IVUSS

**IMAGING PERFORMED BY**

Jenn

**HOSPITAL NAME**

Rockaway AH

**REFERRING VET**

Dr. Maniar

**INVOICE**

44219

**DATE**

1/13/23

**Cardiac Presentation**

The **left atrium** was mildly enlarged in this patient. Deviation of the atrial septum towards the right atrium noted. Chamber volumes and echogenicity were normal. The cranial and caudal **mitral valve** leaflets presented vegetative thickening consistent with endocardiosis. Doppler indicated measurable insufficiency. The **left ventricle** presented thicknesses with linear contour and was not dilated nor restricted. The **myocardium** presented normal echogenicity without subjective evidence of significant fibrotic or ischemic disease. **Contractility** of the ventricular walls was adequate and in normal range for this patient evidenced by the fractional shortening measurement and subjective evaluation of the different regions of the myocardium. The **left ventricular outflow** tract demonstrated normal laminar flow and subjective structural integrity. The **right atrium** and auricle revealed normal size, structure and content. No evidence of masses was noted or chamber overload. Minor **tricuspid** insufficiency noted. The **right ventricle** was of normal size (1/3 diameter of LV), chordae structure, myocardial echogenicity and thickness. **Pulmonic** tract assessment revealed normal valve structure, laminar flow, and diameter (approx. 1:1 pa/ao ratio). No visible **pericardial** or free pleura fluid was noted. No echographically detectable evidence of infiltrative disease was visible. The cranial **mediastinum** and **pericardial regions** were free of masses in the visible window.

**ULTRASONOGRAPHIC FINDINGS**

- Early Stage B2 valvular disease
- Left atrial enlargement, primarily evident in the LA max position

**INTERPRETATION OF THE FINDINGS & FURTHER RECOMMENDATIONS**

The tachypnea is unlikely to be cardiogenic, as there is no evidence of heart failure present. However, mild left atrial enlargement is present. Pimobendan could be initiated at 0.3 mg/kg BID.



**PATIENT**

Toby Bustamante

**SPECIES**

Canine

**BREED**

Poodle X

**SEX**

Neutered Male

**AGE**

8

**WEIGHT**

35

**INTERPRETED BY**

Eric Lindquist, DMV

DABVP, Cert. IVUSS

**IMAGING PERFORMED BY**

Jenn

**HOSPITAL NAME**

Rockway AH

**REFERRING VET**

Dr. Maniar

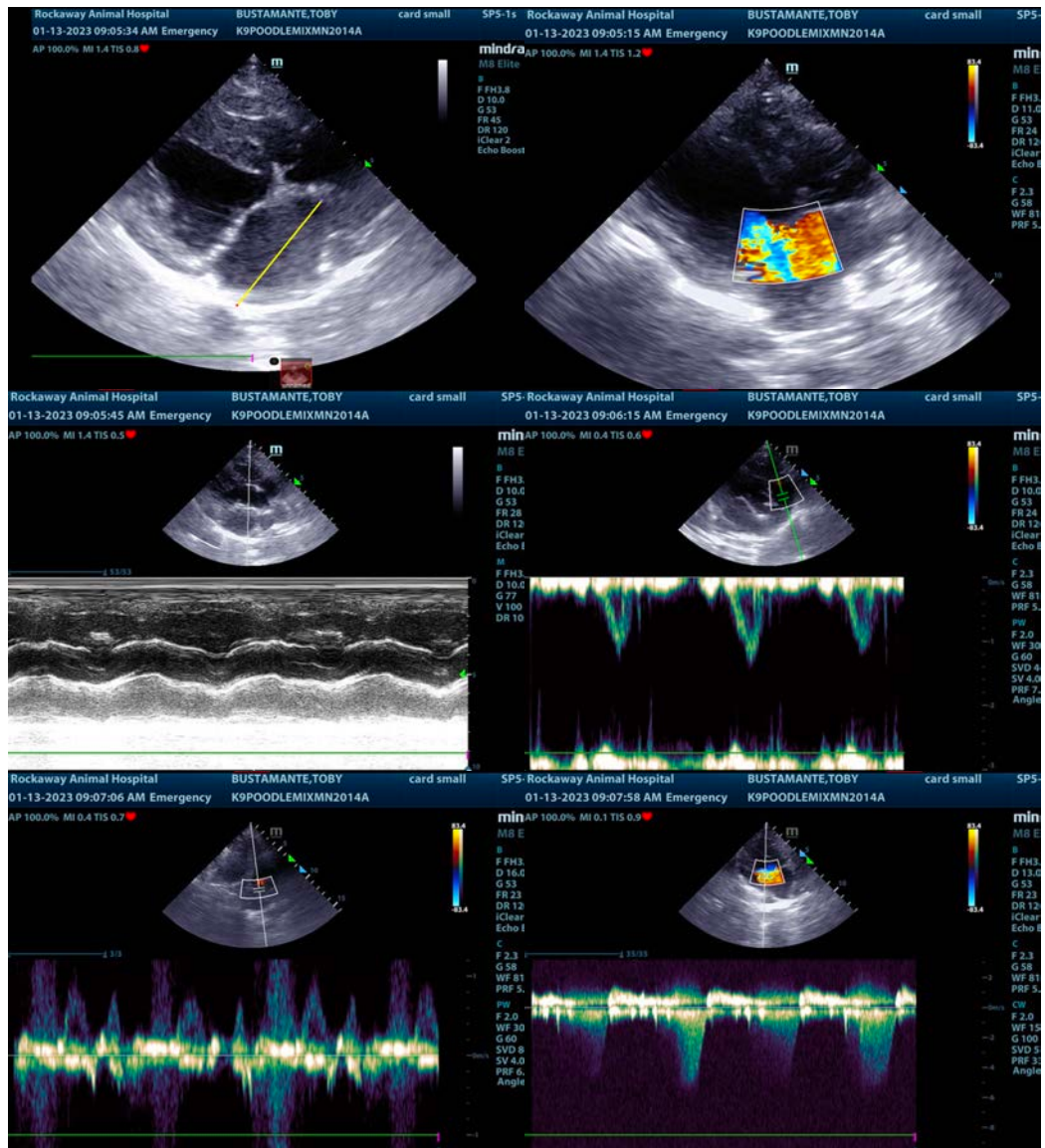
**INVOICE**

44219

**DATE**

1/13/23

The heart has some volume overload and is working to compensate for the valvular insufficiency. Target respiratory rate is < 20 resp/minute after therapy. After initiating therapy, I recommend recheck on the clinical exam, BUN, Creatinine, USG, Chest radiographs & Blood pressure in 5-7 days. Recheck echo in 1 month. Earlier if clinical decompensation is occurring. I do not recommend anesthesia at this time until stabilization has occurred on the recommended medications. Repeat preanesthetic echo is ideal if anesthesia is eventually necessary. There is moderate anesthetic risk for this patient. I recommend cardiac treatment prior to sedation unless only light opioids are utilized which would have minimal effect on heart function.





**PATIENT**

Toby Bustamante

**SPECIES**

Canine

**BREED**

Poodle X

**SEX**

Neutered Male

**AGE**

8

**WEIGHT**

35

**INTERPRETED BY**

Eric Lindquist, DMV

DABVP, Cert. IVUSS

**IMAGING PERFORMED BY**

Jenn

**HOSPITAL NAME**

Rockaway AH

**REFERRING VET**

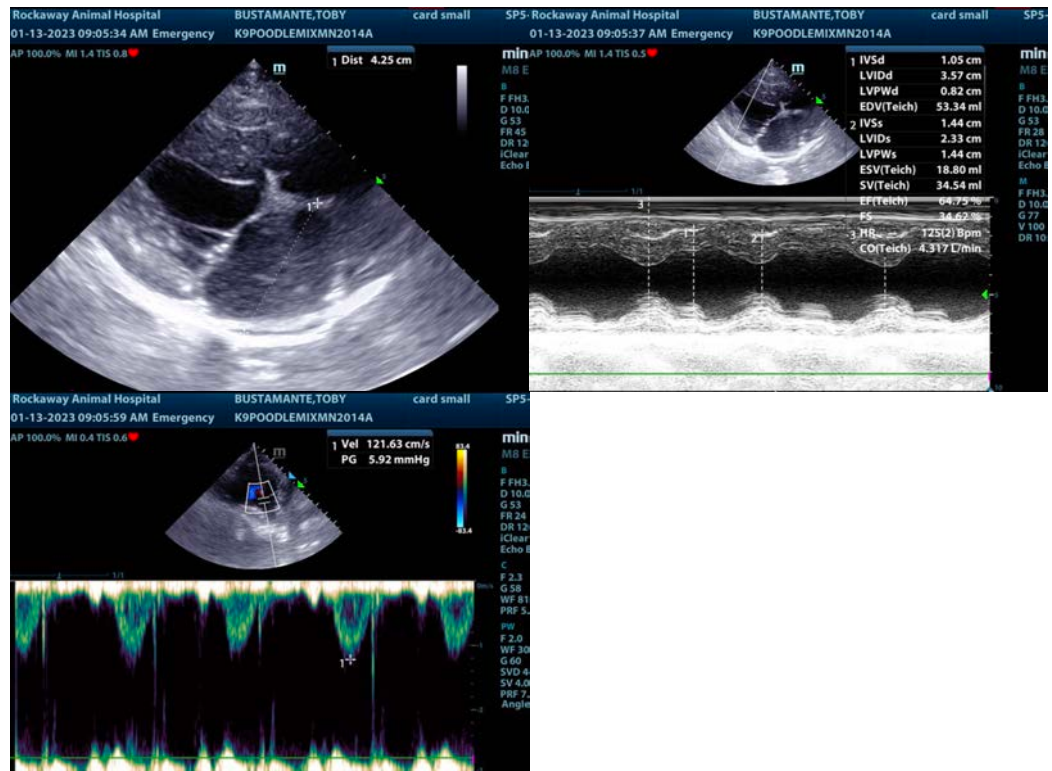
Dr. Maniar

**INVOICE**

44219

**DATE**

1/13/23



The information and recommendations provided are based on the images presented by the referring veterinarian/sonographer. No evaluation can be communicated regarding pathology that was not visible in the image/video clips provided.

Thank you for this referral. If the clinical or image interpretation does not parallel your findings or if I can be of any further assistance please contact me.

Eric Lindquist, DMV, DABVP, Cert. IVUSS, CEO of SonoPath.com

[info@SonoPath.com](mailto:info@SonoPath.com)