

**DATE PRESENTING CLINICAL SIGNS**

1/13/23

History: Original scan done at Cat Sense last march, pet was not eating well and losing weight. Pet eats now but only with Mirataz daily, if meds discontinued - pet stops eating. Last scan had concern with regards to spleen and this was never followed up on.

**PATIENT**Sophia Olivia  
Brookhart

Current Medications: Mirataz daily.

Lab Results: elevated Ft4

Date of Previous IntraPet Ultrasound: 3/11/22. See attached.

Sedation: Patient sedated with Torbugesic &amp; Valium.

Stat Report: Not requested.

Imaging Performed By: Andi Parkinson, BS, RDMS.

**SPECIES**

Feline

**BREED**

DSH

**SEX**

Spayed Female

**AGE**

10/29/11

**WEIGHT**

11.13 Pounds

**INTERPRETED BY**Eric Lindquist, DMV  
DABVP, Cert. IVUSS**HOSPITAL NAME**Happier at Home  
Mobile Vet**REFERRING VET**

Dr. Haskin

**INVOICE**

20552

**ULTRASONOGRAPHIC EXAMINATION OF THE ABDOMEN****Urinary System**

The **urinary bladder**, trigone, and pelvic urethra presented normal thicknesses and normal tone. The ureters were not visible which is normal. No uroliths or sediment were visualized, and anechoic urine was present. No evidence of inflammatory or neoplastic changes were noted. Ureteral papillae were normal.

The **left kidney** revealed uniform size and contour. Age-related increased cortical echogenicity was noted. Slight pinpoint mineralizations were noted. The left kidney measured 3.54 cm.

The **right kidney** measured 3.73 cm with similar changes to the left kidney.

**Adrenal Glands**

Both **adrenal glands** were visualized and recognized as having normal shape, size, position and echogenicity for this breed. The phrenic vasculature, glandular echogenicity and detail were unremarkable. Capsule, cortex, and medullary definition were normal for this age patient. The left adrenal gland measured 0.44 cm.

**Spleen**

The **spleen** presented a smooth homogeneous parenchyma hyperechoic to liver and renal cortical parenchyma. The capsule was smooth without noticeable expansion or deviation from within the spleen or adjacent pathology. The splenic vasculature demonstrated normal volume without signs of congestion or thrombosis. No sonographic evidence of acute or chronic inflammatory, neoplastic, or infarctual changes were noted.

**Liver**

The **liver** revealed coarse architecture. The liver was isoechoic to falciform fat. Hyperechoic lipogranuloma was noted, measuring 0.5 cm, not pathological. The gallbladder was unremarkable. Slight biliary mineralization was noted in the cystic duct.

**Gastrointestinal**

Examination of the **gastrointestinal tract** revealed a stomach and intestine free of stasis, of normal wall thickness, acceptable curvilinear mural detail, and peristaltic activity. Small and large intestine demonstrated normal luminal chyme and stool consistency respectively. No obstructive or overt infiltrative disease was noted. No associated abnormal lymphatic activity was noted.

**Pancreas**

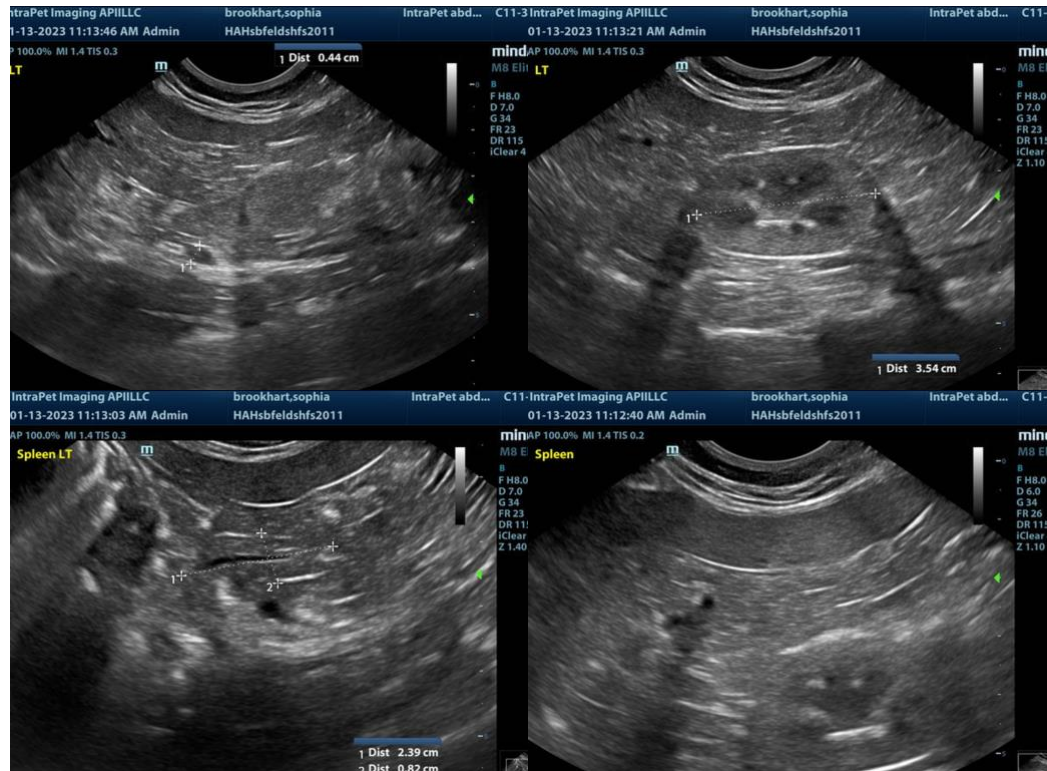
The base and limbs of the **pancreas** were observed to be largely isoechoic to surrounding omental fat. Some minor parenchymal remodeling, however, with mild deviation from curvilinear normalcy was observed. Pancreatic duct and capsular irregularities were present consistent with age related changes. If pain upon imaging (+ Murphy sign) was present or if the patient is focally painful in subxyphoid palpation, then low-grade smoldering chronic pancreatitis should be suspected. The spleen has normalized in size, measuring 9.0 mm.

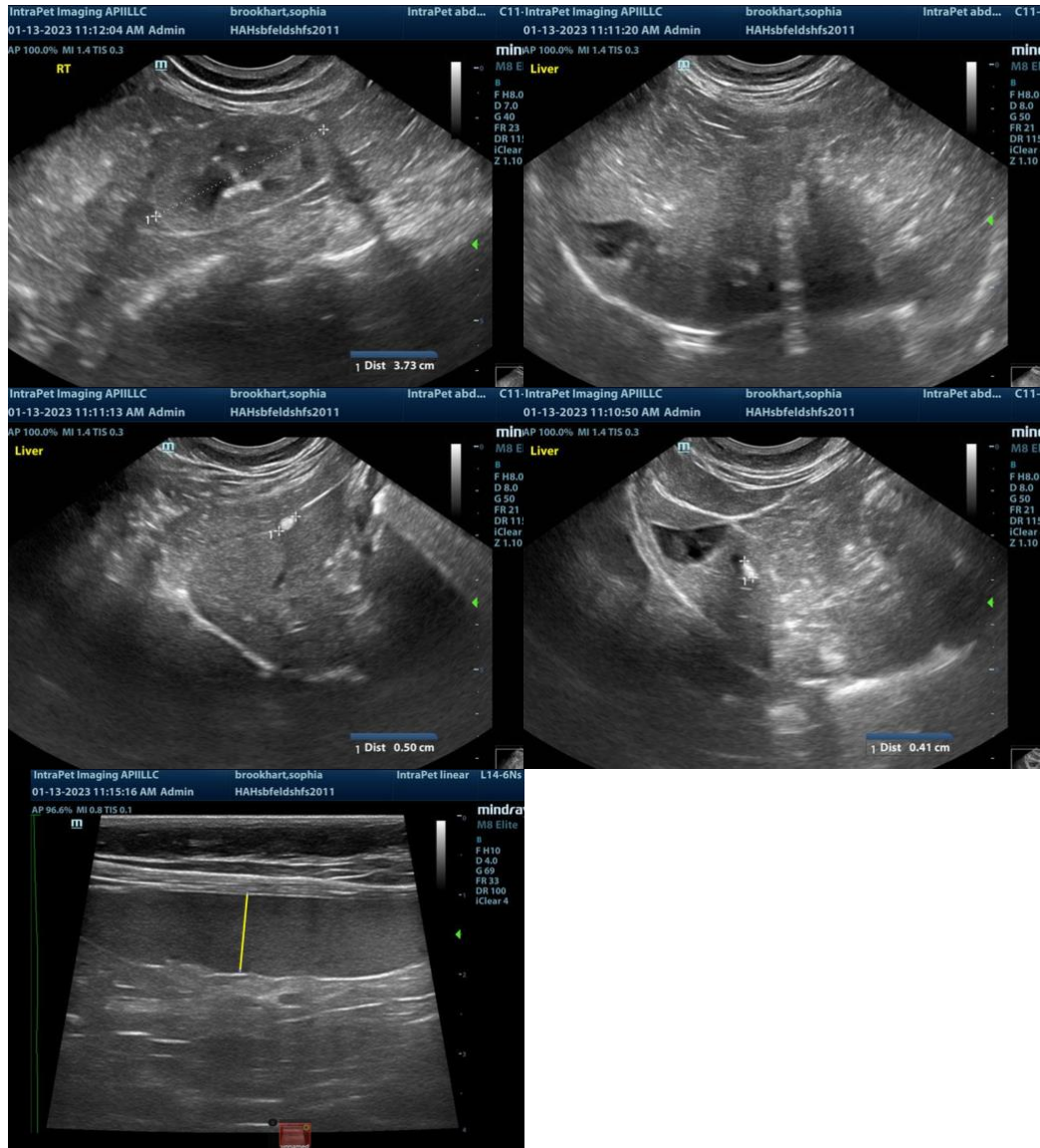
### ULTRASONOGRAPHIC FINDINGS

- Geriatric abdomen
- Normalized spleen
- Minor biliary mineralization
- Coarse architecture in the liver with lipogranulomas
- Age-related renal changes with slight pinpoint mineralization
- Age-related pancreatic changes

### INTERPRETATION OF THE FINDINGS & FURTHER RECOMMENDATIONS

Ursodiol therapy could be considered to attempt to dissolve the biliary mineralization yet appears to be minor and not a clinical issue at this time. The spleen was likely in a reactive state on the prior sonogram.





The information and recommendations provided are based on the images presented by the referring veterinarian. No evaluation can be communicated regarding pathology that was not visible in the image/video clips provided.

Thank you for this referral. If the clinical or image interpretation does not parallel your findings or if I can be of any further assistance please contact me.

**Eric Lindquist**, DMV, DABVP, Cert. IVUSS, CEO of SonoPath.com  
info@SonoPath.com