



**PATIENT**

Scully DeNicola

**SPECIES**

Feline

**BREED**

DSH

**SEX**

Spayed Female

**AGE**

17 Years 4 Months

**WEIGHT**

7.43

**INTERPRETED BY**

Eric Lindquist, DMV

DABVP, Cert. IVUSS

**IMAGING PERFORMED BY**

A Murphy, CVT

**HOSPITAL NAME**

Wauwatosa VC

**REFERRING VET**

Dr. Ericka Haynes

**INVOICE**

44236

**DATE**

1/13/23

**PRESENTING CLINICAL SIGNS**

Recent history of vomiting, improved with cerenia. P has a history of chronic kidney disease, Urinary tract infection. Screening for cause of vomiting (i.e. GI tract disease)

Abnormal PE/Chem/CBC/UA Results: CBC- WNL Chem panel - mild azotemia creatinine 2.3 (0.9-2.3) BUN 40 (16-37)

**ULTRASONOGRAPHIC EXAMINATION OF THE ABDOMEN**

**Urinary System**

The **urinary bladder**, trigone, and pelvic urethra presented normal thicknesses and normal tone. The ureters were not visible which is normal. No uroliths or sediment were visualized and anechoic urine was present. No evidence of inflammatory or neoplastic changes were noted. Ureteral papillae were normal. The pelvic urethra was imaged 2.0 cm beyond the cystourethral junction.

The **kidneys** revealed largely normal size and structure, corticomedullary definition and ratio (cortex 1/3 of medulla) were essentially maintained with some age-related loss of curvilinear patterns regarding the capsule and C/M junction. The cortices presented largely uniform texture with some increased echogenicity expected for his age patient. Medullary structure differed distinctly from that of the cortex and no evidence of pelvic dilation was present. The left kidney measured 2.8 cm. The right kidney measured 3.41 cm.

**Adrenal Glands**

Both **adrenal glands** were visualized and recognized as having normal shape, size, position and echogenicity for this breed. The phrenic vasculature, glandular echogenicity and detail were unremarkable. Capsule, cortex, and medullary definition were normal for this age patient. The left adrenal gland measured 0.40 cm. The right adrenal gland measured 0.40 cm.

**Spleen**

The **spleen** in this patient was uniform, yet volume contracted. Hydration status should be assessed.

**Liver**

The **liver** images from right and left intercostal as well as subcostal views revealed subjectively normal liver size, contour, and structure. Some age-related parenchymal remodeling was noted but likely not clinically significant at this time. An anechoic 5.0 mm cyst was noted in the mid crania liver, not pathological. Vascular and biliary tracts were of normal volume and no evidence of congestion was noted. The gallbladder presented some dependent debris with essentially normal contour. The cystic and common bile ducts were normal. No overt evidence of active inflammatory, infiltrative or regenerative pathology was noted but should be paired with current or past LE elevations regarding any clinical significance to this presentation. The hepatic lymph nodes were unremarkable.

**Gastrointestinal**

Examination of the **gastrointestinal tract** revealed a stomach and intestine free of stasis, of normal wall thickness, acceptable curvilinear mural detail, and peristaltic activity. Small and large intestine demonstrated normal luminal chyme and stool consistency respectively. No obstructive or overt infiltrative disease was noted. No associated abnormal lymphatic activity was noted.



**PATIENT**

**Pancreas**

Scully DeNicola

The base and limbs of the **pancreas** were observed to be largely isoechoic to surrounding omental fat. Some parenchymal remodeling, however, with mild deviation from curvilinear normalcy was observed. Pancreatic duct and capsular irregularities were present consistent with age related changes. If pain upon imaging (+ Murphy sign) was present or if the patient is focally painful in subxyphoid palpation then low-grade smoldering chronic pancreatitis should be suspected.

**SPECIES**

Feline

**BREED**

DSH

**ULTRASONOGRAPHIC FINDINGS**

- Non-specific geriatric abdomen with minor subnormal left renal size and mild hepatic remodeling

**SEX**

Spayed Female

**INTERPRETATION OF THE FINDINGS & FURTHER RECOMMENDATIONS**

No evidence of significant disease. Supportive care should prove effective. Both prerenal and renal disease likely playing a role with the azotemia. However, the kidneys do not appear end stage.

**AGE**

17 Years 4 Months

**WEIGHT**

7.43

**INTERPRETED BY**

Eric Lindquist, DMV  
DABVP, Cert. IVUSS

**IMAGING PERFORMED BY**

A Murphy, CVT

**HOSPITAL NAME**

Wauwatosa VC

**REFERRING VET**

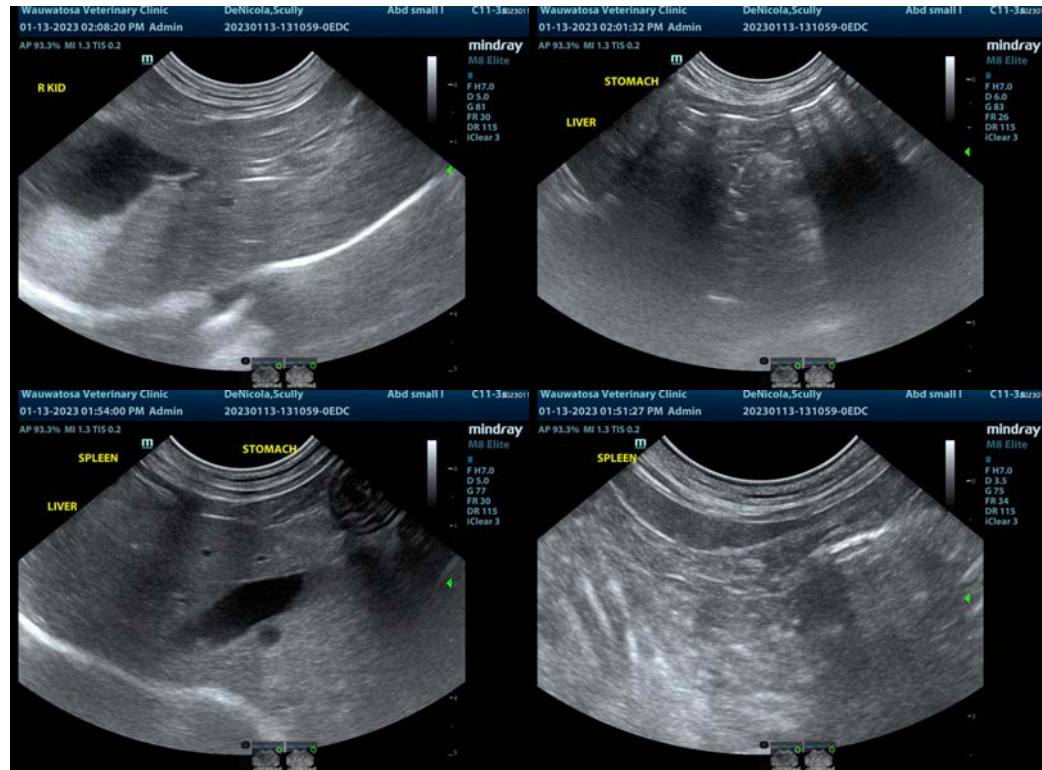
Dr. Ericka Haynes

**INVOICE**

44236

**DATE**

1/13/23





**PATIENT**

Scully DeNicola

**SPECIES**

Feline

**BREED**

DSH

**SEX**

Spayed Female

**AGE**

17 Years 4 Months

**WEIGHT**

7.43

**INTERPRETED BY**

Eric Lindquist, DMV  
DABVP, Cert. IVUSS

**IMAGING PERFORMED BY**

A Murphy, CVT

**HOSPITAL NAME**

Wauwatosa VC

**REFERRING VET**

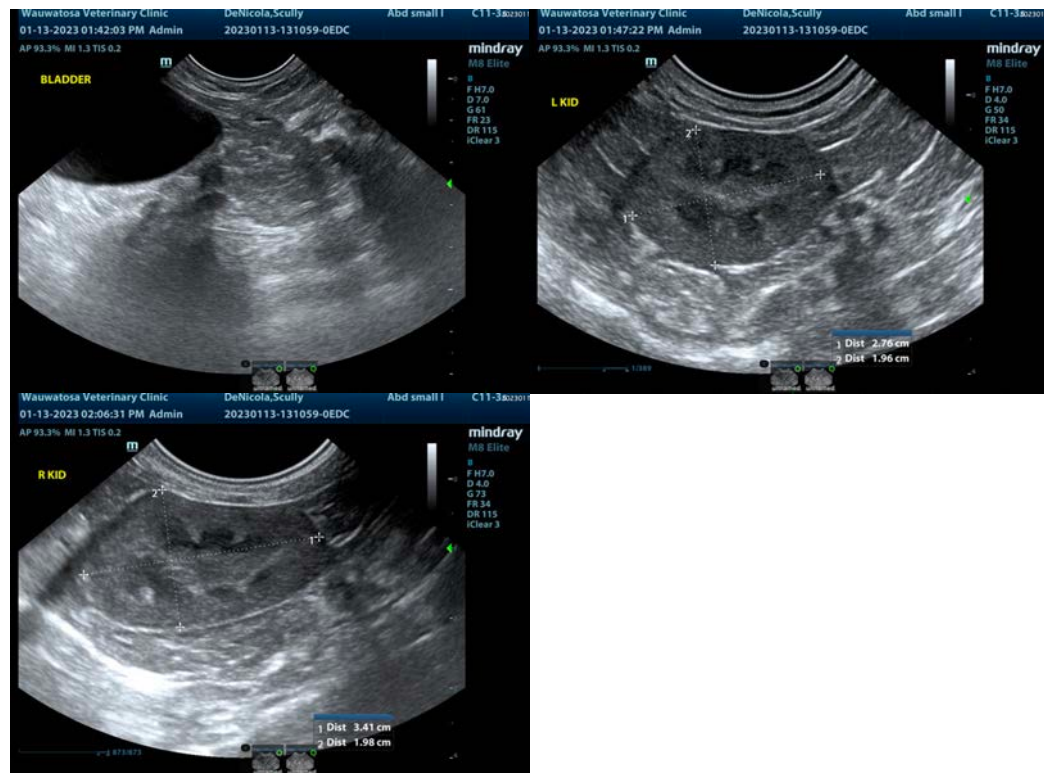
Dr. Ericka Haynes

**INVOICE**

44236

**DATE**

1/13/23



The information and recommendations provided are based on the images presented by the referring veterinarian/sonographer. No evaluation can be communicated regarding pathology that was not visible in the image/video clips provided.

Thank you for this referral. If the clinical or image interpretation does not parallel your findings or if I can be of any further assistance please contact me.

**Eric Lindquist, DMV, DABVP, Cert. IVUSS, CEO of SonoPath.com**

[info@SonoPath.com](mailto:info@SonoPath.com)