

PATIENT

Oliver Tapper
Pickering

SPECIES

Canine

BREED

Labrador mix

SEX

Neutered male

AGE

14 years

WEIGHT

35.6 lbs

INTERPRETED BY

Eric Lindquist,
DMV
DABVP, Cert.
IVUSS

IMAGING PERFORMED BY

Dr. Kicker

HOSPITAL NAME

Wauwautosa VC

PRESENTING CLINICAL SIGNS

History: Grade II/VI left sided systolic murmur auscultated prior to dental prophy. Screening for cause of murmur, anesthetic recommendations.

ULTRASONOGRAPHIC EXAMINATION OF THE HEART

The echocardiogram in this patient demonstrated normal **left atrial** size based on 3 different LA measurement methods. Chamber volumes and echogenicity were normal. Trivial **mitral** valve insufficiency was noted and not clinically significant. The **left ventricle** presented normal thicknesses with linear contour and was not dilated nor restricted. The **myocardium** presented normal echogenicity without subjective evidence of significant fibrotic or ischemic disease. **Contractility** of the ventricular walls was adequate and in normal range for this patient evidenced by the fractional shortening measurement and subjective evaluation of the different regions of the myocardium. The **left ventricular outflow** tract demonstrated normal laminar flow and subjective structural integrity. The **right atrium** and auricle revealed normal size, structure and content. No evidence of masses was noted or chamber overload. **Tricuspid** insufficiency was noted, yet not clinically significant. The **right ventricle** was of normal size (1/3 diameter of LV), chordae structure, myocardial echogenicity and thickness. **Pulmonic** tract assessment revealed normal valve structure, laminar flow, and diameter (approx. 1:1 pa/ao ratio). No visible **pericardial** or free pleura fluid was noted. No echographically detectable evidence of infiltrative disease was visible. The cranial **mediastinum and pericardial regions** were free of masses in the visible window. Occasional arrhythmia was noted in this patient.

CANINE CARDIAC PARAMETERS	MR VMAX (m/s)	TR VMAX (m/s)	LA/AO (Boon method)	LA/AO (Heart Base; Swe)	FS (%)	EF (%)	EPSS (cm)
NORMAL PARAMETER	4.5-5.5	<2.7	1.3	<1.6	28-40	40-100	<0.6
PATIENT			NM	0.92	45	77	0.13
CANINE CARDIAC PARAMETERS	HR (BPM)	AV VMAX (m/s)	PV MAX (m/s)	BODY WEIGHT	LA (2D short axis Base view) (cm)	LVIDd (Avg; 2D and m-mode short axis) (cm)	LVIDs (Avg; 2D and m-mode short axis) (cm)
NORMAL PARAMETER	50-100	0.7-1.7	0.7-1.6	BELOW	BELOW	BELOW	BELOW
PATIENT		2.07	0.64	35.6 lbs	3.8 max	3.6	

REFERRING VET

Dr. Haynes

ULTRASONOGRAPHIC FINDINGS

Minor mitral and tricuspid insufficiency, not clinically significant.

Occasional arrhythmia was noted.

INVOICE

42116

DATE

1/13/23



PATIENT

Oliver Tapper
Pickering

SPECIES

Canine

BREED

Labrador mix

SEX

Neutered male

AGE

14 years

WEIGHT

35.6 lbs

INTERPRETED BY

Eric Lindquist,
DMV
DABVP, Cert.
IVUS

IMAGING PERFORMED BY

Dr. Kicker

HOSPITAL NAME

Wauwatosa VC

REFERRING VET

Dr. Haynes

INVOICE

42116

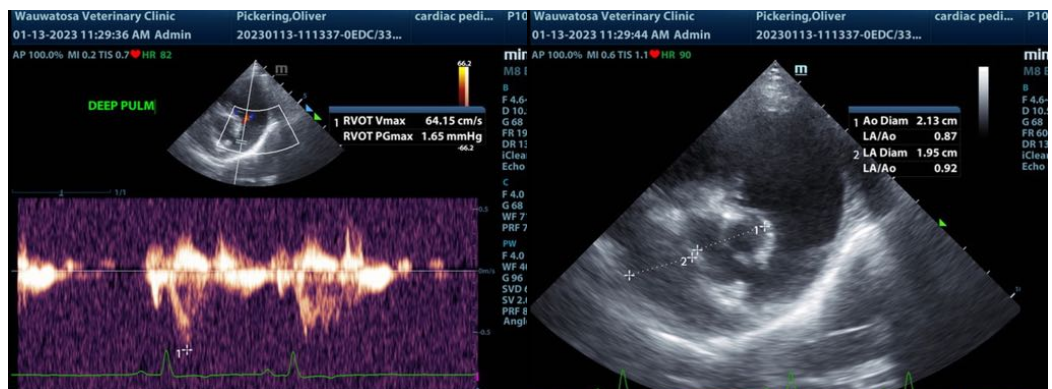
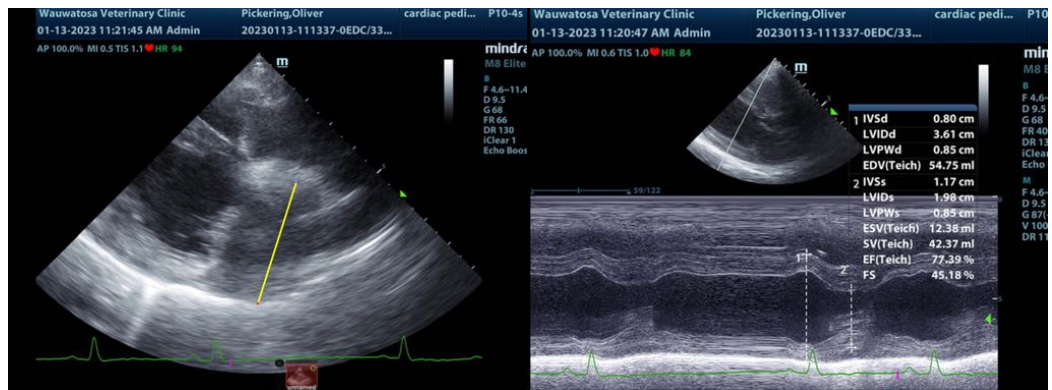
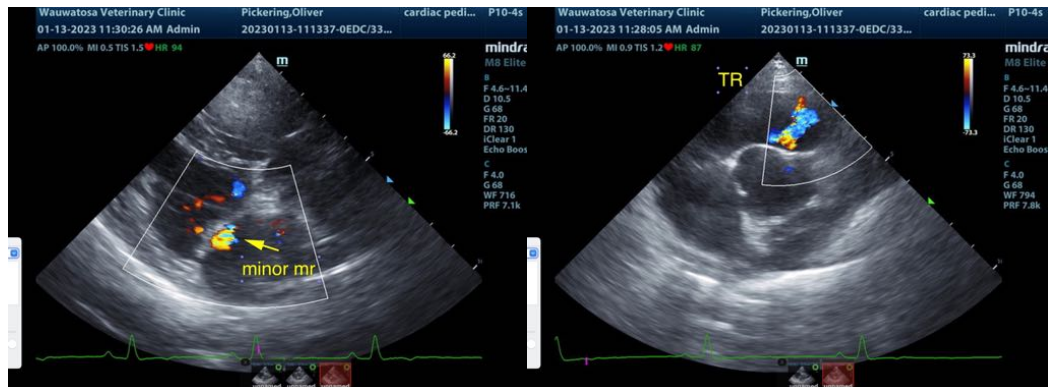
DATE

1/13/23

INTERPRETATION OF THE FINDINGS & FURTHER RECOMMENDATIONS

Structurally and functionally there is no contraindication to anesthetic procedure; however, EKG is indicated prior to anesthesia.

The heart is stable without clinical disease. No overt contraindication for anesthesia of brief to moderate duration. I suggest Torbutrol premed, Propofol induction, Isoflo maintenance or similar protocol if anesthesia is desired. Blood pressure recommended if not already performed and target white coat negative systolic pressure of < 160 mmHg. If higher than this ACE-inhibitor is suggested to reach this level. Recheck echocardiogram is recommended in 6 months, earlier if murmur grade increases or clinical signs initiate.





PATIENT

Oliver Tapper
Pickering

SPECIES

Canine

BREED

Labrador mix

SEX

Neutered male

AGE

14 years

WEIGHT

35.6 lbs

INTERPRETED BY

Eric Lindquist,
DMV
DABVP, Cert.
IVUSS

IMAGING PERFORMED BY

Dr. Kicker

HOSPITAL NAME

Wauwautosa VC

REFERRING VET

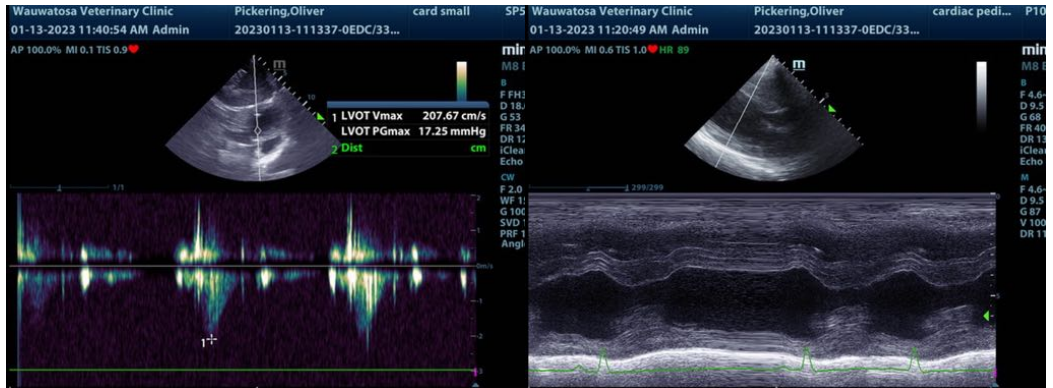
Dr. Haynes

INVOICE

42116

DATE

1/13/23



The information and recommendations provided are based on the images presented by the referring veterinarian/sonographer. No evaluation can be communicated regarding pathology that was not visible in the image/video clips provided.

Thank you for this referral. If the clinical or image interpretation does not parallel your findings or if I can be of any further assistance please contact me.

Eric Lindquist, DMV, DABVP, Cert. IVUSS, CEO of SonoPath.com
info@SonoPath.com