



PATIENT

Kona Bienkowski

PRESENTING CLINICAL SIGNS

Recheck, prev u/s on 1/11 showed full stomach.

SPECIES

Canine

LIMITED ULTRASONOGRAPHIC EXAMINATION

The stomach presented persistent aggressive shadowing material measuring approximately 5.0 cm. The small intestine was empty.

BREED

German Shepherd

ULTRASONOGRAPHIC FINDINGS

- Persistent gastric foreign matter

SEX

Female

INTERPRETATION OF THE FINDINGS & FURTHER RECOMMENDATIONS

Gastrotomy recommended if the patient was NPO at the time of the sonogram.

AGE

5 Months

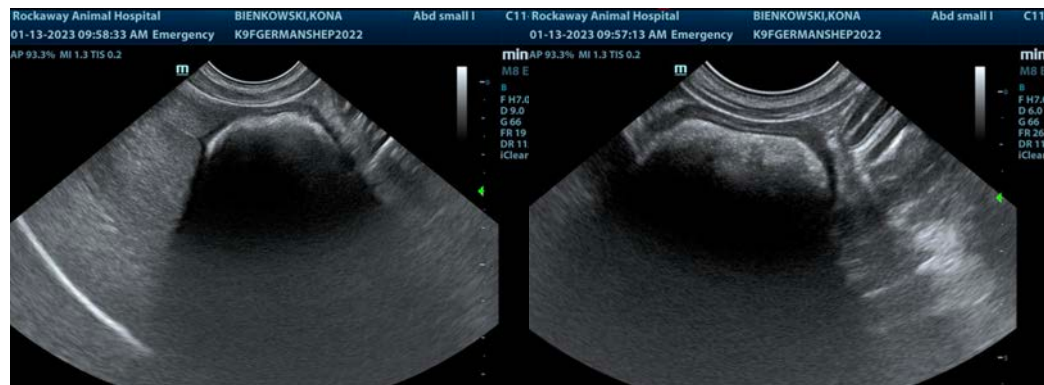
WEIGHT

40

INTERPRETED BY

Eric Lindquist, DMV

DABVP, Cert. IVUSS



IMAGING PERFORMED BY

Jenn

The information and recommendations provided are based on the images presented by the referring veterinarian/sonographer. No evaluation can be communicated regarding pathology that was not visible in the image/video clips provided.

HOSPITAL NAME

Rockaway AH

Thank you for this referral. If the clinical or image interpretation does not parallel your findings or if I can be of any further assistance please contact me.

Eric Lindquist, DMV, DABVP, Cert. IVUSS, CEO of SonoPath.com

info@SonoPath.com

REFERRING VET

Dr. Maniar

INVOICE

44214

DATE

1/13/23