



PATIENT

Daisy Loken

SPECIES

Canine

BREED

Maltese Mix

SEX

Spayed Female

AGE

14 Years

WEIGHT

14.6 Pounds

INTERPRETED BY

Eric Lindquist, DMV,
DABVP, Cert. IVUSS

IMAGING PERFORMED BY

Jenna Walsh, CVT

HOSPITAL NAME

Amazon Park AC

REFERRING VET

Dr. Jones

DATE

1/13/23

Invoice

20549

PRESENTING CLINICAL SIGNS

History: Presented for dental under anesthesia, generally healthy older dog with periodontal disease. Anesthesia delayed until more information on her liver is available. Blood pressures taken - systolic 145, diastolic 100, MAP 115 (average of three). Primary Question/Differential to Be Answered in This Exam What is the appearance of the liver? Are the adrenal glands enlarged? Hyperadrenocorticism is highly suspected.

Abnormal PE/Chem/CBC/UA Results: ALP 1481 (23-212), ALT 140 (10-125, globulin 4/7 (2.5-4.5), platelets 974,000.

ULTRASONOGRAPHIC EXAMINATION OF THE ABDOMEN

Urinary System

The **urinary bladder**, trigone, and pelvic urethra presented normal thicknesses and normal tone. The ureters were not visible which is normal. No uroliths or sediment were visualized, and anechoic urine was present. No evidence of inflammatory or neoplastic changes were noted. Ureteral papillae were normal.

The **kidneys** revealed largely normal size and structure, corticomedullary definition and ratio (cortex 1/3 of medulla) were essentially maintained with some mild age-related loss of curvilinear patterns regarding the capsule and C/M junction. The cortices presented largely uniform texture with some increased echogenicity expected for his age patient. Medullary structure differed distinctly from that of the cortex and no evidence of pelvic dilation was present. Slight anechoic cyst was noted, measuring 4.0 mm at the cranial pole of the right kidney. The right kidney measured 5.36 cm. The left kidney measured 4.61 cm.

Adrenal Glands

The **left adrenal gland** revealed an expansive cranial pole. The left adrenal gland measured 0.84 cm at the cranial pole and 0.63 cm at the caudal pole (normal caudal pole) x 1.85 cm in length.

The **right adrenal gland** was enlarged, irregular and nodular, measuring 2.19 cm x 0.89 cm at maximum width. Capsular expansion was noted without capsular escape or vascular invasion.

Spleen

The **spleen** was normal size and relatively normal contour with multifocal hyperechoic areas of mineralization. This is a benign change; however, can be related to Cushing's disease or other endocrinopathies.

Liver

The **liver** was uniformly swollen. The liver presented coarse architecture with mildly increased portal markings and subtle, mixed echogenic changes. This is consistent with vacuolar hepatopathy and some level of remodeling and history of inflammatory component. There was no overt suspicion of neoplasia. This is a mild change. Occasional parenchymal cysts were noted, not pathological.



PATIENT

The **gallbladder** was mildly over distended with suspended and dependent debris, yet no evidence of mucocele formation, yet sludge appears to be mildly excessive. Minor gallbladder polyps were noted.

Daisy Loken

SPECIES

Gastrointestinal

Canine

Examination of the **gastrointestinal tract** revealed a stomach and intestine free of stasis, of normal wall thickness, acceptable curvilinear mural detail, and peristaltic activity. Small and large intestine demonstrated normal luminal chyme and stool consistency respectively. No obstructive or overt infiltrative disease was noted. No associated abnormal lymphatic activity was noted.

BREED

Maltese Mix

Pancreas

SEX

The base and limbs of the **pancreas** were observed to be largely isoechoic to surrounding omental fat. Pancreatic duct and capsular contour were acceptably normal and parenchyma respected normal curvilinear patterns. No overt evidence of active inflammatory or neoplastic disease was noted.

Spayed Female

AGE

14 Years

- Bilateral adrenal hypertrophy with nodular changes. This is likely PDH, however, particularly the right adrenal should be monitored for potential emergence of a neoplastic event. Bilateral hyperplasia, adenomatous changes are likely, potential emerging pheochromocytoma or adenocarcinoma in either adrenal could be considered, however, not typical.

WEIGHT

14.6 Pounds

- Benign hepatopathy with minor remodeling

INTERPRETED BY

Eric Lindquist, DMV,
DABVP, Cert. IVUSS

- Gallbladder sludge
- Splenic mineralization
- Age-related renal changes with right kidney cyst

IMAGING PERFORMED BY

Jenna Walsh, CVT

HOSPITAL NAME

Amazon Park AC

INTERPRETATION OF THE FINDINGS & FURTHER RECOMMENDATIONS

If urine specific gravity is <1.020, then work up for Cushings is indicated. No overt contraindication to anesthetic procedure. Bile acid profile could be considered for further definition to assess for dysfunction, yet not suspected. Recheck sonogram is recommended in 6 weeks, regarding the adrenal presentation. Ursodiol therapy could be justified as a palliative measure, regarding the hepatic presentation.

REFERRING VET

Dr. Jones

Cushing Work UP

Efficient & Accurate Cushing's Work up-Lindquist

Notes regarding Cushing's Clinical Presentations:

DATE

1/13/23

Nearly all Cushing's dogs have SAP elevations and true PU/PD (USG < 1.025) and most are polyphagic. Cushing's dogs are > 6 years and usually > 9 years old, usually have poor skin coats, body scores > 3/5, and are usually sedentary animals.

Invoice

20549



PATIENT

Daisy Loken

SPECIES

Canine

BREED

Maltese Mix

SEX

Spayed Female

AGE

14 Years

WEIGHT

14.6 Pounds

INTERPRETED BY

Eric Lindquist, DMV,
DABVP, Cert. IVUSS

IMAGING PERFORMED BY

Jenna Walsh, CVT

HOSPITAL NAME

Amazon Park AC

REFERRING VET

Dr. Jones

DATE

1/13/23

Invoice

20549

Its important to remember that Cushing's dogs usually look and play the part and other diseases cause false + stress related cortisol spikes. On rare occasion a Cushing's dog will not follow the rules but this is truly an exception.

Potential Cushing's patient workups can be costly and frustrating if not definitive and, in my experience, the non-definitive patient usually has something else going on that may be contributing to some of the clinical signs a Cushing's dog will have, especially SAP elevations or PU/PD. Based on this prelude of information I came up with the following algorithm in the spirit of diagnostic efficiency.

The following suggested protocol is based on current available literature on Cushing's disease and extensive clinical-sonographic experience evaluation + Cushing's and False + LDDST & ACTH stim. cases in order to maximize the efficiency of a Cushing's workup in practice.

Screen first, workup second

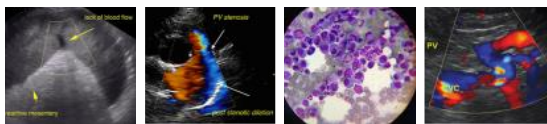
1) **UA:** Repeatable (2-3 urine samples) Urine specific gravity & urine cortisol/creatinine ratio (UCCR): If **repeatable USG < 10.20 and + UCCR** move to next step 2.

Note: UA is inexpensive and easy to obtain and if UA criteria is not met for Cushing's then resources can be spent into other more pertinent diagnostics or left on hold until the UA criteria is met in emerging Cushing's cases.

2) **Sonogram:** Does the patient **have concurrent disease** clinically or sonographically as non-Cushing's illness will influence the potential false + LDDST or even ACTH stim. The sonogram gives a global perspective of the internal health of the patient to be considered in the Cushing's workup as an assessment of concurrent disease. Is there a concurrent neoplastic process, UTI pancreatitis, mucocele....? Are the adrenals enlarged (Cushing's-PDH, stress, age related or breed variant), or atrophied (iatrogenic Cushing's or adrenal burnout), have asymmetric enlargement (Adrenal tumor, hyperplasia, adenoma, age related variant), or is there vascular invasion (Invasive pheno with false + UA criteria or adenocarcinoma or phrenic thrombosis)? The sonogram answers these questions proactively.

Address & treat concurrent disease first before performing Cushing's testing or testing will be artificially altered increasing false negatives and positives.

3) **LDDST** (0.01 D-Sodium phosphate mg/kg IV **with precise dosing******) (Better screening test but plagued with false + but considered more specific than ACTH stim) Use if there is potential early Cushing's or if adrenal asymmetry present on sonogram suspecting tumor. Use LDDST in cats at a higher dose (0.1 mg/kg IV). **Interpretation LDDST:** Look at 8-hour post first: If > 1.4 = Cushing's. Then look at 4-hour: if > 1.4 or > 50% baseline = Cushing's. 4-hour do then 8-hour spike most consistent with PDH. Flat line high constant curve without dip more consistent with tumor but can be PDH. See attached graph.



PATIENT

Daisy Loken

SPECIES

Canine

BREED

Maltese Mix

SEX

Spayed Female

AGE

14 Years

WEIGHT

14.6 Pounds

INTERPRETED BY

Eric Lindquist, DMV,
DABVP, Cert. IVUSS

IMAGING PERFORMED BY

Jenna Walsh, CVT

HOSPITAL NAME

Amazon Park AC

REFERRING VET

Dr. Jones

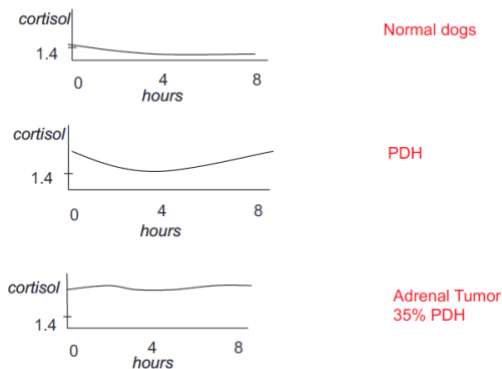
DATE

1/13/23

Invoice

20549

LDDS



Courtesy: Rebecca Berg DACVIM, DECVIM

4) **ACTH stim.** (Better confirming test but can have false +) Use if the patient "looks" Cushingoid or if bilateral adrenal enlargement is present, or high normal width on sonogram, or if iatrogenic Cushing's suspected (Cortisone Tx in past). ACTH stim is better for diagnosis of Addisons, Iatrogenic Cushing's, and Cushing's therapy monitoring but problematic with initial Cushing's diagnosis. First dx LDDST is suggested.

5) If **diabetic** then run both LDDST & ACTH stim but stabilize as much as possible first.

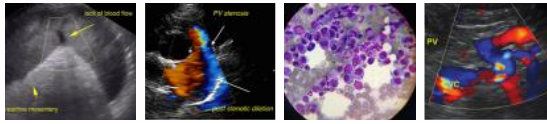
5) Run a **serial blood pressure** in a BP friendly non "white coat effect" atmosphere. Run at least 3 at different times over a few hours or when eating as the patient tends to be calm when eating or give Torbutrol when entering the facility. Cushing's hypertension is usually 150-180 systolic range while pheochromocytoma range is more often > 180 systolic.

6) **Perform CT** of the pituitary to identify macro adenoma expansion if any lethargy or dullness or other central clinical CNS signs are minimally present. CT for adrenal may be more thorough for adrenalectomy surgical planning if ultrasound views of the CVC were problematic.

7) **Adrenalectomy** for adrenal mass is prescribed then it is essential to stabilize the patient first regarding secondary disease such as organ dysfunction, hypertension, diabetes mellitus, hypernatremia, thromboembolic risk urinary and other infection in order to minimize potential for operative and postoperative complications as they are common in adrenalectomy. Trilostane stabilization therapy for Cushing's would be the first approach then address surgery and hypertension should be managed ideally < 160 systolic with ace inhibitors, phenoxybenzamine, or amlodipine.

Suggested reading:

Behrend EN, Kooistra HS, Nelson R, et al. Diagnosis of Spontaneous Canine Hyperadrenocorticism: 2012 ACVIM Consensus Statement (Small Animal). J Vet Intern Med 2013;27:1292-1304



PATIENT

Daisy Loken

SPECIES

Canine

BREED

Maltese Mix

SEX

Spayed Female

AGE

14 Years

WEIGHT

14.6 Pounds

INTERPRETED BY

Eric Lindquist, DMV,
DABVP, Cert. IVUSS

IMAGING PERFORMED BY

Jenna Walsh, CVT

HOSPITAL NAME

Amazon Park AC

REFERRING VET

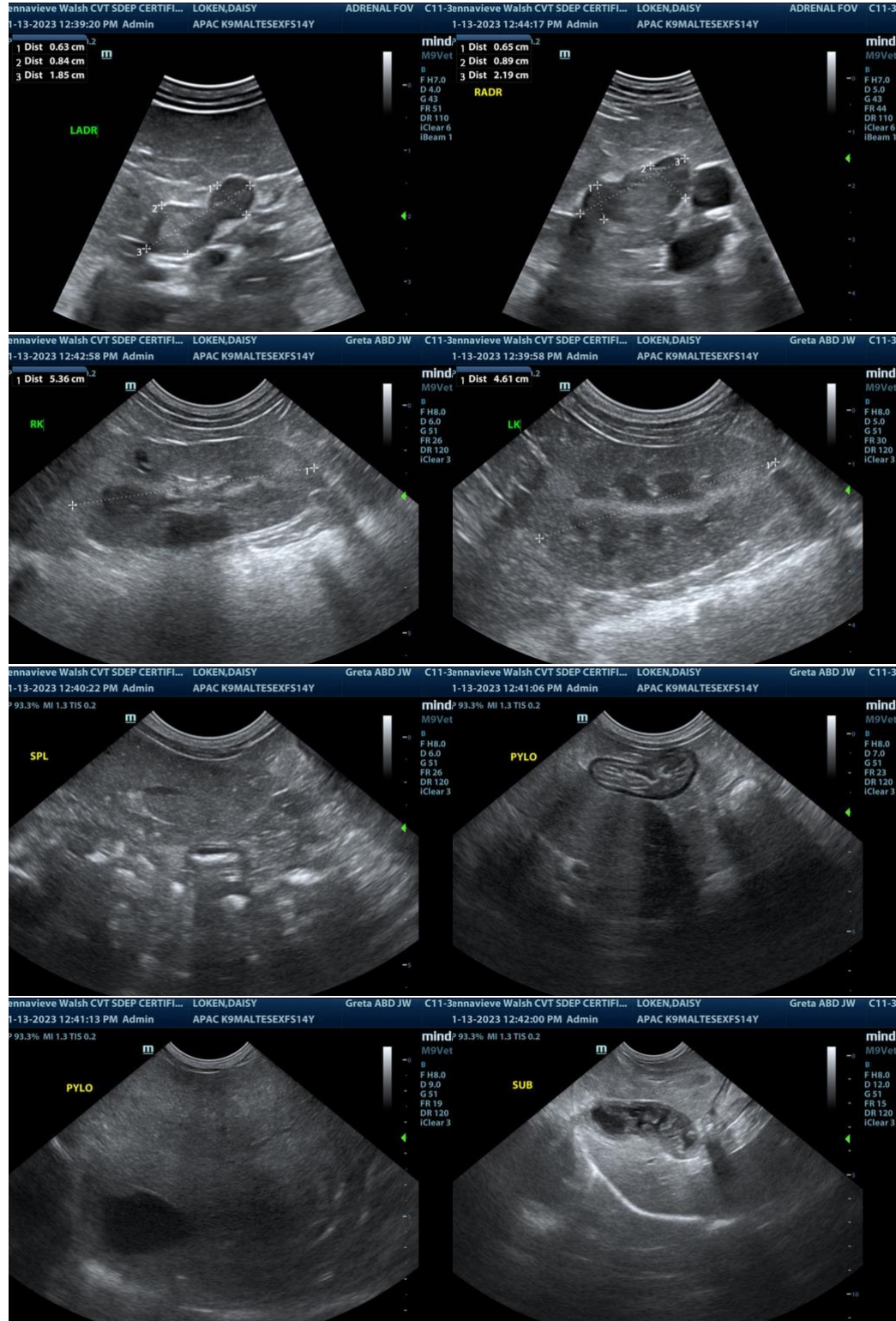
Dr. Jones

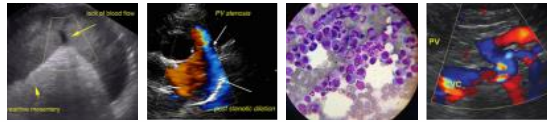
DATE

1/13/23

Invoice

20549





PATIENT

Daisy Loken

SPECIES

Canine

BREED

Maltese Mix

SEX

Spayed Female

AGE

14 Years

WEIGHT

14.6 Pounds

INTERPRETED BY

Eric Lindquist, DMV,
DABVP, Cert. IVUSS

IMAGING PERFORMED BY

Jenna Walsh, CVT

HOSPITAL NAME

Amazon Park AC

REFERRING VET

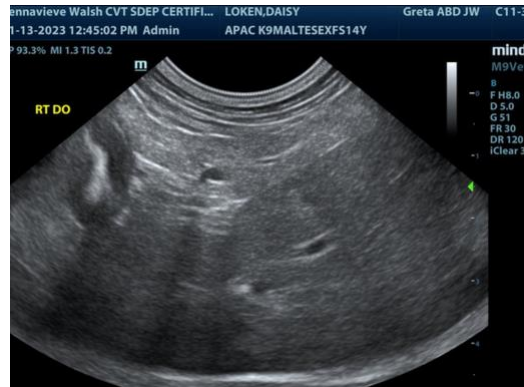Dr. Jones

DATE

1/13/23

Invoice

20549



The information and recommendations provided are based on the images presented by the referring veterinarian. No evaluation can be communicated regarding pathology that was not visible in the image/video clips provided.

Thank you for this referral. If the clinical or image interpretation does not parallel your findings or if I can be of any further assistance please contact me.

Eric Lindquist, DMV, DABVP, Cert. IVUSS, CEO of SonoPath.com

info@SonoPath.com