



DATE PRESENTING CLINICAL SIGNS

1/13/22 History: Raleigh is a 13 yr old, FS, Golden Retriever. She has lost ~15 pounds over the last year. Bloodwork was unremarkable 3/19/21. She has a urinalysis pending to rule out a UTI. Chronic Otitis Externa.

PATIENT

Raleigh DeStafano

Current Medications: BNT ointment in ears. No other medications at this time.
Lab Results: Mildly elevated Chol, 323. No other abnormalities. Done at emergency clinic 3/19/21.
Radiographs: Abdominal radiographs performed at an emergency clinic 3/19/21 and they noted hepatomegaly.

SPECIES

Canine

Date of Previous IntraPet Ultrasound: No previous IntraPet scans.
Sedation: Dexdomitor/Torbugesic. DVM approved.
Stat Report: Not requested.

BREED

Golden Retriever

ULTRASONOGRAPHIC EXAMINATION OF THE ABDOMEN

Urinary System

SEX

Spayed Female

The **urinary bladder**, trigone, and pelvic urethra presented normal thicknesses and normal tone. The ureters were not visible which is normal. No uroliths or sediment were visualized and anechoic urine was present. No evidence of inflammatory or neoplastic changes were noted. Ureteral papillae were normal.

AGE

12/11/08

The **kidneys** revealed normal size and structure, corticomedullary definition and ratio for this age. The cortices presented largely uniform texture with normal echogenic relationship to liver and spleen. Medullary structure differed distinctly from the cortex and no evidence of pelvic dilation was present. The capsules were acceptably uniform without significant irregularities. The right kidney measured 6.76 cm. The left kidney measured 6.8 cm.

WEIGHT

58.1 Pounds

Adrenal Glands

INTERPRETED BY

Eric Lindquist, DMV
DABVP, Cert. IVUSS

Both **adrenal glands** were visualized and recognized as having normal shape, size, position and echogenicity for this breed. The phrenic vasculature, glandular echogenicity and detail were unremarkable. Capsule, cortex, and medullary definition were normal for this age patient. The left adrenal gland measured 3.5 cm x 0.7 cm at the caudal pole and 0.8 cm at the cranial pole.

IMAGING PERFORMED BY

Stephanie Pearce
RDCS, RVT

Spleen

The **spleen** was folded upon itself and mildly heterogeneous. FNA warranted from a screening standpoint.

HOSPITAL NAME

Severna Park AH

Liver

The **liver** revealed a left cranial mixed hyperechoic nodule measuring 3.77 cm x 2.5 cm, deviating the diaphragm. Ultrasound guided FNA indicated. The gallbladder was unremarkable.

REFERRING VET

Dr. Todd

Gastrointestinal

Examination of the **gastrointestinal tract** revealed a stomach and intestine free of stasis, of normal wall thickness, acceptable curvilinear mural detail, and peristaltic activity. Small and large intestine demonstrated normal luminal chyme and stool consistency respectively. No obstructive or overt infiltrative disease was noted. No associated abnormal lymphatic activity was noted.

INVOICE

34238

Pancreas

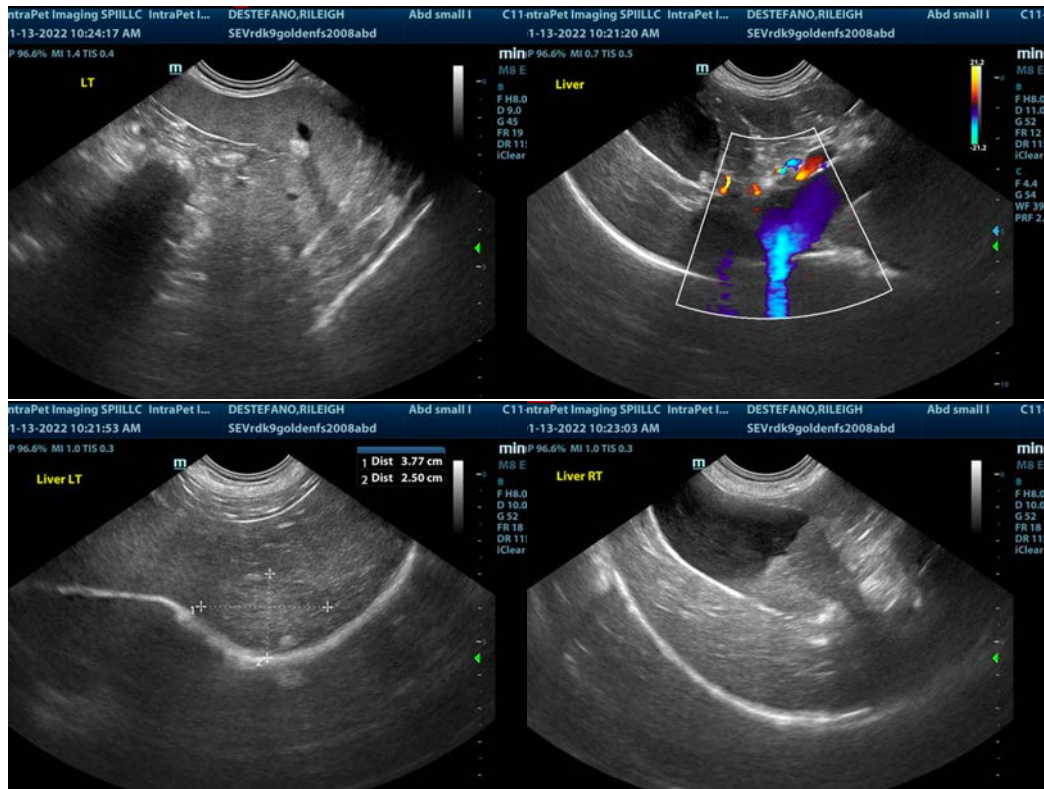
The base and limbs of the **pancreas** were observed to be largely isoechoic to surrounding omental fat. Pancreatic duct and capsular contour were acceptably normal and parenchyma respected normal curvilinear patterns. No overt evidence of active inflammatory or neoplastic disease was noted.

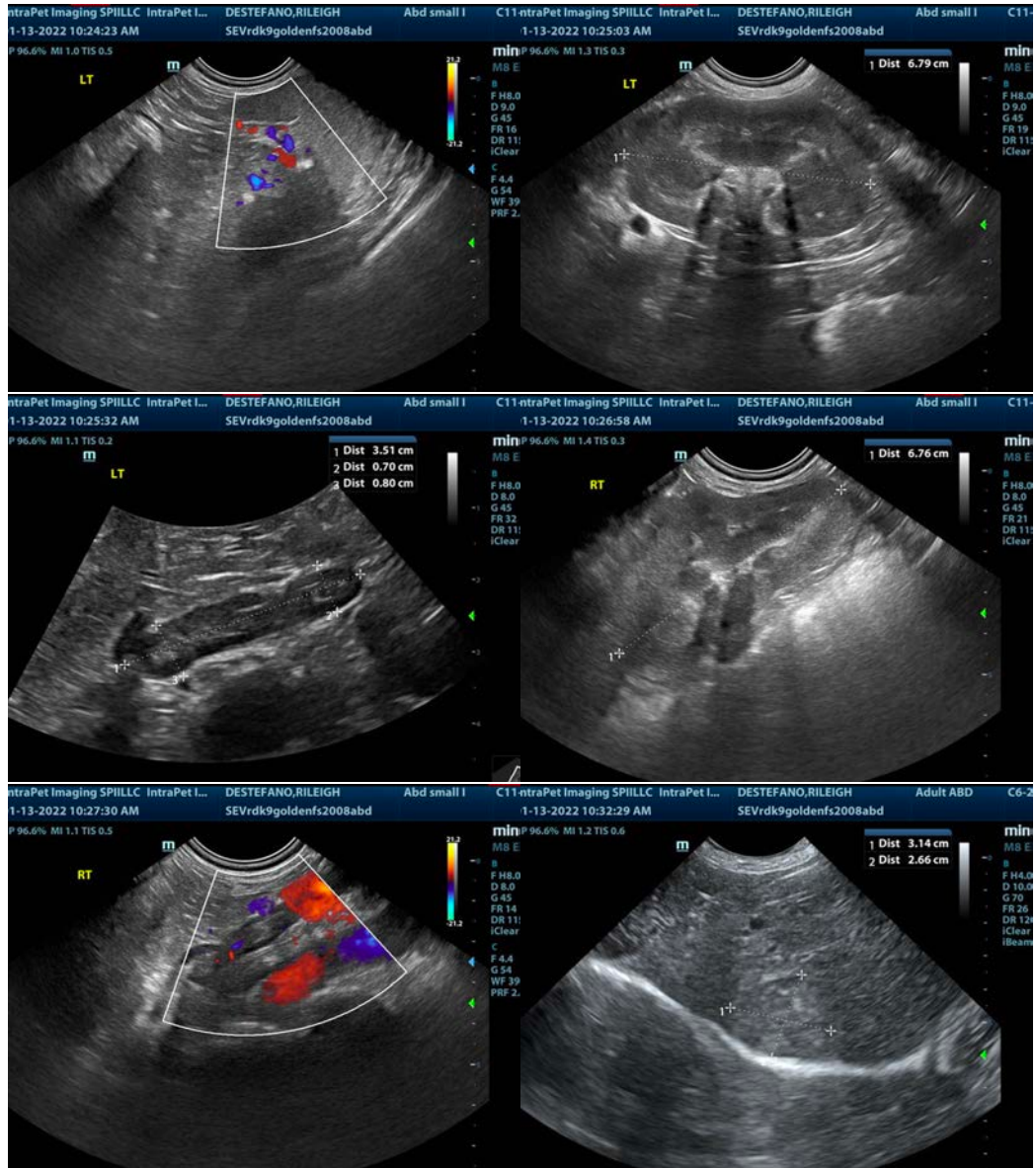
ULTRASONOGRAPHIC FINDINGS

- Nodular liver - Nodular hyperplasia versus emerging round cell neoplasia, may be related to underlying weight loss. However, by itself is unlikely to be a primary cause. Further investigation recommended.
- Nodular spleen

INTERPRETATION OF THE FINDINGS & FURTHER RECOMMENDATIONS

FNA of the spleen and liver recommended. However, these may be completely benign and unrelated to the clinical history. Maldigestion panel, three view chest radiographs and full CNS examination is recommended to examine for occult disease that could be responsible for the weight loss. Evaluation for competitive eating environments should also be considered.





The information and recommendations provided are based on the images presented by the referring veterinarian. No evaluation can be communicated regarding pathology that was not visible in the image/video clips provided.

Thank you for this referral. If the clinical or image interpretation does not parallel your findings or if I can be of any further assistance please contact me.

Eric Lindquist, DMV, DABVP, Cert. IVUSS, CEO of SonoPath.com
info@SonoPath.com