**DATE**

1/13/22

PRESENTING CLINICAL SIGNS

History: 1/10/22- o reports pt not to a vet in ~3years but has lost 5lbs with decreased appetite, and decreased activity. Has recently moved and a new dog in house but indoor only and NO vomiting or diarrhea. PE-BAR w/vitals WNL's but pale-yellow mm's.

PATIENT

Lucy Maddox

Lab Results: BW- >T.bili=9.2mg/dL, >ALP=160.

Date of Previous IntraPet Ultrasound: No previous IntraPet scans.

Sedation: Not required to complete full diagnostic ultrasound.

Stat Report: Not requested.

Imaging Performed By: Stephanie Pearce RDCS, RVT.

SPECIES

Feline

ULTRASONOGRAPHIC EXAMINATION OF THE ABDOMEN**BREED**

Domestic Shorthair

Urinary System

The **urinary bladder**, trigone, and pelvic urethra presented normal thicknesses and normal tone. The ureters were not visible which is normal. No uroliths or sediment were visualized and anechoic urine was present. No evidence of inflammatory or neoplastic changes was noted. Ureteral papillae were normal.

SEX

Spayed Female

The **right kidney** revealed multi-focal cortical infarcts with mineralization. There was no evidence of active inflammation. The right kidney measured 2.24 cm. The **left kidney** revealed slight cortical infarct in the caudal pole with non-obstructive corticomedullary mineralization. The left kidney measured 3.65 cm.

AGE

1/15/13

Adrenal Glands

Both **adrenal glands** were visualized and recognized as having normal shape, size, position and echogenicity for this breed. The phrenic vasculature, glandular echogenicity and detail were unremarkable. Capsule, cortex, and medullary definition were normal for this age patient. The right adrenal gland measured 0.32 cm. The left adrenal gland measured 0.37 cm.

WEIGHT

10.5 lbs

INTERPRETED BYEric Lindquist, DMV
DABVP, Cert. IVUSS**Spleen**

The **spleen** presented a smooth homogeneous parenchyma hyperechoic to liver and renal cortical parenchyma. The capsule was smooth without noticeable expansion or deviation from within the spleen or adjacent pathology. The splenic vasculature demonstrated normal volume without signs of congestion or thrombosis. No sonographic evidence of acute or chronic inflammatory, neoplastic, or infarctual changes was noted. The spleen measured 0.7 cm in width.

HOSPITAL NAME

Alexander AH

Liver

The **liver** was diffusely hyperechoic to the falciform fat with generalized enlargement. The gallbladder and common bile duct were unremarkable.

REFERRING VET

Dr. Alexander

Gastrointestinal**INVOICE**

95232

The **gastrointestinal** presentation revealed mild uniform prominence of the gastric mucosa as well as areas of "ropey" small intestinal wall with slight disruption of the normal 1:3 muscularis/mucosal ratio. The intestinal submucosa was slightly irregular, thickened and hyperechoic suggestive of low grade, chronic disease. Intestinal wall thickness measured 0.22 cm. No concerning lymphadenopathy was visible. No evidence of obstruction was present. Chronic inflammatory bowel disease is likely with a low possibility of an early neoplastic event such as lymphoma. Full thickness tissue biopsies via open laparotomy, ideally guided by intraoperative ultrasound in order to obtain the most representative mural sample, would be necessary to rule out this possibility.

Pancreas

Slight, hyperechoic changes were noted in the pancreas. These are likely lipogranulomas or remodeling from prior episodes of pancreatitis.

Free Abdomen

A large amount of abdominal fat was noted in this patient.

ULTRASONOGRAPHIC FINDINGS

Dystrophic right kidney with infarcts and calculi, moderate on the right and mild on the left.

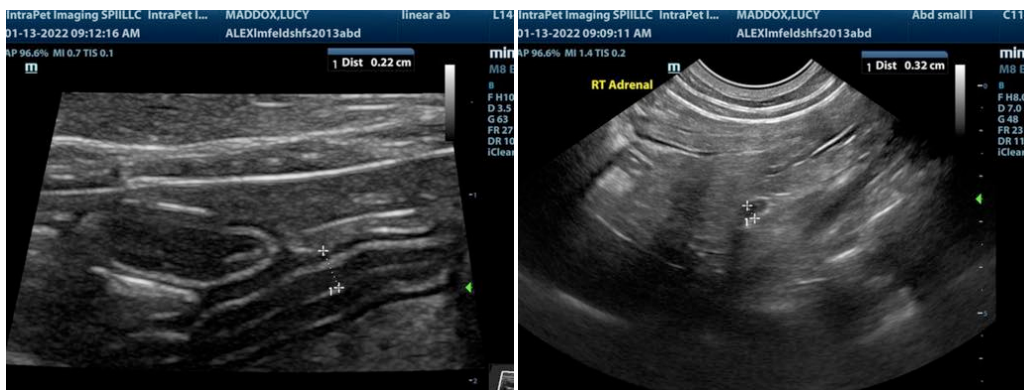
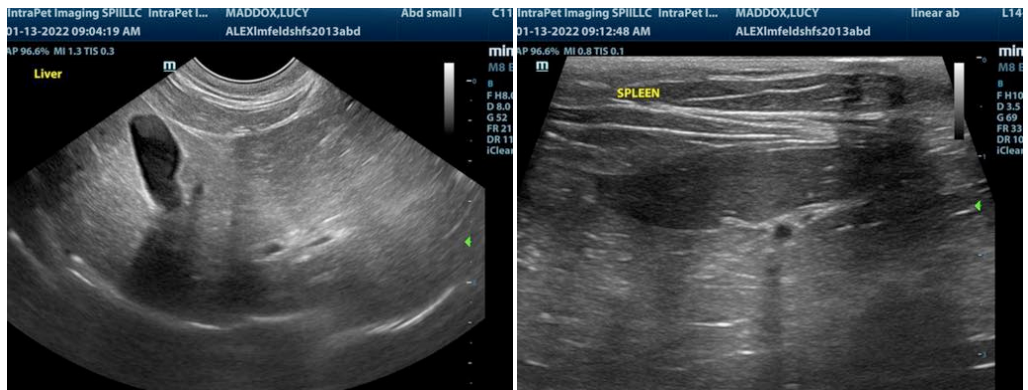
Hepatic lipidosis pattern.

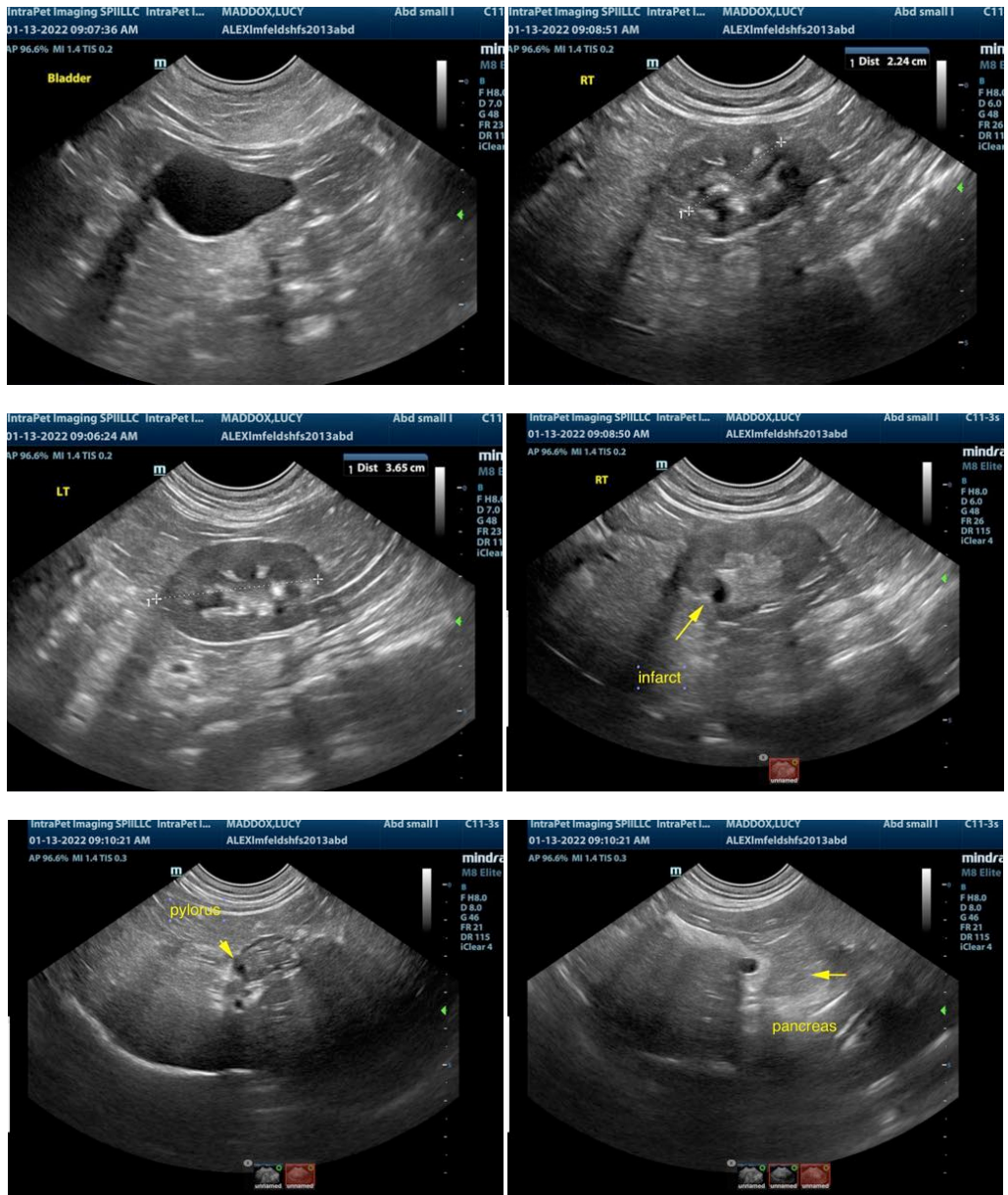
Lipogranuloma sin the pancreas or remodeling from prior episodes of pancreatitis.

INTERPRETATION OF THE FINDINGS & FURTHER RECOMMENDATIONS

FNA of the liver is warranted to confirm. There is a mild potential for underlying hepatic lymphoma. Full urinary work-up is warranted if not already performed. The cause of weight loss is unclear unless cytology of the liver reveals underlying lymphoma. Renal palpation is recommended to assess for any discomfort associated with the kidneys. Subxiphoid palpation is recommended to assess for any current discomfort.

Maldigestion panel, three view chest radiographs and full CNS examination is recommended to examine for occult disease that could be responsible for the weight loss. Evaluation for competitive eating environments should also be considered.





The information and recommendations provided are based on the images presented by the referring veterinarian. No evaluation can be communicated regarding pathology that was not visible in the image/video clips provided.

Thank you for this referral. If the clinical or image interpretation does not parallel your findings or if I can be of any further assistance please contact me.

Eric Lindquist, DMV, DABVP, Cert. IVUSS, CEO of SonoPath.com
Eric.Lindquist@SonoPath.com