

**DATE PRESENTING CLINICAL SIGNS**

1/13/22 History: About 3-week history of urinary incontinence after defecating especially if she has to strain to defecate. Otherwise seems ok. Seems to have a good stream while urinating. Eating and acting ok otherwise. Rads taken revealed no radio opaque stones, but bladder did have a hazy appearance.

PATIENT

Clementine Reid

Lab Results: CBC- high eos 1577. Profile- wnl. U/A- SG 1.045, pH 8, WBC 1-3, rare struvite crystals. Radiographs: Attached separately.

SPECIES

Canine

Date of Previous IntraPet Ultrasound: No previous IntraPet scans.
Sedation: Not required to complete full diagnostic ultrasound.
Stat Report: Not requested.

BREED

Labrador Retriever

ULTRASONOGRAPHIC EXAMINATION OF THE ABDOMEN**Urinary System****SEX**

Spayed Female

The **urinary bladder**, trigone, and pelvic urethra presented normal thicknesses and normal tone. The ureters were not visible which is normal. No uroliths or sediment were visualized and anechoic urine was present. No evidence of inflammatory or neoplastic changes were noted. Ureteral papillae were normal.

AGE

1/1/18

The **kidneys** revealed normal size and structure, corticomedullary definition and ratio for this age. The cortices presented largely uniform texture with normal echogenic relationship to liver and spleen. Medullary structure differed distinctly from the cortex and no evidence of pelvic dilation was present. The capsules were acceptably uniform without significant irregularities. The right kidney measured 6.39 cm.

WEIGHT

57 Pounds

Adrenal Glands**INTERPRETED BY**Eric Lindquist, DMV
DABVP, Cert. IVUSS

Both **adrenal glands** were visualized and recognized as having normal shape, size, position and echogenicity for this breed. The phrenic vasculature, glandular echogenicity and detail were unremarkable. Capsule, cortex, and medullary definition were normal for this age patient. The right adrenal gland measured 2.6 cm x 0.76 cm at the caudal pole and 0.79 cm at the cranial pole. The left adrenal gland measured 2.85 cm x 0.73 cm at the caudal pole and 0.56 cm at the cranial pole.

IMAGING PERFORMED BYStephanie Pearce
RDMS, RVT**Spleen**

The **spleen** presented a smooth homogeneous parenchyma hyperechoic to liver and renal cortical parenchyma. The capsule was smooth without noticeable expansion or deviation from within the spleen or adjacent pathology. The splenic vasculature demonstrated normal volume without signs of congestion or thrombosis. No sonographic evidence of acute or chronic inflammatory, neoplastic, or infarctual changes were noted.

HOSPITAL NAME

Healing Paws VWC

Liver

The **liver** images submitted revealed subjectively normal liver size, contour, and structure. Parenchymal echogenicity was naturally coarse and hypoechoic to the spleen. Vascular and biliary tracts were of normal volume with no evidence of congestion. The gallbladder presented acceptably thin walls with primarily anechoic content. The cystic and common bile ducts were normal. No pathological hepatic lymphadenopathy was evident. No overt structural evidence of inflammatory, infiltrative or regenerative pathology was evident.

REFERRING VET

Dr. Levitsky

INVOICE

34233

Gastrointestinal

Examination of the **gastrointestinal tract** revealed a stomach and intestine free of stasis, of normal wall thickness, acceptable curvilinear mural detail, and peristaltic activity. The colon presented normal stool and mural structure.

Pancreas

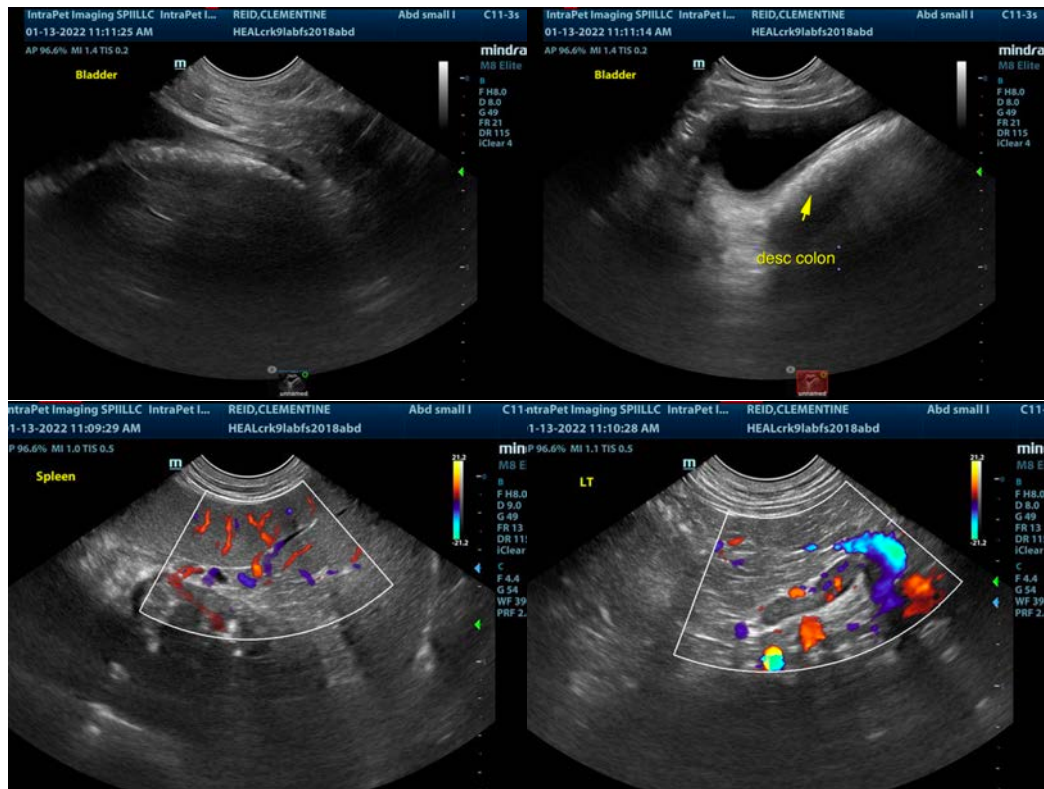
The base and limbs of the **pancreas** were observed to be largely isoechoic to surrounding omental fat. Pancreatic duct and capsular contour were acceptably normal and parenchyma respected normal curvilinear patterns. No overt evidence of active inflammatory or neoplastic disease was noted.

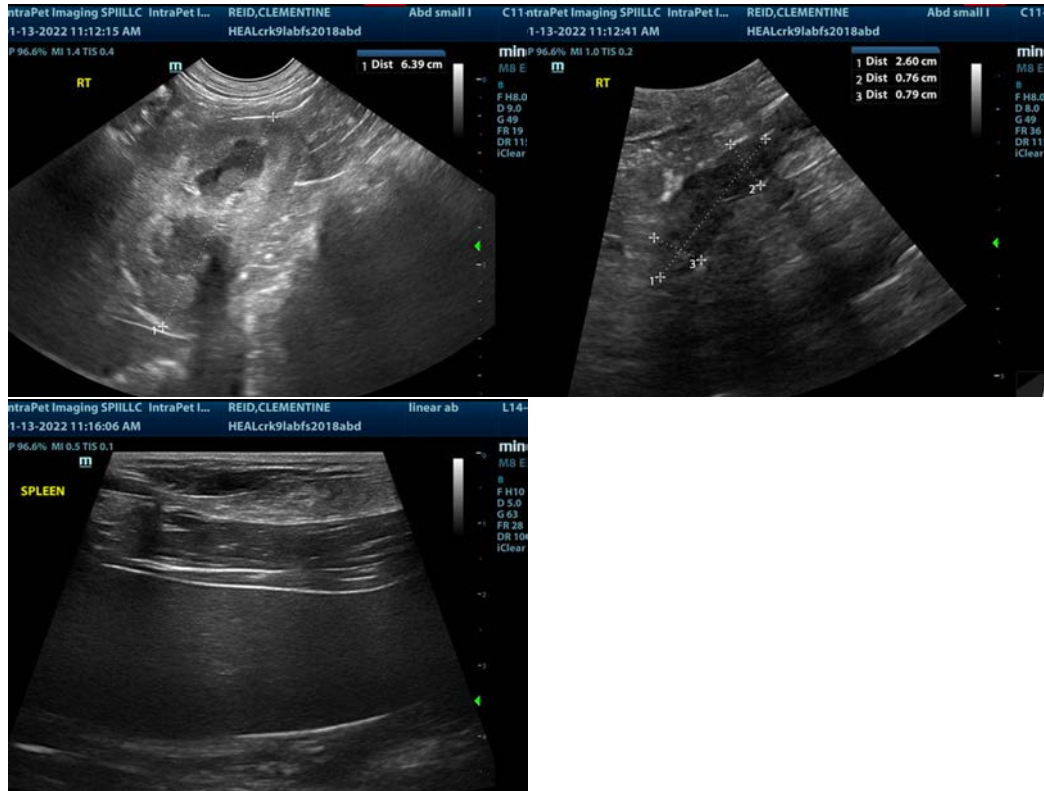
ULTRASONOGRAPHIC FINDINGS

- Structurally unremarkable abdomen

INTERPRETATION OF THE FINDINGS & FURTHER RECOMMENDATIONS

Lumbosacral disease, anal gland disease, or colorectal disease should be considered. Manual palpation of the colorectum recommended if not already performed. However, structurally, no evidence of pathology from an abdominal and deep pelvic urethral/colonic approach.





The information and recommendations provided are based on the images presented by the referring veterinarian. No evaluation can be communicated regarding pathology that was not visible in the image/video clips provided.

Thank you for this referral. If the clinical or image interpretation does not parallel your findings or if I can be of any further assistance please contact me.

Eric Lindquist, DMV, DABVP, Cert. IVUSS, CEO of SonoPath.com
info@SonoPath.com