



PATIENT

Chulo Calcaterra

PRESENTING CLINICAL SIGNS

Anemia, elevated GGT.

SPECIES

Canine

ULTRASONOGRAPHIC EXAMINATION OF THE ABDOMEN

Urinary System

The **urinary bladder**, trigone, and pelvic urethra presented normal thicknesses and normal tone. The ureters were not visible which is normal. No uroliths or sediment were visualized and anechoic urine was present. No evidence of inflammatory or neoplastic changes were noted. Ureteral papillae were normal. The prostate measured 1.79 cm (normal size) with minor heterogeneous changes.

BREED

Pug

The **kidneys** revealed largely normal size and structure, corticomedullary definition and ratio (cortex 1/3 of medulla) were essentially maintained with some age-related loss of curvilinear patterns regarding the capsule and C/M junction. The cortices presented largely uniform texture with some increased echogenicity expected for his age patient. Medullary structure differed distinctly from that of the cortex and no evidence of pelvic dilation was present. The left kidney measured 5.06 cm. The right kidney measured 5.23 cm.

SEX

Male

AGE

9 Years

Adrenal Glands

The **left adrenal gland** was enlarged and irregular, measuring 2.42 cm x 1.0 cm. Capsular expansion noted without capsular escape or vascular invasion.

WEIGHT

31 Pounds

The **right adrenal gland** was nodular and mildly irregular, measuring 2.3 cm x 1.08 cm at the cranial pole and 0.60 cm at the caudal pole.

Spleen

The **spleen** was volume contracted with multifocal areas of mineralization.

INTERPRETED BY

Eric Lindquist, DMV
DABVP, Cert. IVUSS

Liver

The **liver** was diffusely hyperechoic to falciform fat with coarse architecture. The gallbladder was unremarkable.

IMAGING PERFORMED BY

Eric Lindquist, DMV
DABVP, Cert. IVUSS

Gastrointestinal & Pancreas

Examination of the **gastrointestinal tract** revealed minor gastric luminal fluid. Duodenal spasm and corrugation noted. No evidence of foreign body. However, the right **pancreatic limb** revealed a 4.0 cm x 3.0 cm mixed hypoechoic region with dilated common bile duct at 0.91 cm. Adhesions and regional inflammation present. This continued into the duodenal papilla. Neoplastic event is a strong potential. Minor areas of free fluid noted.

HOSPITAL NAME

Rockaway AH

ULTRASONOGRAPHIC FINDINGS

- Pancreatitis/necrosis with adhesions and post-hepatic obstruction – Gastroenteritis versus pancreatic or common bile duct carcinoma with concurrent inflammation and gastroduodenitis
- Bilateral nodular adrenal enlargement

REFERRING VET

Dr. Maniar

INVOICE

34208

INTERPRETATION OF THE FINDINGS & FURTHER RECOMMENDATIONS

If bilirubin values elevate in this patient, I would recommend surgical intervention with exploratory of the upper gastrointestinal region and common bile duct. Bile duct redirection procedure may be necessary in this patient. Aggressive treatment for gastroenteritis/pancreatitis warranted in the meantime. Recheck sonogram in 48-72 hours. Prognosis is very guarded.

DATE

1/13/22



PATIENT

Chulo Calcaterra

SPECIES

Canine

BREED

Pug

SEX

Male

AGE

9 Years

WEIGHT

31 Pounds

INTERPRETED BY

Eric Lindquist, DMV
DABVP, Cert. IVUSS

IMAGING PERFORMED BY

Eric Lindquist, DMV
DABVP, Cert. IVUSS

HOSPITAL NAME

Rockaway AH

REFERRING VET

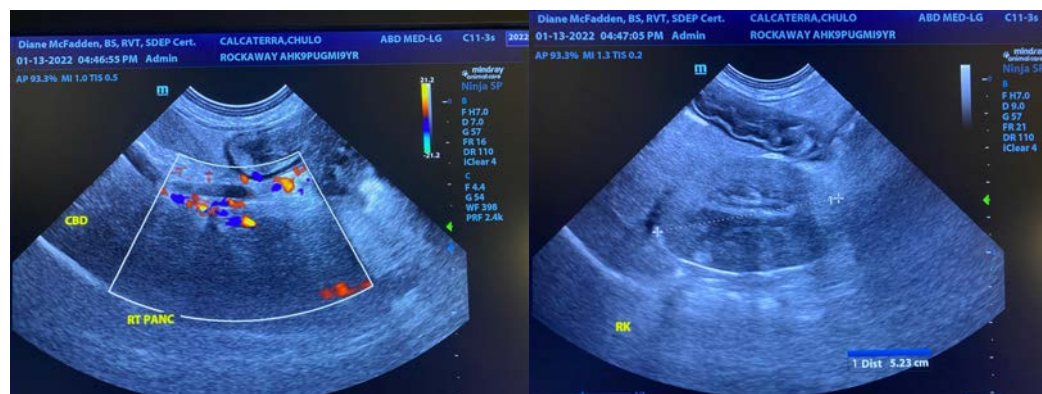
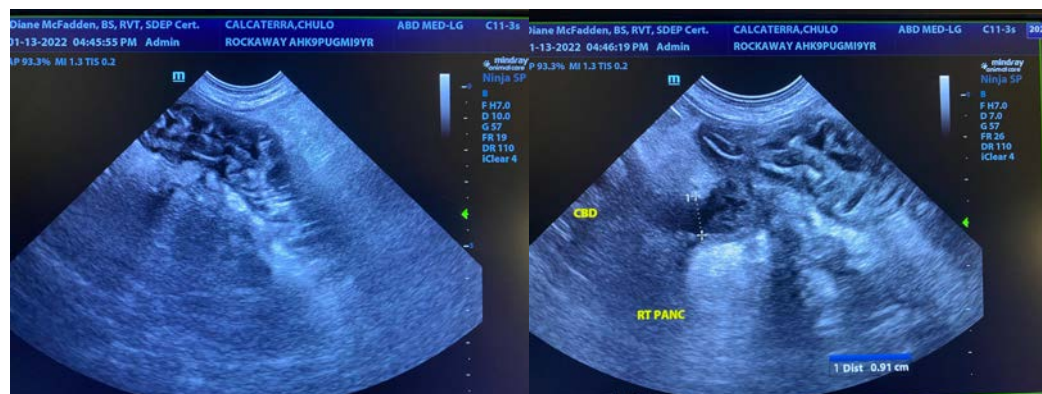
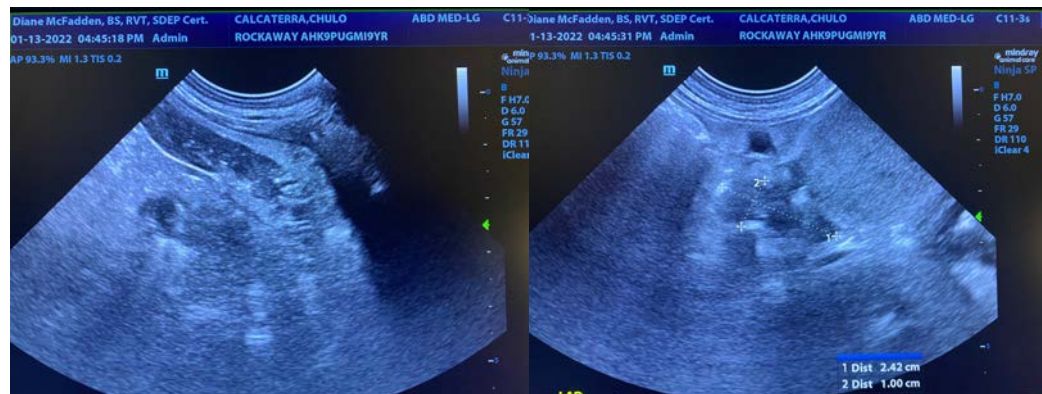
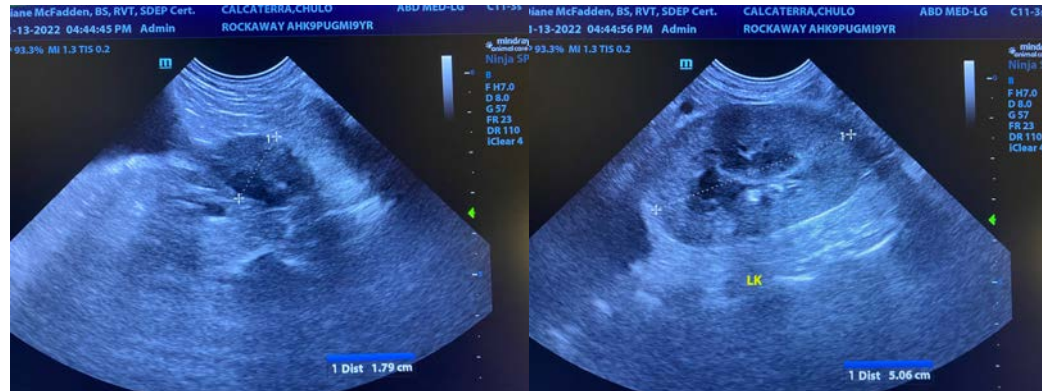
Dr. Maniar

INVOICE

34208

DATE

1/13/22





PATIENT

Chulo Calcaterra

SPECIES

Canine

BREED

Pug

SEX

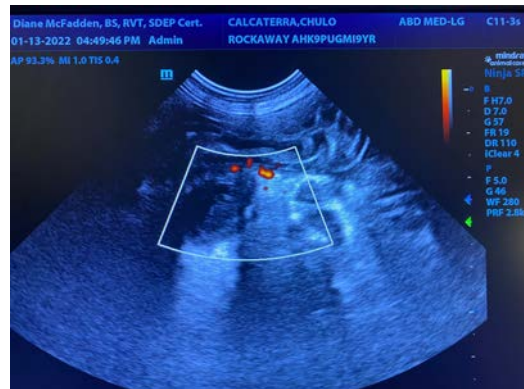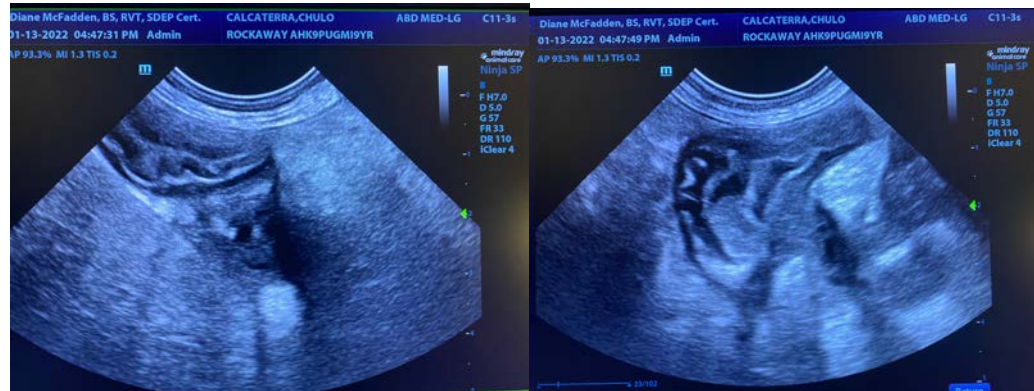
Male

AGE

9 Years

WEIGHT

31 Pounds



INTERPRETED BY

Eric Lindquist, DMV
DABVP, Cert. IVUSS

The information and recommendations provided are based on the images presented by the referring veterinarian. No evaluation can be communicated regarding pathology that was not visible in the image/video clips provided.

Thank you for this referral. If the clinical or image interpretation does not parallel your findings or if I can be of any further assistance please contact me.

IMAGING PERFORMED BY

Eric Lindquist, DMV
DABVP, Cert. IVUSS

Eric Lindquist, DMV, DABVP, Cert. IVUSS, CEO of SonoPath.com
info@SonoPath.com

HOSPITAL NAME

Rockaway AH

REFERRING VET

Dr. Maniar

INVOICE

34208

DATE

1/13/22