



PATIENT

Zeus Rodriguez

SPECIES

Canine

BREED

Bulldog

SEX

Neutered Male

AGE

2 Years

WEIGHT

37.2

INTERPRETED BY

Eric Lindquist, DMV,
DABVP (CFM), Cert.
IVUSS

IMAGING PERFORMED BY

Gabriel Ferrer, DVM

HOSPITAL NAME

Pulse: Pet Ultrasound

REFERRING VET

Dr. Miguel Fernandez

INVOICE

72174

DATE

1/12/26

PRESENTING CLINICAL SIGNS

Px presented as a referral for an abdominal ultrasound and an echocardiogram due to episodes of ataxia, lethargy, and inappetence. The referring veterinarian would like to rule in or out a portosystemic shunt vs. microhepatica (microvascular dysplasia). Px presented to the clinic with ataxia, lethargy/anxiety, and stertor. Px presented to the clinic on a 16 hour fast. Px had been previously diagnosed with a heart murmur, but did not bring any paperwork with further information. The client also mentioned that the Px had been neutered at 6 months old. Client reported anorexia, some episodes of bile regurgitation, no diarrhea, no cough.

Abnormal PE/Chem/CBC/UA Results: Radiographs, Electrocardiogram, and bloodwork attached below for your reference: High RETIC-HGB (31.2pg) Low EOS (0.05L/uL) Low ALKP (11U/L) Low AMYL (399 U/L) Negative 4DX

ULTRASONOGRAPHIC EXAMINATION OF THE ABDOMEN

Urinary System

The **urinary bladder**, trigone, and pelvic urethra presented normal thicknesses and normal tone. The ureters were not visible which is normal. No uroliths or sediment were visualized and anechoic urine was present. No evidence of inflammatory or neoplastic changes were noted. Ureteral papillae were normal.

The prostate was uniform at 1.4 cm.

The **kidneys** revealed normal size and structure, corticomedullary definition and ratio for this age. The cortices presented largely uniform texture with normal echogenic relationship to liver and spleen. Medullary structure differed distinctly from the cortex and no evidence of pelvic dilation was present. The capsules were acceptably uniform without significant irregularities. Right kidney measured 5.5 cm. Left kidney measured 5.7 cm.

Adrenal Glands

Both **adrenal glands** were visualized and recognized as having normal shape, size, position and echogenicity for this breed. The phrenic vasculature, glandular echogenicity and detail were unremarkable. Capsule, cortex, and medullary definition were normal for this age patient. Left measured 2.4 cm x 0.66 cm at the caudal pole and 0.40 cm at the cranial pole. Right measured 2.5 cm x 0.75 cm.

Spleen

The **spleen** was folded upon itself caudally. It presented a smooth homogeneous parenchyma hyperechoic to liver and renal cortical parenchyma. The capsule was smooth without noticeable expansion or deviation from within the spleen or adjacent pathology. The splenic vasculature demonstrated normal volume without signs of congestion or thrombosis. No sonographic evidence of acute or chronic inflammatory, neoplastic, or infarctual changes were noted.

Liver

The **liver** images submitted revealed subjectively normal liver size, contour, and structure. Parenchymal echogenicity was naturally coarse and hypoechoic to the spleen. Vascular and biliary tracts were of normal volume with no evidence of congestion. The gallbladder presented acceptably thin walls with



PATIENT

Zeus Rodriguez

SPECIES

Canine

BREED

Bulldog

SEX

Neutered Male

AGE

2 Years

WEIGHT

37.2

INTERPRETED BY

Eric Lindquist, DMV,
DABVP (CFM), Cert.
IVUSS

IMAGING PERFORMED BY

Gabriel Ferrer, DVM

HOSPITAL NAME

Pulse: Pet Ultrasound

REFERRING VET

Dr. Miguel Fernandez

INVOICE

72174

DATE

1/12/26

primarily anechoic content. The cystic and common bile ducts were normal. No pathological hepatic lymphadenopathy was evident. No overt structural evidence of inflammatory, infiltrative or regenerative pathology was evident. Portal vein to vena cava ratio was 1:1. Portal vein measured 0.70 cm. Vena cava measured 0.97 cm.

Gastrointestinal

The **stomach** revealed shadowing luminal material, assuming the patient was NPO. Structures measured up to 1.7 cm. Gastric stasis noted. The small intestine and colon were unremarkable.

Pancreas

The base and limbs of the **pancreas** were observed to be largely isoechoic to surrounding omental fat. Pancreatic duct and capsular contour were acceptably normal and parenchyma respected normal curvilinear patterns. No overt evidence of active inflammatory or neoplastic disease was noted.

Free Abdomen

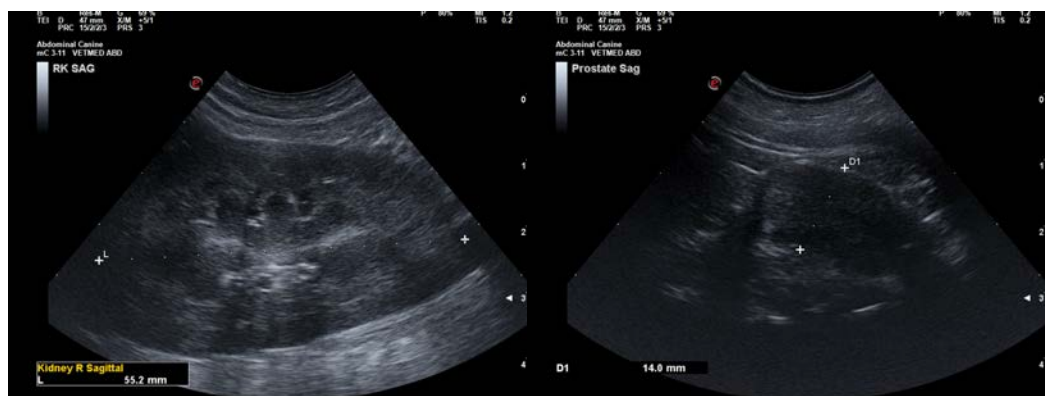The mesenteric **lymph nodes** presented normal length to width ratio with slight, swollen contour. There was no loss of parenchymal detail. This is most consistent with reactive lymphadenitis or lymphatic hyperplasia.

ULTRASONOGRAPHIC FINDINGS

- Shadowing gastric material consistent with gastric foreign body.
- Reactive mesenteric lymph nodes.
- Folded spleen.

INTERPRETATION OF THE FINDINGS & FURTHER RECOMMENDATIONS

No evidence of intrahepatic or extrahepatic shunting. If the patient was NPO at the time of the sonogram, then gastrotomy or endoscopy indicated.





PATIENT

Zeus Rodriguez

SPECIES

Canine

BREED

Bulldog

SEX

Neutered Male

AGE

2 Years

WEIGHT

37.2

INTERPRETED BY

Eric Lindquist, DMV,
DABVP (CFM), Cert.
IUUSS

**IMAGING
PERFORMED BY**

Gabriel Ferrer, DVM

HOSPITAL NAME

Pulse: Pet Ultrasound

REFERRING VET

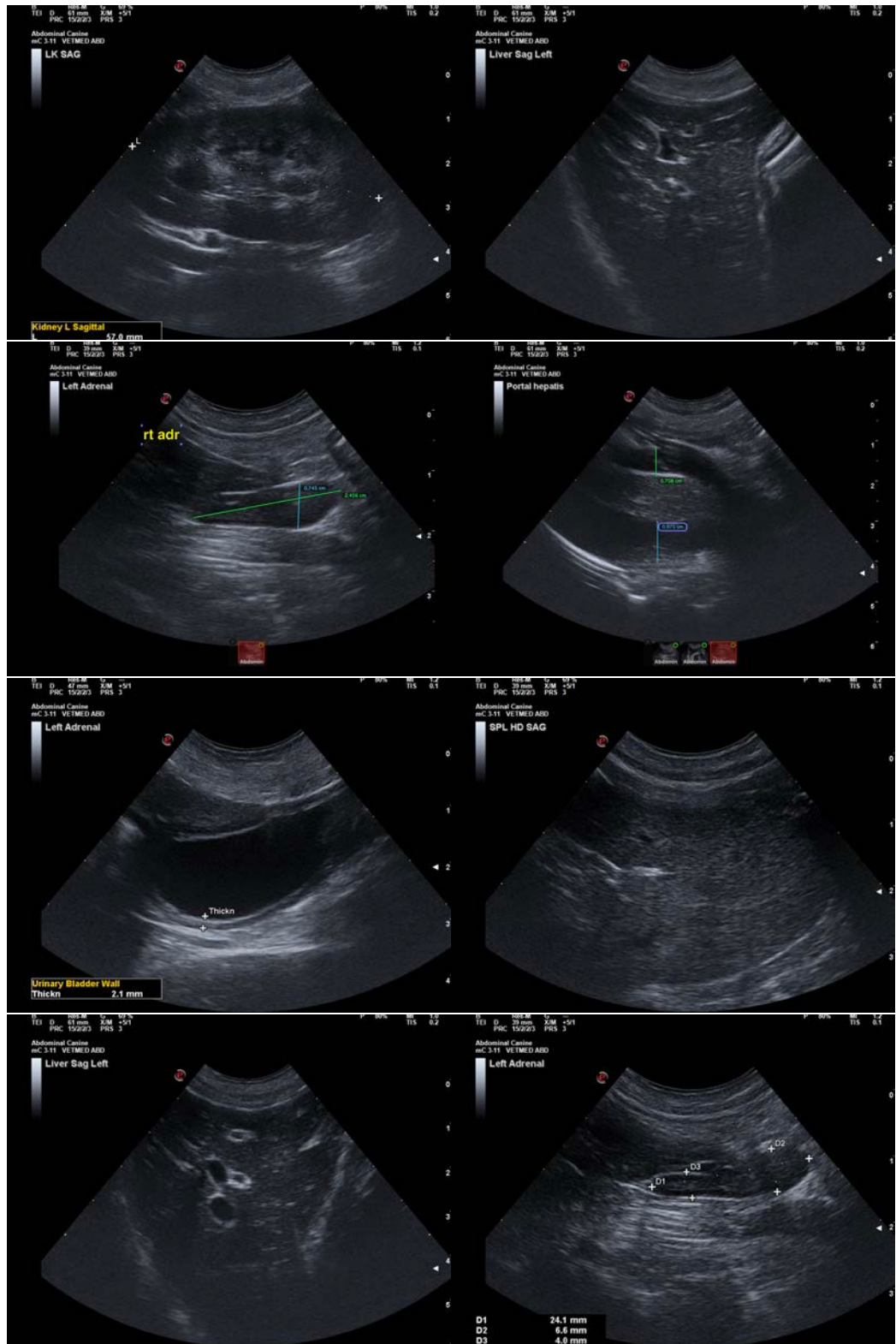
Dr. Miguel Fernandez

INVOICE

72174

DATE

1/12/26





PATIENT

Zeus Rodriguez

SPECIES

Canine

BREED

Bulldog

SEX

Neutered Male

AGE

2 Years

WEIGHT

37.2

INTERPRETED BY

Eric Lindquist, DMV,
DABVP (CFM), Cert.
IVUSS

IMAGING PERFORMED BY

Gabriel Ferrer, DVM

HOSPITAL NAME

Pulse: Pet Ultrasound

REFERRING VET

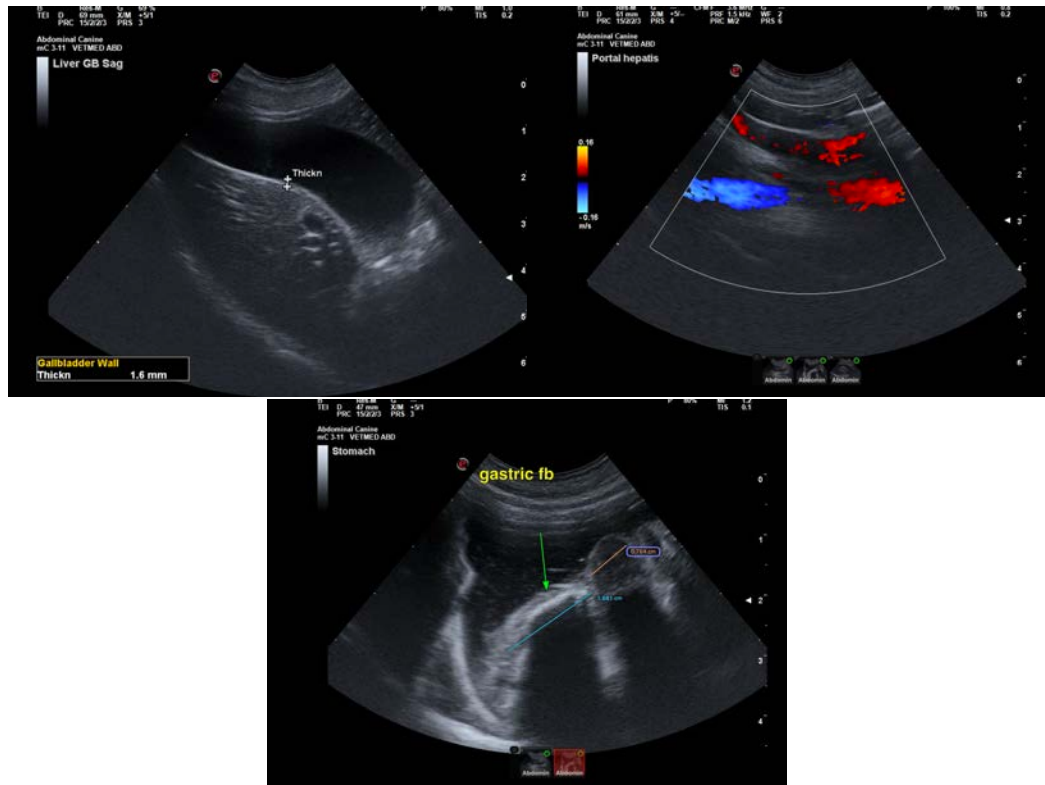
Dr. Miguel Fernandez

INVOICE

72174

DATE

1/12/26



The information and recommendations provided are based on the images presented by the referring veterinarian/sonographer. No evaluation can be communicated regarding pathology that was not visible in the image/video clips provided.

Thank you for this referral. If the clinical or image interpretation does not parallel your findings or if I can be of any further assistance please contact me.

Eric Lindquist, DMV, DABVP(CFM), Cert. IVUSS,
CEO, Owner, Founder -- SonoPath.com
info@SonoPath.com