

Clinical Sonography & Telecytology
Educational Teleconsultation Services™

PATIENT
Skyla Gutierrez

SPECIES
Canine

BREED
Pomeranian

SEX
Intact Male

AGE
12 Years 11 Months

WEIGHT
Not Provided

INTERPRETED BY
Eric Lindquist, DMV, DABVP (CFM), Cert. IVUSS

IMAGING PERFORMED BY
Eric Lindquist, DMV, DABVP (CFM), Cert. IVUSS

HOSPITAL NAME
Warren Animal Hospital

REFERRING VET
Dr. Brian

INVOICE
72144

DATE
1/12/26

PRESENTING CLINICAL SIGNS

Heart murmur 3/6. On Hydrocodone and Furosemide.

ULTRASONOGRAPHIC EXAMINATION OF THE HEART

CANINE CARDIAC PARAMETERS	MR VMAX (m/s)	TR VMAX (m/s)	LA/AO (M-Mode)	LA/AO (Heart Base; Swe)	FS (%)	EF (%)	EPSS (cm)
NORMAL PARAMETER	4.5-5.5	<2.7	1.3	Up to 1.6	28-40	40-100	<0.6
PATIENT	6.0	--	1.3	1.4	55	87	0.1
CANINE CARDIAC PARAMETERS	**HR** (BPM)	**AV VMAX** (m/s)	**PV MAX** (m/s)	**BODY WEIGHT** (kg)	**LAD** LA MAX 4 Chamber	**LVIDd** Avg; 2D and m-mode short axis (cm)	**LVIDs** Avg; 2D and m-mode short axis (cm)
NORMAL PARAMETER	50-100	0.7-1.7	0.7-1.6				
PATIENT	150	1.6	0.8	NP	2.4	2.73	--

Cardiac Presentation

The echocardiogram in this patient demonstrated normal **left atrial** size based on 3 different LA measurement methods. Chamber volumes and echogenicity were normal. The cranial and caudal **mitral** valve leaflets presented vegetative thickening consistent with endocardiosis. Doppler indicated measurable insufficiency. The **left ventricle** presented thicknesses with linear contour and was not dilated nor restricted. The **myocardium** presented normal echogenicity without subjective evidence of significant fibrotic or ischemic disease. **Contractility** of the ventricular walls was adequate and in normal range for this patient evidenced by the fractional shortening measurement and subjective evaluation of the different regions of the myocardium. The **left ventricular outflow** tract demonstrated normal laminar flow and subjective structural integrity. The **right atrium** and auricle revealed normal size, structure and content. No evidence of masses was noted or chamber overload. **Tricuspid** valvular assessment demonstrated adequate linear morphology. The **right ventricle** was of normal size (1/3 diameter of LV), chordae structure, myocardial echogenicity and thickness. **Pulmonic** tract assessment revealed normal valve structure, laminar flow, and diameter (approx.1:1 pa/ao ratio). No visible **pericardial** or free pleura fluid was noted. No echographically detectable evidence of infiltrative disease was visible. The cranial **mediastinum and pericardial regions** were free of masses in the visible window.

ULTRASONOGRAPHIC FINDINGS

- Stage B1 valvular disease.

INTERPRETATION OF THE FINDINGS & FURTHER RECOMMENDATIONS

The cough is non-cardiogenic in this patient.

PATIENT

Skyla Gutierrez

SPECIES

Canine

BREED

Pomeranian

SEX

Intact Male

AGE

12 Years 11 Months

WEIGHT

Not Provided

INTERPRETED BY

Eric Lindquist, DMV, DABVP (CFM), Cert. IVUSS

IMAGING PERFORMED BY

Eric Lindquist, DMV, DABVP (CFM), Cert. IVUSS

HOSPITAL NAME

Warren Animal Hospital

REFERRING VET

Dr. Brian

INVOICE

72144

DATE

1/12/26

The heart is stable without clinical disease. No overt contraindication for anesthesia of brief to moderate duration. I suggest Torbutrol premed, Propofol induction, Isoflo maintenance or similar protocol if anesthesia is desired. Blood pressure, EKG and chest radiographs are recommended if not already performed. Target white coat negative systolic pressure of < 160 mmHg. If higher than this ACE-inhibitor is suggested to reach this level. Recheck echocardiogram is recommended in 6 months, earlier if murmur grade increases or clinical signs initiate.

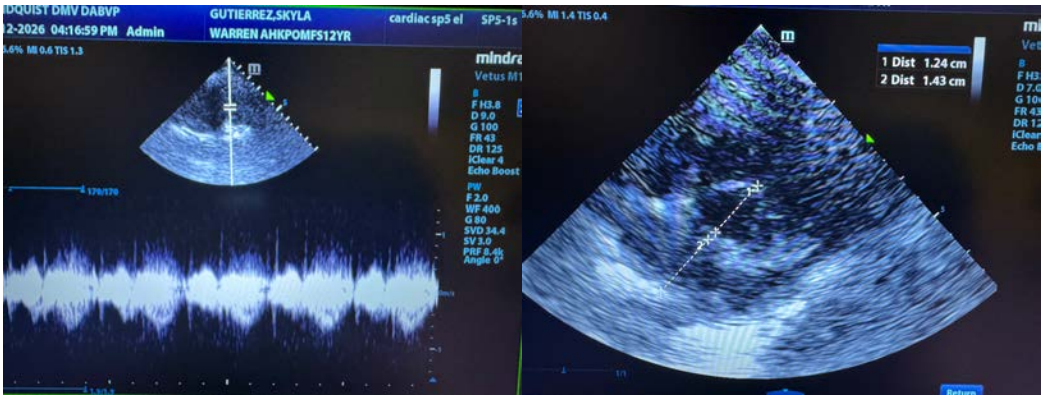

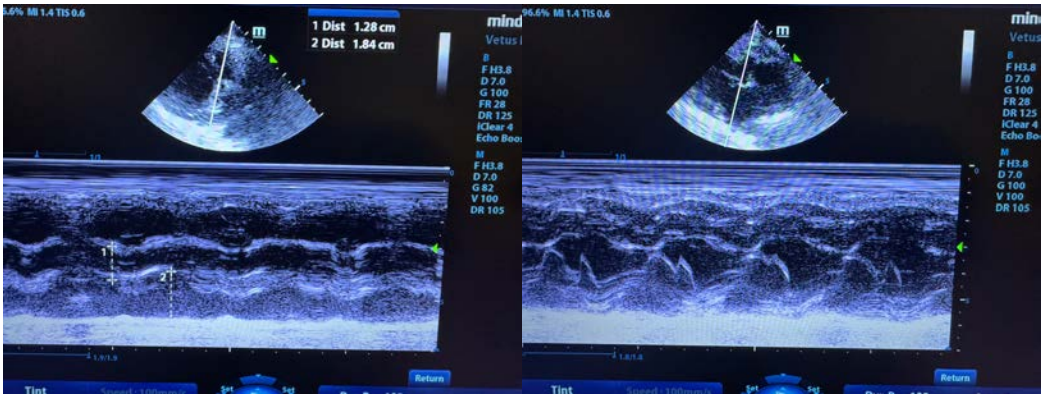

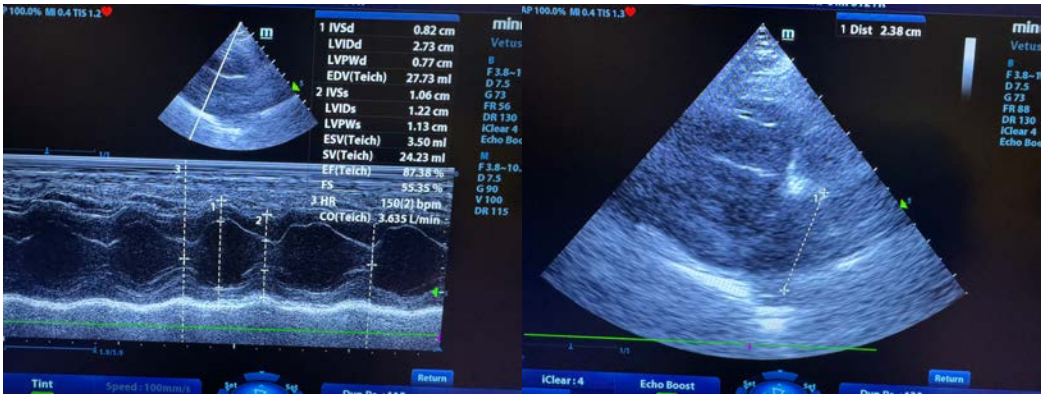

New Jersey Mobile
FUELED BY SONOPATH VETERINARY ULTRASOUND



Clinical Sonography & Telecytology
Educational Teleconsultation Services™

SonoPath www.SonoPath.com info@sonopath.com 800.838.4268

PATIENT

Skyla Gutierrez

SPECIES

Canine

BREED

Pomeranian

SEX

Intact Male

AGE

12 Years 11 Months

WEIGHT

Not Provided

INTERPRETED BY

Eric Lindquist, DMV, DABVP (CFM), Cert. IVUSS

IMAGING PERFORMED BY

Eric Lindquist, DMV, DABVP (CFM), Cert. IVUSS

HOSPITAL NAME

Warren Animal Hospital

REFERRING VET

Dr. Brian

INVOICE

72144

DATE

1/12/26

The information and recommendations provided are based on the images presented by the referring veterinarian/sonographer. No evaluation can be communicated regarding pathology that was not visible in the image/video clips provided.

Thank you for this referral. If the clinical or image interpretation does not parallel your findings or if I can be of any further assistance please contact me.

Eric Lindquist, DMV, DABVP(CFM), Cert. IVUSS,
CEO, Owner, Founder -- SonoPath.com
info@SonoPath.com