



PATIENT

Prince Harry Girard

SPECIES

Feline

BREED

Sphynx

SEX

Neutered male

AGE

5 ½ years

WEIGHT

9.86 lbs

INTERPRETED BY

Eric Lindquist, DMV
DABVP, Cert. IVUSS

PRESENTING CLINICAL SIGNS

History: No relevant history to my knowledge. Owner has just been wanting to perform an echo due to the breed predisposition for cardiac disease and mild elevation in proBNP. No murmur auscultated (pet already sedated with alfaxalone and torb at the time of auscultation due to behavior)
Abnormal PE/Chem/CBC/UA Results: Normal t4 ProBNP 151 Unable to get a reliable blood pressure on patient, very fractious and unable to examine pet prior to sedation.

ULTRASONOGRAPHIC EXAMINATION OF THE HEART

The echocardiogram in this patient demonstrated normal **left atrial** size based on 3 separate LA measurements. The cranial and caudal **mitral** valve leaflets presented normal linear structure and kinetics. The **left ventricle** presented normal thicknesses with linear contour and was not dilated nor restricted. The **myocardium** presented normal echogenicity without subjective evidence of significant fibrotic or ischemic disease. **Contractility** of the ventricular walls was adequate and in normal range for this patient evidenced by the fractional shortening measurement and subjective evaluation of the different regions and angles of the myocardium. The **left ventricular outflow** tract demonstrated normal laminar flow and subjective structural integrity. The **right atrium** and auricle revealed normal size, structure and content. No evidence of masses was noted or chamber overload. **Tricuspid** valvular assessment demonstrated adequate linear morphology and kinetics. The **right ventricle** was of normal size (1/3 diameter of LV), chordae structure, myocardial echogenicity and thickness. **Pulmonic** tract assessment revealed normal valve structure, laminar flow, and diameter (approx. 1:1 pa/ao ratio). No visible **pericardial** or free pleura fluid was noted or extra cardiac pathology in the visible planes. The cranial **mediastinum and pericardial regions** were free of masses in the visible window.

IMAGING PERFORMED BY

Amy Isaac

HOSPITAL NAME

Valley West & Elk
Valley VH

REFERRING VET

Dr. Isaac

INVOICE

70024

DATE

1/12/26

FELINE CARDIAC PARAMETERS	BODY WEIGHT	HR (BPM)	IVSd (cm)	LVIDd (cm)	LVWd (cm)	FS (%)	EF (%)
NORMAL PARAMETER	-----	150-240	0.3-0.6	1.0-2.1	0.25-0.6	35-67	80-100
PATIENT	9.86 lbs	180	0.57	1.2	0.55	45	90
FELINE CARDIAC PARAMETERS	LA/AO (M-mode)	LA/AO HEART BASE (Sisson)	LAD LA MAX 4 Chamber		LVOT VEL. (m/s)	RVOT VEL. (m/s)	IVRT (m/)
NORMAL PARAMETER	<1.5	1.6	0.7-1.7		<1.6	<1.3	40-60
PATIENT	10.9	1.3	1.4		-	-	NM
Adapted from June Boon, Veterinary Echocardiography, 1998 Sisson D et al. JVIM 1991; 5: 232, Jacobs et al. Am J Vet Res 1985; 46:1705							



PATIENT

Prince Harry Girard

SPECIES

Feline

BREED

Sphynx

SEX

Neutered male

AGE

5 ½ years

WEIGHT

9.86 lbs

INTERPRETED BY

Eric Lindquist, DMV
DABVP, Cert. IVUSS

IMAGING PERFORMED BY

Amy Isaac

HOSPITAL NAME

Valley West & Elk
Valley VH

REFERRING VET

Dr. Isaac

INVOICE

70024

DATE

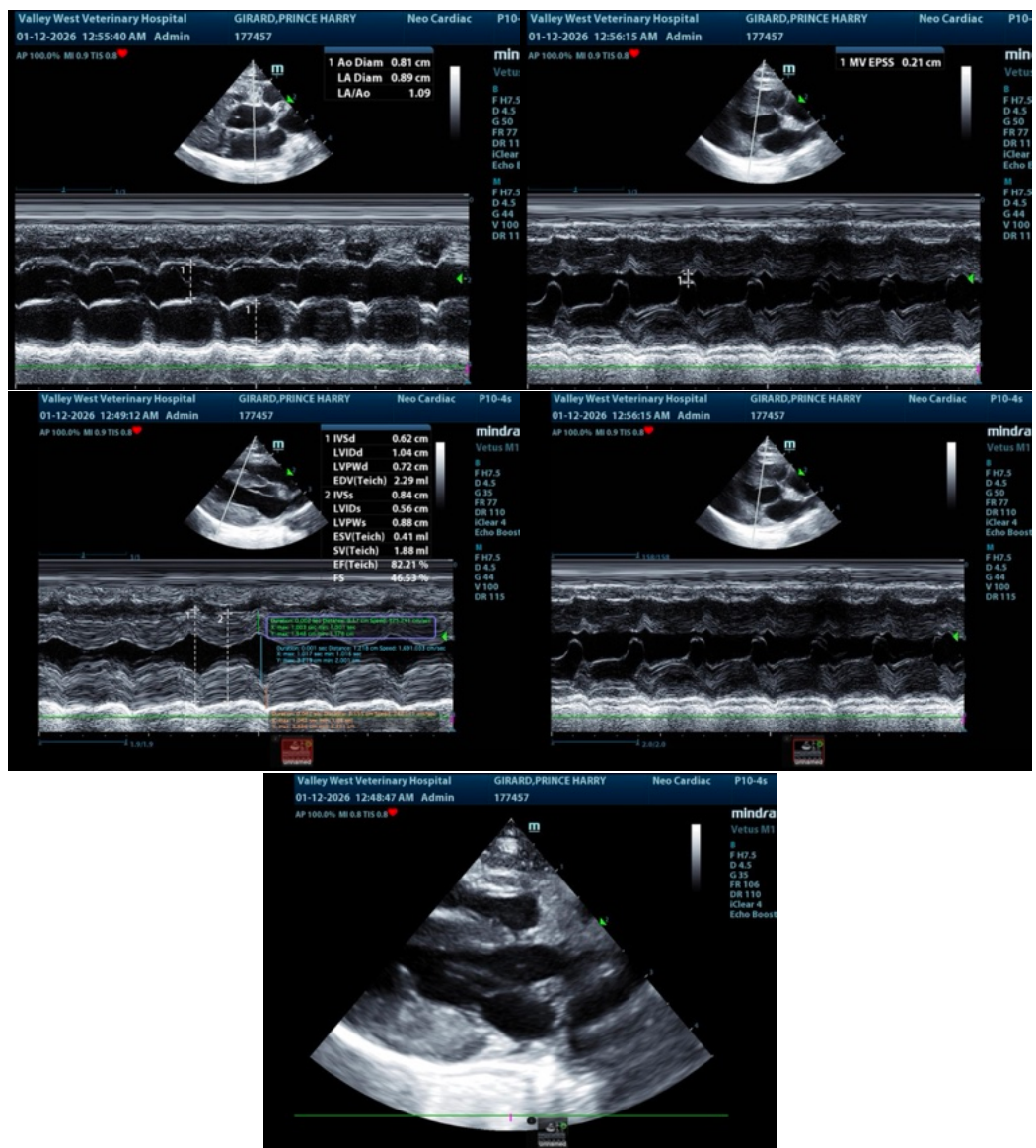
1/12/26

ULTRASONOGRAPHIC FINDINGS

Structurally normal heart.

INTERPRETATION OF THE FINDINGS & FURTHER RECOMMENDATIONS

There was no evidence of congenital or acquired disease.





PATIENT

Prince Harry Girard

SPECIES

Feline

BREED

Sphynx

SEX

Neutered male

AGE

5 ½ years

WEIGHT

9.86 lbs

INTERPRETED BY

Eric Lindquist, DMV
DABVP, Cert. IVUSS

IMAGING PERFORMED BY

Amy Isaac

HOSPITAL NAME

Valley West & Elk
Valley VH

REFERRING VET

Dr. Isaac

INVOICE

70024

DATE

1/12/26

The information and recommendations provided are based on the images presented by the referring veterinarian/sonographer. No evaluation can be communicated regarding pathology that was not visible in the image/video clips provided.

Thank you for this referral. If the clinical or image interpretation does not parallel your findings or if I can be of any further assistance please contact me.

Eric Lindquist, DMV, DABVP (CFM), Cert. IVUSS, CEO of SonoPath.com

info@SonoPath.com