



**PATIENT**

Minnie Rice

**SPECIES**

Canine

**BREED**

Micro Bully

**SEX**

Female

**AGE**

8 Months

**WEIGHT**

17 lbs

**PRESENTING CLINICAL SIGNS**

Low-grade heart murmur.

**ULTRASONOGRAPHIC EXAMINATION OF THE HEART**

CANINE CARDIAC PARAMETERS	MR VMAX (m/s)	TR VMAX (m/s)	LA/AO (M-Mode)	LA/AO (Heart Base; Swe)	FS (%)	EF (%)	EPSS (cm)
NORMAL PARAMETER	4.5-5.5	<2.7	1.3	Up to 1.6	28-40	40-100	<0.6
PATIENT	--	--	1.3	1.4	45	90	NM
CANINE CARDIAC PARAMETERS	HR (BPM)	AV VMAX (m/s)	PV MAX (m/s)	BODY WEIGHT (lbs)	LAD LA MAX 4 Chamber	LVIDd Avg; 2D and m-mode short axis (cm)	LVIDs Avg; 2D and m-mode short axis (cm)
NORMAL PARAMETER	50-100	0.7-1.7	0.7-1.6				
PATIENT	~80	1.67	1.63	17	2.66	2.4	--

**INTERPRETED BY**

Eric Lindquist, DMV, DABVP (CFM), Cert. IVUSS

**IMAGING PERFORMED BY**

Eric Lindquist, DMV, DABVP (CFM), Cert. IVUSS

**HOSPITAL NAME**

Warren Animal Hospital

**REFERRING VET**

Dr. Brian

**INVOICE**

72145

**DATE**

1/12/26

**Cardiac Presentation**

The echocardiogram in this patient demonstrated normal **left atrial** size based on 3 separate methods of LA evaluation. The cranial and caudal **mitral** valve leaflets presented normal linear structure, extension in systole, and union in diastole with normal kinesis. The **left ventricle** presented thicknesses with linear contour and was not dilated nor restricted. The **myocardium** presented normal echogenicity without subjective evidence of significant fibrotic or ischemic disease. **Contractility** of the ventricular walls was adequate and in normal range for this patient evidenced by the fractional shortening measurement and subjective evaluation of the different regions of the myocardium. The **left ventricular outflow** tract demonstrated normal laminar flow and subjective structural integrity. The **right atrium** and auricle revealed normal size, structure and content. No evidence of masses was noted. **Tricuspid** valvular assessment demonstrated adequate linear morphology and kinesis. The **right ventricle** was of normal size (1/3 diameter of LV), chordae structure, myocardial echogenicity and thickness. **Pulmonary outflow** tract assessment revealed normal valve structure, laminar flow, and diameter (approx. 1:1 pa/ao ratio). Frequent arrhythmia noted. No visible **pericardial** or free pleura fluid was noted. The cranial **mediastinum** and **pericardial** and **extra-cardiac** regions were free of masses in the visible window.

**ULTRASONOGRAPHIC FINDINGS**

- Normal echocardiogram with persistent arrhythmia, likely pronounced sinus arrhythmia.

**INTERPRETATION OF THE FINDINGS & FURTHER RECOMMENDATIONS**

EKG warranted for further definition. No evidence of congenital disease. No evidence of pressure overload or volume overload. The murmur is likely idiopathic flow murmur.



**PATIENT**

Minnie Rice

**SPECIES**

Canine

**BREED**

Micro Bully

**SEX**

Female

**AGE**

8 Months

**WEIGHT**

17 lbs

**INTERPRETED BY**

Eric Lindquist, DMV,  
 DABVP (CFM), Cert.  
 IVUSS

**IMAGING PERFORMED BY**

Eric Lindquist, DMV,  
 DABVP (CFM), Cert.  
 IVUSS

**HOSPITAL NAME**

Warren Animal  
 Hospital

**REFERRING VET**

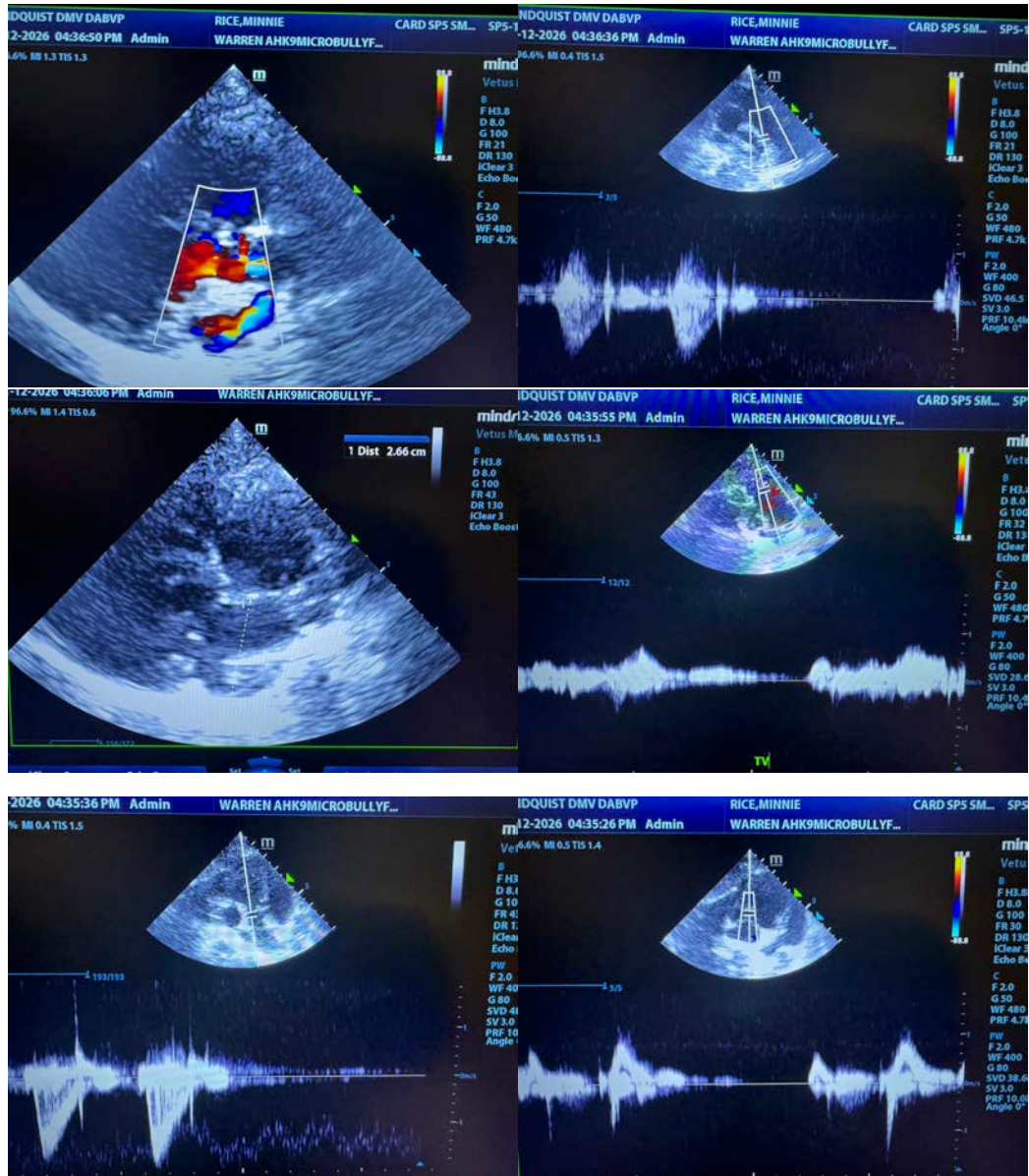
Dr. Brian

**INVOICE**

72145

**DATE**

1/12/26





**PATIENT**

Minnie Rice

**SPECIES**

Canine

**BREED**

Micro Bully

**SEX**

Female

**AGE**

8 Months

**WEIGHT**

17 lbs

**INTERPRETED BY**

Eric Lindquist, DMV,  
 DABVP (CFM), Cert.  
 IVUSS

**IMAGING PERFORMED BY**

Eric Lindquist, DMV,  
 DABVP (CFM), Cert.  
 IVUSS

**HOSPITAL NAME**

Warren Animal  
 Hospital

**REFERRING VET**

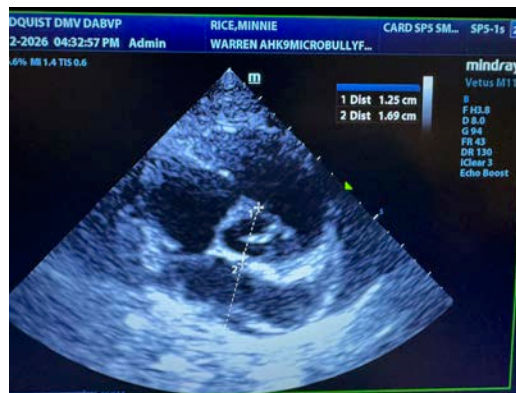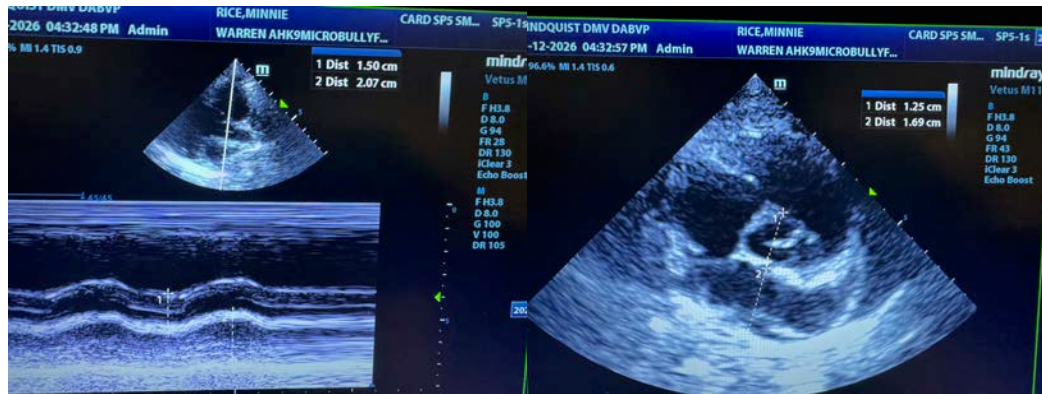
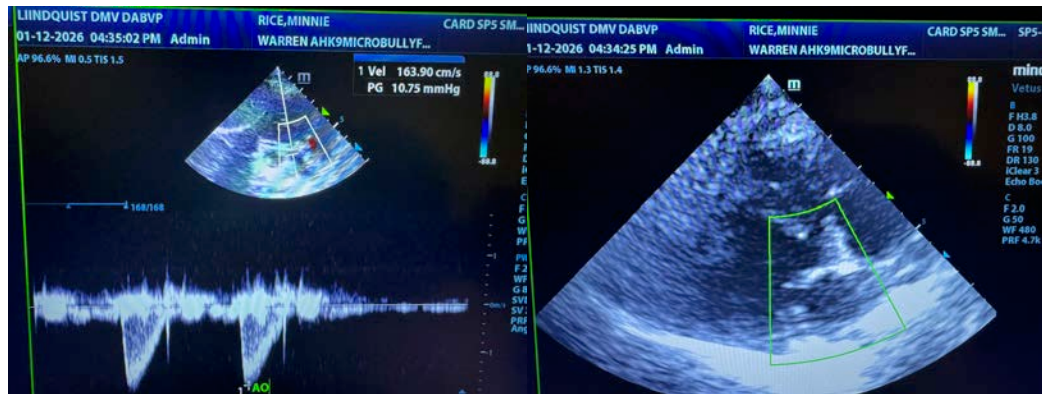
Dr. Brian

**INVOICE**

72145

**DATE**

1/12/26



The information and recommendations provided are based on the images presented by the referring veterinarian/sonographer. No evaluation can be communicated regarding pathology that was not visible in the image/video clips provided.

Thank you for this referral. If the clinical or image interpretation does not parallel your findings or if I can be of any further assistance please contact me.

**Eric Lindquist, DMV, DABVP(CFM), Cert. IVUSS,**  
 CEO, Owner, Founder -- SonoPath.com  
[info@SonoPath.com](mailto:info@SonoPath.com)